

Histopathology and Bioaccumulation of Heavy Metals (Cu & Pb) in the Giant land snail, *Archachatina marginata* (Swainson)

Otitolaju, A.A., *¹ Ajikobi, D.O. ² and Egonmwan, R.I. ¹

¹University of Lagos, Faculty of Science, Department of Zoology, Akoka, Lagos, Nigeria

²NEXT Newspapers, A Publication of Timbuktu Media, 235, Igbosere road, Lapal House, Lagos Island, Lagos, Nigeria

Abstract: Histopathological effects of heavy metals (Cu and Pb) and their bioaccumulation in the giant land snails, *Archachatina marginata* were assessed by feeding experiments. On the basis of 168h LC₅₀, CuSO₄ with 168h LC₅₀ value of 2.35mM was found to be significantly (no overlaps in 95% confidence limit) more toxic than Pb(NO₃)₂ (5.79mM). The exposure of the snails to sublethal concentrations of the metals resulted in a prevalence of hepatocellular foci of cellular alterations (FCA) in the hepatopancreas of snails. Hepatocytes of test animals exposed to sublethal concentration of Cu were also observed to be clogged together with peripheral thickening while exposure to lead caused inflammation of hepatic tubules. Basophilic adenoma and ovotesticular fibrillar inclusions were also observed in the ovotestes of snails exposed to the test metals. Post treatment analysis of *A. marginata* tissues revealed that exposure to sublethal Cu concentrations resulted in a five-fold and three-fold accumulation of the metal, respectively, in the hepatopancreas and muscular foot of exposed animals compared to the control animal. The bioaccumulation studies also indicate the ability of the snail to regulate and excrete excess level of copper from its body. The accumulation of Pb in the hepatopancreas were found to be up to 375 folds while accumulation of over 1000 folds compared to the concentrations detected in control animals was observed in the edible muscular foot. The array of toxicopathic organ or tissue alterations observed in this study represents biological end-points of contaminant exposure and therefore reinforces the application of histopathology as a powerful tool for monitoring anthropogenic contamination of terrestrial environments. The combination of these pathological end points with the monitoring of metal levels in body tissues of edible animals provides important tools for early detection of impending environmental problems and prevention of potential public health issues.

Keywords: Histopathology, Bioaccumulation, *Archachatina*, Biomonitoring, Heavy metal.

1. INTRODUCTION AND LITERATURE REVIEW

Heavy metal pollution of terrestrial and aquatic ecosystems have long been recognized as a serious environmental concern [1]. This is largely due to their non-biodegradability and tendency to accumulate in plants and animals tissues. As a result, metal bioaccumulation is a major route through which increased levels of the pollutants are transferred across food chains/web, creating public health problems wherever man is involved in the food chain [2-4]. Therefore, it is important to always determine the bioaccumulation capacity for heavy metals by organisms especially the edible ones, in order to assess potential risk to human health.

Several authors [5-7] have reported the importance of molluscs as good indicators for monitoring heavy metal pollution even though the abnormally high environmental concentrations of heavy metal affects numerous biological processes involved in the development and maintenance of molluscan populations such as feeding, growth, reproduction, general physiological activities and maturity [8]. These cascades of stress related responses including histopathology

are now increasingly being used as biomarkers of environmental stress since they provide a definite biological end-point of historical exposure [9-11]. As such, the utility of histological lesions as sensitive and reliable indicators of the health of wild fish populations has been demonstrated [12-14]. Several laboratory and mesocosm studies have also demonstrated casual links between exposure to xenobiotics and development of toxicopathic hepatic lesions [15, 16].

Archachatina marginata (Swainson) commonly referred to as the giant land snail is a pulmonate gastropod, distributed throughout the world in the tropical and sub-tropical regions where most of the genera of the family are confined to Africa [17, 18]. The land snail is a major source of protein and consumed by a vast majority of people living around the dense tropical forests and in surrounding cities where snail farming is now a major preoccupation for the people [19]. Therefore this present study on the bioaccumulation capacity of the snails and histopathological effects of heavy metals (Copper and Lead) appear to be of particular relevance for assessing public health risks that could arise from the consumption of snails and also provide useful biological indices and measurements that can be deployed during biological effects monitoring. The choice of heavy metals (Cu and Pb) used for this study is based on the use of copper (Cu) as a major constituents of agricultural pesticides which the snails are inadvertently exposed to while lead (Pb) has been an

*Address correspondence to this author at the University of Lagos, Faculty of Science, Department of Zoology, Akoka, Lagos, Nigeria; Tel: +2348030628981; Fax: +12084745808; E-mail: bayotitolaju@yahoo.com

additive of petroleum products which gets introduced into the environment during burning of the fossil fuels and ultimately become deposited on the leaves and soil where the snails dwell.

2. MATERIALS AND METHODS

Test Animals, Laboratory Cultures and Acclimatisation

Archachatina marginata (Mollusca: Gastropoda; Stylomatophora, Archatinidae) was used for the experiments. Snails within weight ranges of 55g–75g were selected for all the bioassays.

The snails were allowed to acclimatize to laboratory conditions (28±2°C; 79±2 RH) in a glass terrarium (200cmX80cmX30cm) containing a layer of moist humus soil as substrate for at least 7 days before commencement of bioassays. The terrarium was covered with a wire mesh for proper ventilation and also to prevent the snails from crawling out. The terrarium was wet daily with dechlorinated tap water and the snails were fed *ad libitum* on fresh pawpaw leaves (*Carica papaya*). Unconsumed food and faecal material were removed daily to prevent contamination.

The snails used throughout the experiment were obtained from the same source to reduce variability of biotype.

Test Chemicals

The heavy metals investigated in this study were analar grades of the following metallic compounds:

Copper Sulphate (CuSO₄.5H₂O)

Lead Nitrate (Pb (NO₃)₂)

3. GENERAL BIOASSAY TECHNIQUES

Preparation of Test Media including Application of Toxicant

Acute Toxicity Studies

Predetermined amounts of heavy metal compounds were weighed using an analytical balance, and made up to a fixed volume by adding appropriate volume of distilled water as diluent to achieve a stock solution of known strength. The resultant stock was then serially diluted to obtain solutions of required concentration. For each of the test concentrations, 1000g of the loamy plus humus soil was placed into the bioassay container to form a thick layer of substrate. 100g of *Carica papaya* (pawpaw) leaves were then placed in each bioassay container. Each test medium was then sprinkled with 150mls of solution containing pre-determined concentration of the test compound. The control setup was prepared in the same way describe above except that only water was sprinkled on the leaves and substrate. The setup was covered with wire mesh and labeled accordingly.

The definitive concentrations which the snails were exposed to are given below.

Cu against *A. marginata*: 2.0mM, 2.41mM, 2.81mM, 3.2mM and untreated control.

Pb against *A. marginata*: 4.5mM, 6.04mM, 7.6mM, 9.1mM and untreated control.

The definitive concentrations were chosen after a concentration range-finding experiment. Mortality count was carried out once every 24hours for 7 days.

Assessment of Quantal Response (Mortality)

Snails are taken to be dead if there is no movement when the foot region of the animal is prodded with a pointed metal rod or if there is no activity after 5 minutes of placing the snail inside water.

Histopathological Studies

A similar experiment as described above was carried out, however in this case, *A. marginata* were exposed to sublethal concentrations of Cu and Pb salts. Each treatment including control was replicated six times (2 snails per replicate) giving a total of 12 snails per concentration and control. The animals were fed every 72 hours for the duration of the bioassay.

Sublethal concentrations was extrapolated from the 168hrLC50 as fractions given by 1/10th of 168hrLC50 and 1/100th of 168hrLC50. The test concentrations used for the experiment are as follows:

Cu against *A. marginata* are 0.235mM, 0.0235mM and untreated control.

Pb against *A. marginata* are 0.579mM, 0.0579mM and untreated control.

On day 14 and 28 of the assays, four live snails per concentration including control were randomly selected, cleaned thoroughly in distilled water and carefully removed from their shells. The ovotestes and hepatopancreas were removed and fixed in Bouin's fluid. The fixed samples were transferred to phosphate buffer (pH 6.8) after 7 hours of fixation in Bouin's fluid. The tissues were then dehydrated in graded alcohol, cleared in xylene before embedding in paraffin wax (melting point 56.0°C). Serial sections of 2-5 μm thickness were cut in rotary microtome then passed through xylene followed by absolute alcohol and water.

The sections were stained with Haematoxylin and Eosin, dehydrated in graded alcohol, cleared in more xylene and mounted in Canada balsam. The slides were left to dry on the hot plate for 2 hours before observation under the microscope.

Bioaccumulation Studies

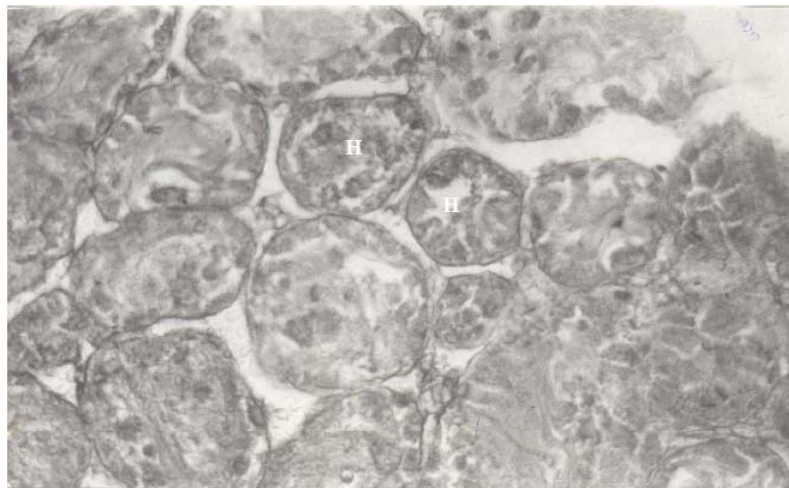
A similar experiment as described above under histopathological studies was carried out. On day 14 and 28 of the bioassays, four live snails per concentration including control were randomly selected, cleaned thoroughly in distilled water and carefully removed from their shells. The ovotestes and hepatopancreas were cut off, cleaned in distilled water and put in labeled polyethylene bags in which they are kept frozen awaiting digestion and analysis for metal content by atomic absorption spectrophotometry.

Digestion of samples: The target organs investigated for metal content were cleaned with distilled water to remove debris and other adherents before they were homogenized. A portion (5g wet weight basis) of the homogenate of each organ was digested using a freshly prepared mixture 1:1 of hydrogen peroxide and perchloric acid [20].

Table 1. Relative Acute Toxicity of Copper and Lead Salts against *Archachatina marginata*

Treatment	Time (hrs)	LC ₅₀ [95% C.L.(mM)]	LC ₉₅ [95% C.L.(mM)]	Slope ±S.E	Probit Line Equation	D.F	T.F
CuSO ₄	168	2.35 [2.72-2.03]	3.22 [4.25-2.45]	11.91 ±5.38	y = -27.96+11.91x	2	3.27
Pb(NO ₃) ₂	168	5.79 [7.22-4.64]	9.36 [14.12-6.19]	7.91 ±3.58	y = -20.96+7.91x	2	1

C.L - Confidence Limit
D.F - Degree of Freedom
T.F - Toxicity Factor
S.E - Standard Error

**Fig. (1).** Hepatopancreas of *Archachatina marginata*. Distinct hepatocytes (H) with no visible lesions.

Atomic Absorption Spectrophotometry: The heavy metal concentration in each digested sample was determined by comparing their absorbencies with those of standards (Solution of known metal concentrations) using a Perkin Elmer Analyst 200 AAS. For data quality, particular attention was paid to the cleanliness of all wares. In addition, factory prepared AAS standard solutions were run as samples for accuracy checked after every five measurements.

Statistics

Probit Analysis

The dose-response data were analyzed by Probit analysis after [21]. Probit analysis was based on a program by Ge-Le Pattouriel, Imperial College, London as adopted by [22]. The indices of toxicity measurement derived from this analysis are;

LC₉₅ - Lethal concentration that causes 95% responses (mortality) in exposed organisms.

LC₅₀ - Lethal concentration that causes 50% responses (mortality) in exposed organisms.

The Analysis of Variance (ANOVA) was carried out to compare several treatments mean at 5% (P<0.05) level of significance for appropriately designed experiments.

Bioaccumulation Capacity

Bioaccumulation Capacity (BAC) was also estimated as the ratio of the concentration of the metal in animal organ

after 28 days of exposure to the level detected in same organs of unexposed/control animals.

$$\text{Bioaccumulation Capacity (BAC)} = \frac{\text{Concentration in animal organ}}{\text{Concentration in control animals}}$$

4. RESULT

Acute Toxicity Studies of CuSO₄ and Pb (NO₃)₂ Against *Archachatina marginata*

On the basis of 168h LC₅₀, CuSO₄ with 168h LC₅₀ value of 2.35mM was found to be significantly (no overlaps in 95% confidence limit) more toxic than Pb(NO₃)₂ (5.79mM) when tested against *Archachatina marginata* (Table 1). On the basis of the derived toxicity factor, the Cu salt was found to be about three times as toxic as the Pb salt, based on the 168h LC₅₀ values (Table 1). The log-dose probit response plot depicting the toxicity profile of copper and lead salts against *A. marginata* were non-parallel, indicating that comparison of the toxicity of the test chemicals are only valid for a level of dose and response.

Histopathological Studies

The results of the histopathological effects of Cu and Pb on the hepatopancreas and ovotestes after 28 days of exposure are shown in Figs. (1-10). The results show that there were various degrees of histological alterations observed in the organs examined (hepatopancreas – Figs. (1-5) and ovotestes – Figs. (6-10)). There was a prevalence of hepatocel

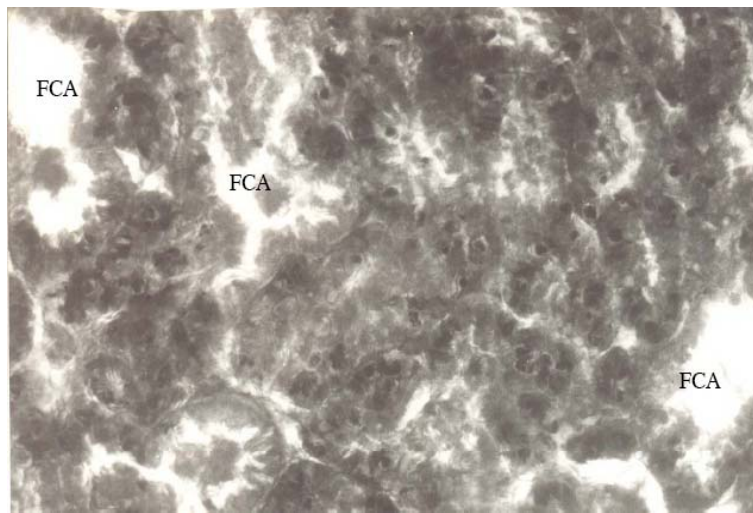


Fig. (2). Hepatopancreas of *Archachatina marginata*. Hepatic foci of cellular alterations (FCA) in the cell membranes of the hepatocytes for test animals exposed to sublethal concentrations of Cu salt.

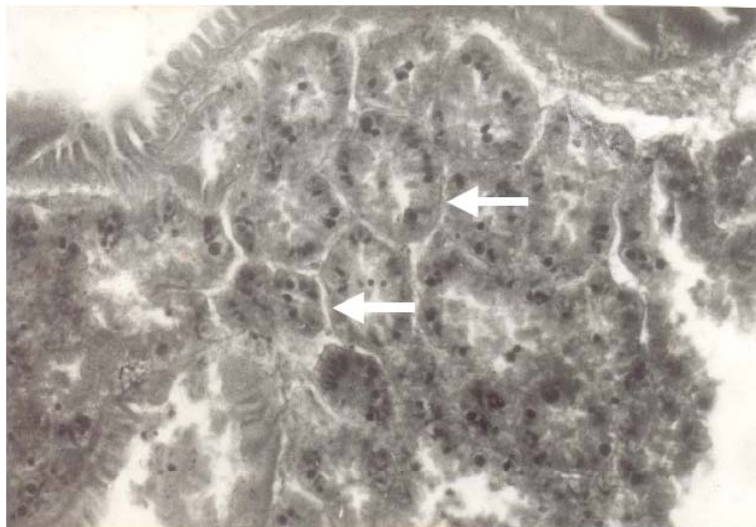


Fig. (3). Hepatopancreas of *Archachatina marginata*. Hepatocytes clogged together with peripheral thickening (arrow) in test animals exposed to sublethal concentrations of Cu salt.

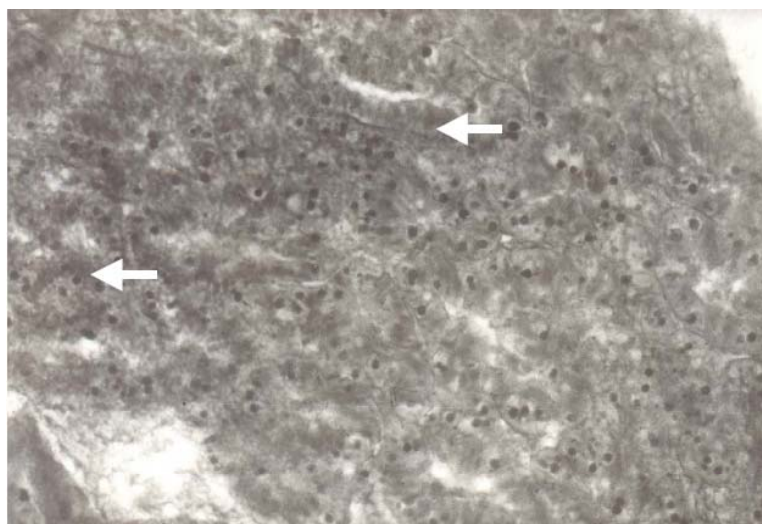


Fig. (4). Hepatopancreas of *Archachatina marginata*. Inflammation of hepatic tubules (arrow) in test animals exposed to sublethal concentrations of Pb salt.

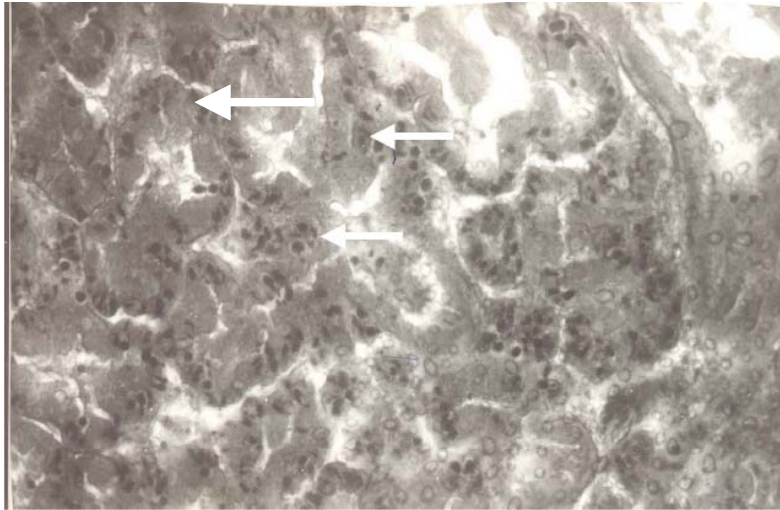


Fig. (5). Hepatopancreas of *Archachatina marginata*. Hepatic foci of cellular alterations (arrow) in the cell membranes of the hepatocytes for test animals exposed to sublethal concentrations of Pb salt.

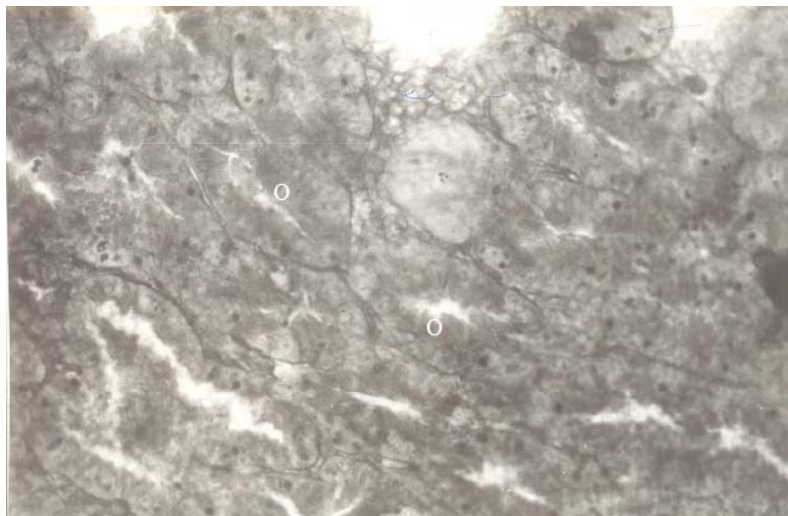


Fig. (6). Ovotestes of *Archachatina marginata*. Normal section of ovotestes showing distinct oocytes (O) for control animals.

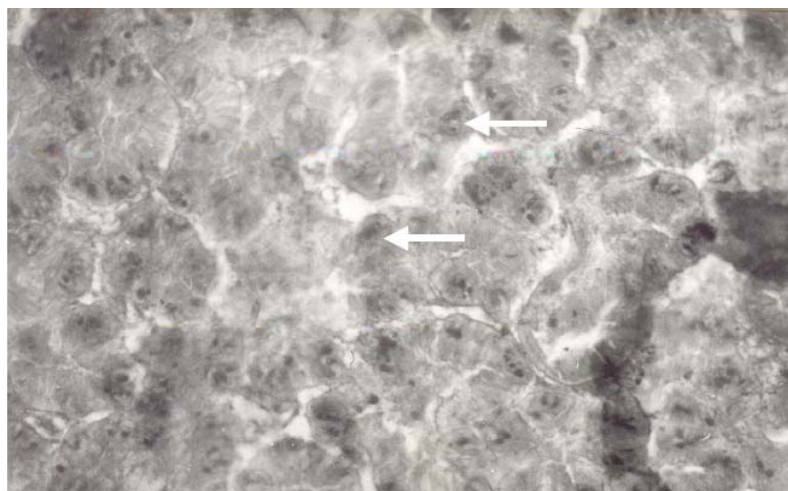


Fig. (7). Ovotestes of *Archachatina marginata*. Cellular alterations (arrow) of the ovotestes with no distinguishable oocytes in test animals exposed to sublethal concentrations of Cu salt.

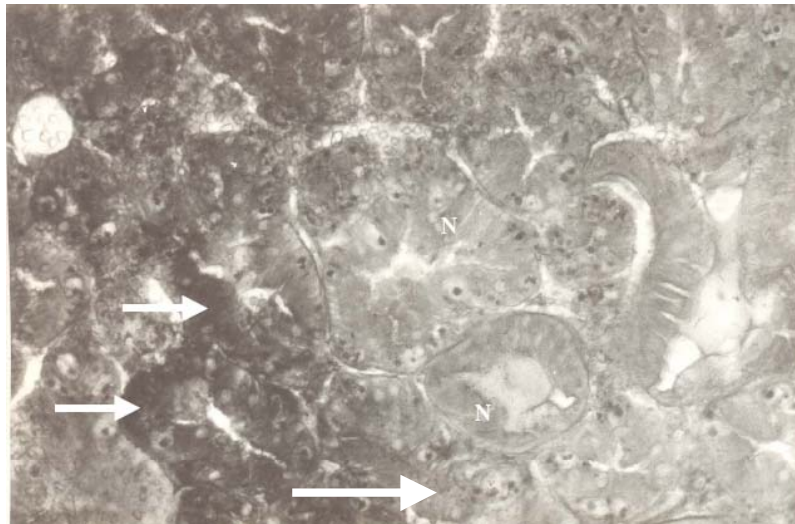


Fig. (8). Ovotestes of *Archachatina marginata*. Periphery of basophilic adenoma with differential staining characteristics (arrow) to the normal cells (N) of the ovotestes.

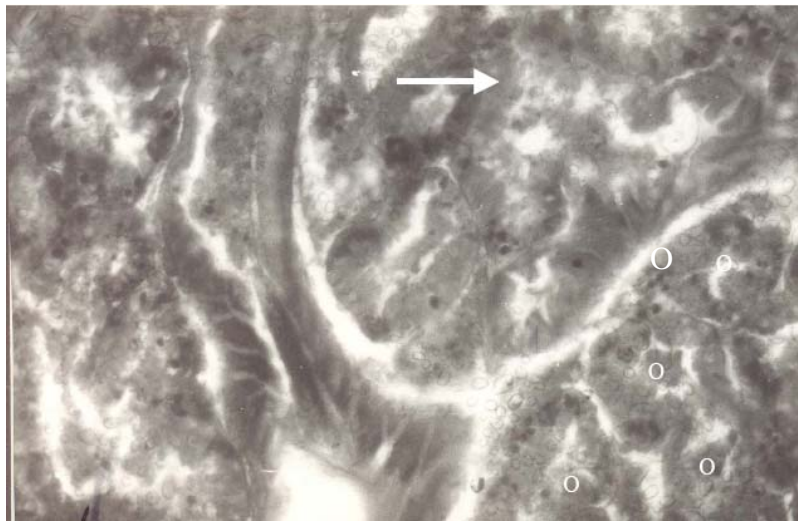


Fig. (9). Ovotestes of *Archachatina marginata*. Putative cholangioma in the ovotestes. Note the apparent proliferation of the oocytes (O) and relatively invasive nature of the lesions (arrow).

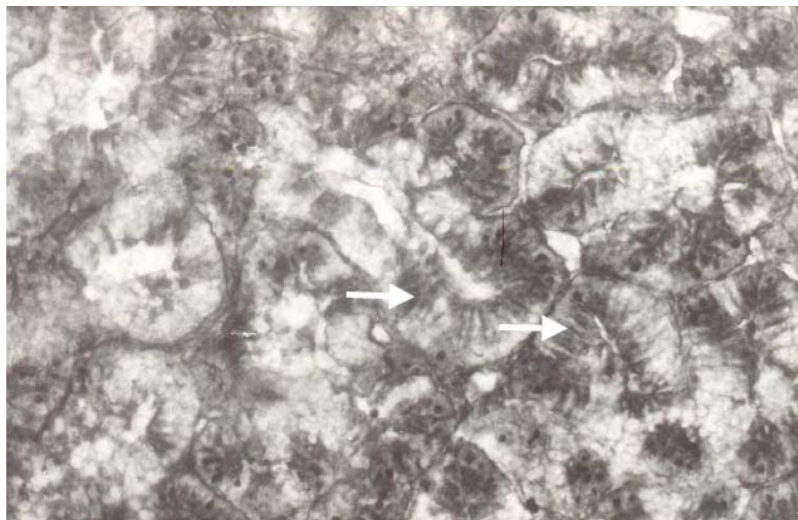

Fig. (10). Ovotestes of *Archachatina marginata*. Ovotesticular fibrillar inclusions.

Table 2. Accumulation of Cu ions by *A. marginata* Exposed to Sublethal Concentrations of the Heavy Metal Over a 28-day Period Under Laboratory Conditions

Treatment (mM)	Mean Concentrations of Cu in Organs (mg/kg)		Overall Net Gain*	
	Day 0	Day 28		BAC
Copper				
<i>Hepatopancreas</i>				
Untreated Control	1.27	1.29		
*0.0235 [1/100th of 168hr LC ₅₀]	1.27	1.35	0.06	1.05
Untreated Control	1.27	1.29		
**0.235 [1/10th of 168hr LC ₅₀]	1.27	6.08	4.79	4.71
<i>Foot</i>				
Untreated Control	1.125	1.22		
*0.0235 [1/100th of 168hr LC ₅₀]	1.125	1.11	-0.11	0.91
Untreated Control	1.125	1.22		
**0.235[1/10th of 168hr LC ₅₀]	1.125	3.19	1.97	2.62

*overall net gain=concentration in snails after 28 days- concentration in animal at day zero.

*1/100th 168hrLC₅₀ value of Cu ions in the test media.

**1/10th of 168hr LC₅₀ values of Cu ions in the test media.

lular foci of cellular alterations (FCA) in the hepatopancreas of snails exposed to sublethal concentrations of copper and lead (Figs. 2 & 5). Hepatocytes of test animals exposed to sublethal concentration of Cu were also observed to be clogged together with peripheral thickening (Fig. 3) while exposure to lead caused inflammation of hepatic tubules (Fig. 4). Basophilic adenoma was recorded in the ovotestes of snails exposed to the copper compound (Fig. 8). In addition, one case of cholangioma, a benign neoplastic lesion involving the proliferation of the oocytes was recorded in sections of the snails exposed to lead compound (Fig. 9). Ovotesticular fibrillar inclusions were also observed in ovotestes of test animals exposed to sublethal concentrations of lead compound (Fig. 10).

5. BIOACCUMULATION STUDIES

Hepatopancreas

Post treatment analysis of the hepatopancreas of *A. marginata* showed that in the snails exposed to sublethal concentrations of 0.235mM (1/10th of LC₅₀) and 0.0235mM (1/100th of LC₅₀) of the copper ions, there was an overall gain of 4.842mg/g and 0.08mg/g respectively than the level detected in control animals over the 28 days period of observation (Table 1). On the basis of the bioaccumulation capacity (BAC), the snails exposed to sublethal concentrations of 0.235mM (1/10th of LC₅₀) and 0.0235mM (1/100th of LC₅₀) accumulated Cu ions that was about 5 times and 1.04 times respectively higher than the levels detected in control animals over the 28 days period of observation (Table 1).

With regards to lead, post treatment analysis of the hepatopancreas of *A. marginata* showed that in the snails exposed to sublethal concentrations of 0.579mM (1/10th of LC₅₀) and 0.0579mM (1/100th of LC₅₀) of the lead ions, there was an overall gain of 67.014mg/g and 1.131mg/g respectively, relative to the level detected in control animals over the 28 days period of observation (Table 2). On the basis of the bioaccumulation capacity (BAC), the snails exposed to sublethal concentrations of 0.579mM (1/10th of LC₅₀) and 0.0579mM (1/100th of LC₅₀) accumulated Pb ions that was about 375 and 7 times, respectively, higher than the levels detected in control animals over the 28 days period of observation (Table 2).

Foot

Post treatment analysis of the edible muscular foot of *Archachatina marginata* showed that in the snails exposed to sublethal concentrations of 0.235mM (1/10th of LC₅₀) and 0.0235mM (1/100th of LC₅₀) of the copper ions, there was an overall gain of 1.97mg/g and -0.11 mg/g respectively, relative to the level detected in control animals over the 28 days period of observation (Table 1). On the basis of the bioaccumulation capacity (BAC), the snails exposed to sublethal concentrations of 0.235mM (1/10th of LC₅₀) and 0.0235mM (1/100th of LC₅₀) accumulated Cu ions that was about 2.62 times and 0.91 times, respectively, higher than the levels detected in foot of the control animals over the 28 days period of observation (Table 1).

Table 3. Accumulation of Pb Ions by *A. marginata* Exposed to Sublethal Concentrations of the Heavy Metal Over a 28-day Period Under Laboratory Conditions

Treatment (mM)	Mean Concentrations of Pb in Organs (mg/kg)		Overall Net Gain*	
	Day 0	Day 28		BAC
Lead				
<i>Hepatopancreas</i>				
Untreated Control	0.17	0.18		
*0.0579[1/100th of 168hr LC ₅₀]	0.17	1.31	1.13	7.32
Untreated Control	0.17	0.18		
**0.579 [1/10th of 168hr LC ₅₀]	0.17	67.19	67.01	375.55
<i>Foot</i>				
Untreated Control	0.05	0.06		
*0.0579[1/100th of 168hr LC ₅₀]	0.05	0.09	0.03	1.55
Untreated Control	0.05	0.06		
**0.579 [1/10th of 168hr LC ₅₀]	0.05	71.61	71.55	1234.66

*overall net gain=concentration in snails after 28 days- concentration in animal at day zero.

*1/100th 168hrLC₅₀ values of Pb ions in the test media.

**1/10th of 168hr LC₅₀ values of Pb ions in the test media.

With regards to lead, post treatment analysis of the muscular edible foot of *A. marginata* showed that in the snails exposed to sublethal concentrations of 0.579mM (1/10th of LC50) and 0.0579mM (1/100th of LC50) of the lead ions, there was an overall gain of 71.55mg/g and 0.03mg/g respectively, relative to the level detected in control animals over the 28 days period of observation (Table 2). On the basis of the bioaccumulation capacity (BAC), the snails exposed to sublethal concentrations of 0.579mM (1/10th of LC50) and 0.0579mM (1/100th of LC50) accumulated Pb ions that was about 1200 and 1.55 times, respectively, higher than the levels detected in the edible muscular foot of control animals over the 28 days period of observation (Table 2).

6. DISCUSSION

In this study, the copper compound was found to be about three times more toxic than lead compound when tested against the giant land snail *Archachatina marginata*. This observation is in agreement with earlier works on heavy metal toxicity profiles. According to Otitolaju and Don-Pedro [3], lead was found to be consistently the least toxic test metal compared to Hg, Cd, Cu and Zn when tested against *Tympanotonus fuscatus*, *Clibanarius africanus* and *Sesarma huzardi*. Other workers [23, 24] have demonstrated the relatively higher toxicity of copper compound than lead when tested against *Helix aspersa*. They reported that the higher toxicity of copper may be due to its ability to form complexes with anions and also because Cu (II) induces the oxidation of quinone and may be a factor in the oxidative

activation and toxicity of hydroquinone in target cells. According to Oyewo [25] and Otitolaju [26], the low toxicity of Pb maybe due to low penetrability in exposed organisms and the ability of the exposed animals to accumulate the Pb ions in its body tissue without ill effects or lethal action.

The exposure of the snails to sublethal concentrations of heavy metals caused varying degrees of histological alterations in the organs examined (hepatopancreas and ovotestes). In the hepatopancreas, there was a prevalence of hepatocellular foci of cellular alterations (FCA) in snails exposed to the sublethal concentrations of copper and lead. Peripheral thickening and inflammation of hepatic tubules of the hepatocytes were also observed in exposed snails. These neoplastic changes in the hepatopancreas have been reported to represent transitional lesions that bridge the gap between hepatocellular FCA's and malignant lesions such as hepatocellular carcinoma [10]. Hepatocellular FCAs is therefore categorised as an early stage in the stepwise formation of hepatic neoplasia and as such provide an excellent example of a histopathological biomarker for contaminant exposure [27].

In the ovotestes, basophilic adenoma was recorded in snails exposed to the sublethal concentrations of copper. A benign neoplastic lesion, cholangioma involving the proliferation of oocytes in ovotestes was also recorded in sections of snails exposed to sublethal concentrations of lead. According to Brooks and Roe [28], long term administration of carcinogenic compounds can result in the formation of adenomatous hyperplasia, which can progress to cholangioma. As a result, the observation of this lesion type is usually as-

sociated with the development of carcinogenesis hence the influence of lead to cause such lesion type in the current study merits further studies before its inclusion as a biomarker of exposure to lead can be justified. Furthermore, ovotesticular fibrillar inclusions were also recorded in snails exposed to sublethal concentrations of lead. These inclusions have been reported to be an unusual proliferation of the rough endoplasmic reticulum (RER) and/or an extensive formation of microtubules [29]. Although the significance of these fibrillar inclusions as indicators of contaminant exposure is not entirely understood [10], the prevalence of the inclusions in exposed snails is quite suggestive of its role as an important histological biomarker of exposure to lead.

Due to the fact that the giant land snail *A. marginata* is an important edible animal and the current spate of snail farming going on in many developing countries where it thrives, the establishment of the bioaccumulation capacity of the snail for heavy metals that are readily found in its environment such as Cu and Pb is an important public health issue that must be considered under any meaningful biomonitoring regime/programme. In the current study, the snails were found to have the capacity to accumulate the metals to varying degrees, depending on the concentration of exposure and metal type. With regards to copper, exposure of the snails to 0.0235mM (1/100th of 168hLC50 value) of copper compound indicate (negative net gain value) an ability of the snail to regulate and excrete excess level of copper ions in its body. However, exposure to the higher sublethal concentration of 0.235mM (1/10th of 168hLC50 value) of the copper compound resulted in a five-fold and three-fold accumulation of the metal in the hepatopancreas and muscular foot respectively compared to the control animal. The observed ability of the snail to regulate Cu is not particularly surprising because copper is a component of haemocyanin, which is a respiratory pigment in the body fluids of *A. marginata*. Otitoloju and Don-Pedro [4] reported the ability of another molluscan species, *Tympanotonus fuscatus* to regulate its body concentration of copper under laboratory and field experimental conditions. Similarly, Bryan and Langston [6] also reported the ability of polychaete worms, *Melinna palmate* (which naturally has high concentration of Cu in its tissues) and *Tharyx marionti* to regulate their tissue concentration of Cu. This capacity to regulate their tissue concentration of Cu by excretion however becomes hindered as the system becomes overloaded resulting in the initiation of other detoxication processes such as accumulation in an innocuous state. According to Hopkin [23], a number of studies have shown that Cu can be deposited as insoluble intracellular membrane-bound granules in the hepatopancreas of most terrestrial invertebrates and/or transiently detoxified through synthesis of low-molecular-weight protein e.g. metallothionein which binds the metal ions [30, 31].

The exposure of the snails to sublethal concentrations of Pb revealed that the snails had high capacity to accumulate the metal in both the hepatopancreas and muscular foot. While accumulation in the hepatopancreas were found to be up to 375-fold, an unprecedented accumulation of over 1000-fold compared to the concentrations detected in control animals was observed in the edible muscular foot. This high accumulation (up to 71.55 mg/kg) of lead in edible portion of the snails is particularly disturbing and of public health

importance when compared to the maximum permissible intake of 3 mg Pb per week. Several authors [3, 4, 30, 31] have reported the ability of several animals to progressively accumulate Pb in their body tissues. Williamson and Evans [32] had indicated that the widespread tolerance of snails to Pb contamination may be due to the fact that the animals are exposed to relatively high concentrations in their natural environment. According to these authors, Pb concentrations in the soil may sometimes reach up to 200 mg/kg. Thus soil and epigeic invertebrates could be evolutionarily 'pre-adapted' to tolerate high Pb concentrations. Beeby and Richmond [33] also suggested that Pb assimilation and excretion is under control of a physiological mechanism that is able to adapt to high concentrations of this metal in its food. This ability of the snails to adapt to lead contamination and accumulate high concentration of the metal in the edible part therefore implies an urgent need to institute a continuous monitoring of the snails and soils where they are reared or collected to avert a looming public health problem that might arise under a no-control situation.

In summary, an array of toxicopathic organ or tissue alterations were observed in this terrestrial mollusc, *Archachatina marginata* found in metal laden environment. These changes represent a biological end-point of contaminant exposure and as such this study reinforces the application of histopathology as a powerful tool for monitoring anthropogenic contamination of terrestrial environments. When these pathological end points are assessed in conjunction with the capacity of the animals to accumulate these contaminants e.g. heavy metals in the body tissues, a clearer picture of the complex interactions between anthropogenic and natural environmental modifiers will emerge. This will ensure early detection of impending environmental problems that may ensue and also avert potential human health tragedies.

REFERENCES

- [1] Balkas IT, Tugrel S, Salhoglu I. Trace metals levels in fish and crustacean from Northeastern Mediterranean coastal waters. *Mar Environ Res* 1982; 6: 281-9.
- [2] Tuzen M. Determination of heavy metals in fish samples of the middle Black Sea (Turkey) by graphite furnace atomic absorption spectrometry. *Food Chem* 2003; 80: 119-23.
- [3] Otitoloju AA, Don-Pedro KN. Bioaccumulation of heavy metals (Zn, Pb, Cu and Cd) by *Tympanotonus fuscatus* var. *radula* exposed to sublethal concentrations of the test metal compounds in laboratory assays. *West Afr J Appl Ecol* 2002; 3: 17-29.
- [4] Otitoloju AA, Don-Pedro KN. Integrated laboratory and field assessments of heavy metals accumulation in edible periwinkle, *Tympanotonus fuscatus* var. *radula* (L.). *Ecotoxicol Environ Saf* 2004; 57(3): 354-62.
- [5] Nuenberg KJ. Fresh water molluscs as sentinel organisms of heavy metal accumulation in fresh water ecosystems. *J Environ Pollut* 1984; 16: 26-33.
- [6] Bryan GW, Langston WJ. Bioavailability, accumulation and effects of heavy metals in sediments with special reference to United Kingdom estuaries: a review. *Environ Pollut* 1992; 76(2): 89-131.
- [7] Kiffney PM, Clement WH. Bioaccumulation of heavy metals by benthic invertebrates at the Arkansas River, Colorado. *Environ Toxicol Chem* 1993; 12(8): 1507-17.
- [8] Coughtrey PJ, Martin MH. The distribution of Pb, Zn, and Cu within the pulmonate mollusc *Helix aspersa*. *Oecologia* 1976; 23: 315-22.
- [9] Matthiessen P, Thain JE, Law RJ, Fileman TW. Attempts to assess the environmental hazard posed by complex mixtures of organic chemicals in UK estuaries. *Mar Pollut Bull* 1993; 26: 90-95.

- [10] Stentiford GD, Longshaw M, Lyons BP, Jones G, Green M, Feist SW. Histopathological biomarkers in estuarine fish species for the assessment of biological effects of contaminants. *Mar Environ Res* 2003; 55: 137-59.
- [11] Stentiford GD, Feist SW. A histopathological survey of shore crab (*Carcinus maenas*) and brown shrimp (*Crangon crangon*) from six estuaries in the United Kingdom. *J Invert Pathol* 2005; 88: 136-46.
- [12] Myers MS, Stehr CM, Olson OP, *et al.* Relationship between toxicopathic hepatic lesions and exposure to chemical contaminants in English sole (*Pleuronectes vetulus*), starry flounder (*Platichthys stellatus*) and white croaker (*Genyonemus lineatus*) from selected sites on the pacific coast, USA. *Environ Health Perspect* 1994; 102: 200-15.
- [13] Myers MS, Johnson LL, Hom T, Collier TK, Stein JE, Varanasi U. Toxicopathic lesions in subadult English sole (*Pleuronectes vetulus*) from Puget Sound, Washington USA: relationships with other biomarkers of contaminant exposure. *Mar Environ Res* 1998; 45: 47-67.
- [14] Bogovski S, Lang T, Mellergaard S. Histopathological examinations of liver nodules in flounder (*Platichthys flesus* L.) from the Baltic Sea. *ICES J Mar Sci* 1999; 56: 152-6.
- [15] Varanasi U, Stein JE, Nishimoto M, Reichert WL, Collier TK. Chemical carcinogenesis in feral fish: uptake, activation and detoxication of organic xenobiotics. *Environ Health Perspect* 1987; 71: 155-70.
- [16] Vethaak AD, Jol JG, Meijboom A, *et al.* Skin and liver diseases induced in flounder (*Platichthys flesus* L.) after long-term exposure to contaminated sediment in large scale mesocosms. *Environ Health Perspect* 1996; 104: 1218-29.
- [17] Pilsbry HA. Family archatiniidae. *Manual Onchol* 1904; 16: 205-325.
- [18] Egonmwan RI. Reproductive biology and growth of the land snail *Archachatina maginata ovum* and *Limicolaria flammea*. Ph.D. Thesis. London: University of Oxford, 1988; pp. 186.
- [19] Ajayi SS, Tewe CM, Awesu MO. Observation on the biology and nutritive value of the African Giant Land snail *Archachatina maginata*. *East Afr Wild J* 1978; 16: 85-95.
- [20] FAO/SIDA. Manual of methods in aquatic environmental research, part 9. Analyses of metals and organochlorines in fish. FAO Fish/Tech. Paper, Rome 1986; pp. 212.
- [21] Finney DJ. Probit Analysis. 3rd ed. London: Cambridge University Press 1971.
- [22] Don-Pedro KN. Mode of action of fixed oils against eggs of *Callosobruchus maculatus* (L). *Pestic Sci* 1989; 26: 107-15.
- [23] Hopkin SP. Ecophysiology of metals in terrestrial invertebrates. New York: Elsevier 1989; p. 323.
- [24] Dallinger R, Janssen HH, Bauer-Hilty A, Berger, B. Characterization of an inducible cadmium-binding protein from hepatopancreas of metal-exposed slugs (*Arionidae*, Mollusca). *Comp Biochem Physiol* 2000; 92: 355-60.
- [25] Oyewo EO. Industrial sources and distribution of heavy metals in Lagos lagoon and their biological effects on estuarine animals. Ph.D. Thesis. Nigeria: University of Lagos 1998; p. 274.
- [26] Otitoloju AA. Joint action of heavy metals and their bioaccumulation by benthic animals of lagos lagoon. Ph.D Thesis. Nigeria: University of Lagos 2001; p. 231.
- [27] Hinton DE, Baumen PC, Gardener GC, Hawkins WE, Hendricks JD, Okhiro MS. Biochemical, physiological and histological biomarkers of anthropogenic stress in terrestrial environments. In: Hugget RJ, Kummel RA, Merhle PM, Eds. *Histopathological Biomarkers*. USA: M.I Lewis Publishers 1992; pp. 155-210.
- [28] Brooks PN, Roe FJC. In: Digestive system. 2nd ed. *Monographs on pathology of laboratory animals*. Cholangioma, liver, rat. Germany: Springer-Verlag 1997; pp. 83-6.
- [29] Köhler AU. Identification of contaminant-induced cellular and subcellular lesions in the liver and gonads of flounder (*Platichthys flesus* L.) caught at different polluted estuaries. *Aquat Toxicol* 1990; 16: 271-94.
- [30] Langston WJ, Zhou M. Cadmium accumulation, distribution and metabolism in gastropod *Littorina littorea*: the role of metal-binding proteins. *J Mar Biol Ass UK* 1987; 67: 585-601.
- [31] George SG. Cadmium effects on plaice liver xenobiotic and metal detoxication systems: dose-response. *Aquat Toxicol* 1989; 15: 303-10.
- [32] Williamson P, Evans PR. A preliminary study of the effect of high levels of inorganic lead on soil fauna. *Pedobiology* 1973; 13: 16-21.
- [33] Beeby A, Richmond L. Adaptation by an urban population of the snail *Helix aspersa* to a diet contaminated with lead. *Environ Pollut* 1987; 46: 73-82.

Received: April 06, 2009

Revised: May 08, 2009

Accepted: May 18, 2009

© Otitoloju *et al.*; Licensee Bentham Open.

This is an open access article licensed under the terms of the Creative Commons Attribution Non-Commercial License (<http://creativecommons.org/licenses/by-nc/3.0/>) which permits unrestricted, non-commercial use, distribution and reproduction in any medium, provided the work is properly cited.