

Actocardiogram

Kazuo Maeda*

Department of Obstetrics and Gynecology (Emeritus), Tottori University Medical School, Yonago, Japan

Abstract: *Aims:* To objectively study fetal movements, clarify fetal behavior, identify false positive fetal heart rate (FHR), estimate fetal outcome, and study fetal response to external stimuli, using an actocardiogram (ACG).

Methods: The ACG is a chart record that simultaneously traces FHR and fetal movements by continuous wave (CW) ultrasonic Doppler signals of fetal heart beats and movements using a single probe. In addition, uterine contraction is recorded in clinical models.

Results: Signals from fetal movements are clustered to form bursts and characterized by 5 indices of mean duration, occupancy, frequency, ratio of duration of FHR acceleration to movement bursts (A/B ratio), and the ratio of acceleration count to the bursts; fetal behavior was classified into resting, active, hyperactive and intermediate states; non-reactive FHR was differentiated from fetal resting FHR; sinusoidal FHR was separated from benign physiologic one; and sinus bradycardia was separated from hypoxia. Interval of fetal hiccups was 2 sec, and hiccups lasted for 20 minutes or more and tended to repeat in a day. The severity ranking of fetal central nervous system lesion and fetal disorder outcome were assessed using the A/B ratio. The correlation coefficient of FHR and movement increased if the movement delayed. A fetus responded to sound light stimulation in ACG; fetal sensitivity increased in late pregnancy.

Conclusion: The controversial obtained used a cardiotocogram were resolved using the ACG. It opened new objective fields in perinatal medicine.

Keywords: Actocardiogram, Fetus, Heart rate, Fetal movement, Fetal behavior, Fetal monitoring, Fetal outcome, Ultrasound, CW Doppler.

INTRODUCTION

Pregnant women are aware of fetal well-being when they experience frequent quickening, and are concerned about fetal deterioration with a decrease in the frequency or intensity of fetal movements. Then pregnant women who visited a clinic were asked by some physicians to count the fetal movements in a unit of time to assess the fetal status. In addition, fetal well-being was also assessed using the non-stress test (NST) of cardiotocogram (CTG) that records fetal heart rate (FHR) and uterine contraction but no fetal movement, where the FHR acceleration detected at fetal movement perception was the parameter of fetal well-being. The NST, however, would be incorrect if the fetal movement was recorded with maternal perception, because pregnant women are unable to perceive more than 30 % of the fetal movements, i.e. the count of fetal movement perception was 64 % to 68 % of fetal movements counted on the actocardiogram (ACG) [1, 2]. In addition, the perception of fetal movement by pregnant women is a subjective feeling. A mechanical or electric fetal movement sensor placed on maternal abdominal surface will act as indirect maternal perception because the sensor would detect fetal movements just reached at the maternal abdominal surface. Further, perception of fetal hiccups and counting them as fetal movement is incorrect, because there is no FHR acceleration in fetal hiccups. On the con-

trary, the ACG directly detects correct movements of the fetal trunk using the ultrasound signals reflected from the fetal trunk, and fetal hiccups were correctly recognized on the ACG chart without FHR acceleration [3]. The fetal movement and fetal behavior played important role in the determination of biophysical profile score. Although real-time ultrasonic B-mode image enables direct observation of fetal movements, it will be incompletely objective because the events of fetal movement recorded on the monitoring chart are marked by the B-mode screen observer. Prolonged monitoring may not be easy using the B-mode image observation, while fully objective, automatic and prolonged fetal movement monitoring is required in fetal NST and behavioral studies.

To address the issue of false positive FHR was another purpose of objective recording of the fetal movement using the ACG, because there are problems in fetal studies using the CTG or electronic fetal monitoring (EFM) which record only FHR and uterine contraction.

METHODS

The continuous wave (CW) ultrasound reflected from the fetal trunk produces Doppler signals by the fetal movements. The CW ultrasound of ACG is safe even in prolonged monitoring because the intensity of output ultrasound is as weak as 1 mW/cm^2 in the recent ACG models. Because the Doppler signal frequency of fetal movement was as low as 20 to 50 Hz, and the Doppler signal of fetal heart was higher than 100 Hz when the ultrasound is 2 MHz, a single ultrasound

*Address correspondence to this author at the 3-125, Nadamachi, Yonago, Tottoriken, 683-0835 Japan; Tel/Fax: +81-859-22-6856; E-mail: maedak@mocha.ocn.ne.jp

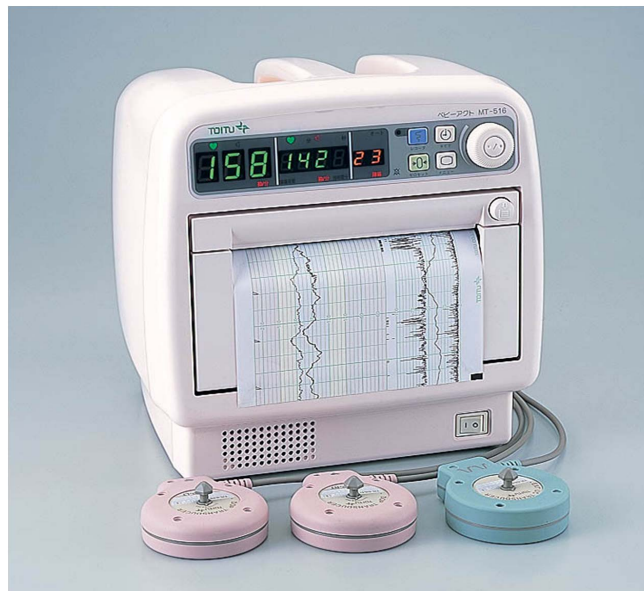

Fig. (1). Actocardiograph MT516 (TOITU, Tokyo).

Fetal actocardiograms are traced in each two channels of twin fetal heart rate and movement. Two ultrasound probes and single contraction probe are prepared to monitor twin pregnancy in ante- and intrapartum periods. A singleton pregnancy is monitored as well.

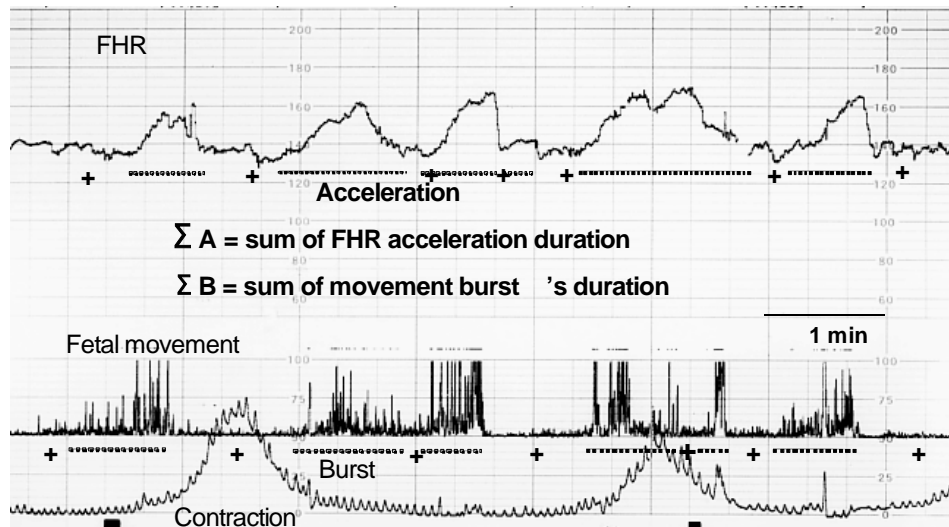


Fig. (2). Active fetal state in the ACG and the determination of A/B ratio. Frequent fetal movement bursts are synchronized with frequent FHR accelerations.

The A/B ratio = ΣA (Sum of acceleration duration) / ΣB (Sum of fetal movement burst duration).

probe can simultaneously detect Doppler signals of fetal heart beat and movement and separate both signals with a band-pass filter, i.e. fetal movement recording in the ACG does not increase the exposure to ultrasound if compared to the common ultrasound FHR monitor. Doppler signals of fetal movement were rectified and changed to low frequency spikes to record movement using the CTG chart recorder [3]. Various physiologic and pathologic changes in the fetus were objectively analyzed using the FHR and movements recorded on the ACG chart.

The first ACG device was produced by the author by the addition of a band-pass filter, amplifiers and the spike forming circuit to used TN-4000 ultrasonic fetal CTG monitor, where fetal movement signals instead of uterine contraction were traced on the CTG chart [3]. The first commercial model was MT-320, and it was followed by MT-325, MT-

332, MT-333U, MT-430, MT-540, MT-516, MT-517, MT-522 and MT-523 (TOITU, Tokyo). Recent MT-516 model traces each of the 2 signals FHR and fetal movement channels and single contraction FHR channel for twin pregnancies (Fig. 1).

The attachment of probes on maternal abdomen is the same as common CTG, where the location of ultrasound probe is adjusted to clearly listen to the sounds of fetal heart beat using the monitor speaker. The recording chart is also similar to the CTG, where the chart speed is 3 cm/min. Recorded fetal movement spikes are traced between the FHR and contraction channels (Fig. 2). Supplementary dots show the presence of fetal movements recorded parallel with the movement spikes, where the spike records are better to recognize fetal movement bursts.

Table 1. ACG Parameter Values in 4 Fetal States

Behavioral States	Movement Burst			A/B Ratio	N
	Duration	Occupancy	Frequency		
	(sec)	(%)	(CPM)		
Resting	0	0	0	0/0	12
Active	29.7±10.3	32.7±14.8	0.7±0.2	1.4±0.4	14
	S S	S	S		
Intermediate	17.7±3.7	6.4±1.8	0.2±0.03	1.2±0.3	5
	S	S			
Hyper-active	88.6±14.6	44.1±5.3	0.5±0.3	1.2±0.1	3

S: significant difference (p<0.05)

The ACG enables visual diagnosis or quantification of charts and computer processing of FHR and movements [4]. A fetal movement burst usually clusters 10 to 15 movement spikes in around 10 to 30 sec. The bursts are separated from each other by an interval of no or minimal signals, and the burst is associated with FHR acceleration in normal active fetal states (Fig. 2).

Quantified fetal movements are characterized by (1) mean burst duration, (2) occupancy (percentage of the sum of burst duration to whole record length), (3) frequency (the count of movement bursts in one minute), (4) the A/B ratio (the ratio of the sum of duration of FHR acceleration to that of the movement bursts (Fig. 2) and (5) the ratio of acceleration count to bursts [5].

Fetal behavioral states were classified by the states on the basis of FHR acceleration, FHR baseline variability and fetal movement bursts.

The ACG of 12 cases of central nervous system (CNS) lesion were studied on their ranking [6], and the ACG of 20 other fetal disorders were studied in relation to their outcome [7]. The ACG charts and patient records were offered from the obstetric and gynecologic departments of Tottori and Kyushu university hospitals, and from the friends of the authors. The ACG of patients with pathological conditions was recorded in the pregnancy after 28 weeks of gestation, except for an anencephalic fetus and the control case in 18 weeks [8]. ACG was recorded in normal controls at 28 to 41 weeks. The ACG of these cases was analyzed by the author himself. The earliest recording of ACG was made at 14 weeks of pregnancy in the studies on fetal response to external stimuli [9].

Cross correlation of the signals of FHR and fetal movement was studied using computer analysis, where the largest correlation coefficient was obtained after the delay of fetal movement signals [10].

Fetal response to the sound and light stimuli was studied using the fetal movement and FHR acceleration of ACG, where the sound of the loud speaker was 250, 500 or 1,000 Hz sine wave, and the sound intensity was determined by audiometer at 1 meter apart from the loud speaker. The light

source was photographic speed light of which guide number was 20 ISO 100 [9].

RESULTS

Although the ACG was frequently used successfully for common antepartum NST and intrapartum fetal monitoring in clinical obstetric practice from its CTG function, the ACG have also achieved particularly unique objective results in the following fields with the application of its fetal movement channel.

Fetal Movement Bursts

Fetal movement traces show characteristic clusters of around 0.8 Hz spikes in about 30 sec in active fetal states, and are known as “fetal movement bursts” [3]. Intervals of no remarkable signal are inserted between each bursts (Fig. 2, Table 1), except for continuous or periodic one Hz fetal respiratory movements and continuous 0.5 Hz fetal hiccups (Figs. 6 and 7). The movement burst was absent in the loss of FHR variability and acceleration, and in true sinusoidal FHR, both immediately before the fetal demise. The movement burst transiently diminished after the severe variable deceleration which was supposed to be fetal hypoxia.

The movement bursts accompany FHR accelerations in active fetal state (Fig. 2), and periodic respiratory movements associated with physiologic sinusoidal FHR was the marker to differentiate it from truly ominous sinusoidal FHR (Fig. 5) [11].

Fetal Behavior

Nijhuis [12] used ultrasonic B-mode, FHR and fetal eye movements to classify fetal behavior into 1F, 2F, 3F and 4F. Fetal behavior is also classified using ACG in the present study into resting, active, intermediate and hyper-active state [13].

The resting fetal state was characterized by the absence of both FHR acceleration and fetal movement burst, where FHR baseline was stable, and the FHR variability was normally preserved with 3 to 6 cycles per minute (cpm) variations. The duration of resting fetal state was 20 to 40 min (Table 1, Fig. 3).

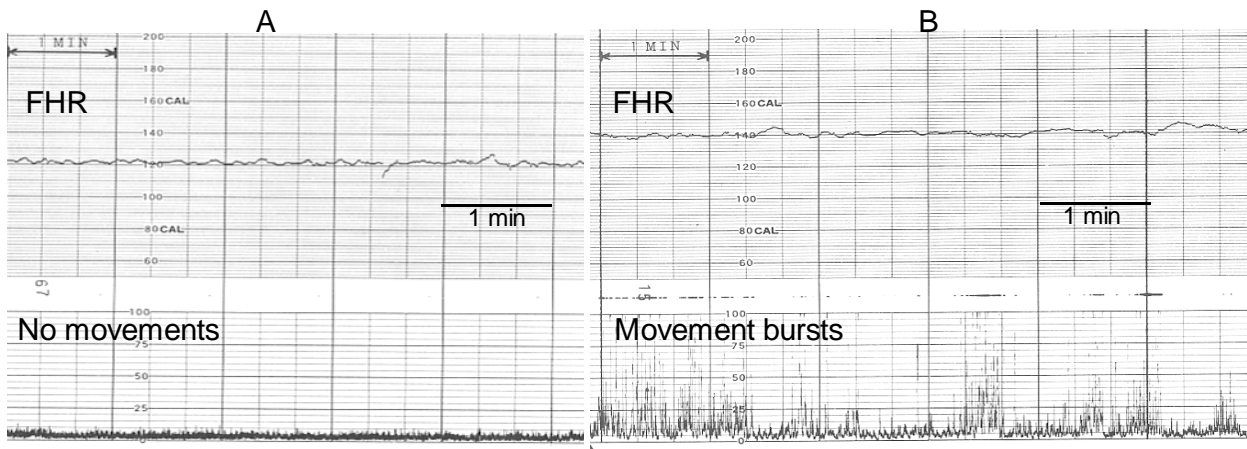


Fig. (3). (A) Resting fetal state is characterized by neither acceleration nor fetal movement, where variability is normal. (B) Non-reactive FHR is differentiated from the resting fetal state by the presence of active fetal movement bursts in spite of absent FHR acceleration, while the variability is preserved. Continuous monitoring is mandatory in non-reactive FHR because of frequent appearance of severe hypoxic changes within a few days where an emergency cesarean section is performed.

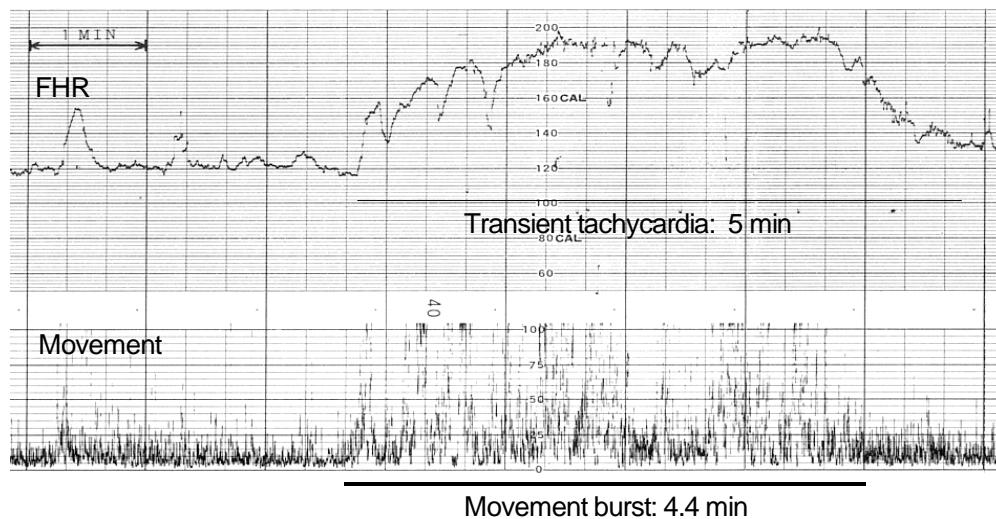


Fig. (4). Hyper-active fetal state: FHR shows transient tachycardia associated with prolonged fetal movement burst.

The active fetal state showed multiple fetal movement bursts synchronized with FHR accelerations and the FHR baseline variability was remarkable. The occupancy value of movement bursts was 33 % of the active stage in average, and the burst frequency was nearly once in one min (1 cpm). Duration of active fetal state is 30 to 50 min (Table 1 and Fig. 2).

Intermediate fetal state showed small, short and sporadic movement bursts associated with minor FHR accelerations, just between the resting and active states (Table 1).

Hyperactive fetal state showed long lasting fetal movements associated with prolonged FHR rise resulting in transient tachycardia, where the movement burst duration was 90 sec in average and its upper range was 4.5 min (Table 1, Fig. 4).

The ratio of duration of FHR acceleration to the movement burst (A/B ratio) was greater than 1 in each active, intermediate and hyperactive states of normal fetus (Table 1).

Four behavioral states were easily classified with the ACG (Figs. 2-4).

Differentiation of False Positive FHR from Truly Pathological FHR Changes

False Positive Non-reactive FHR

The resting state of normal fetus and ominous non-reactive FHR were difficult to separate using a CTG, because both shows no FHR acceleration and preserved baseline variability, i.e. fetal resting state was the false positive non-reactive FHR in this case. Although resting fetal state lasts for 10 to 40 minutes and followed by an active fetal state, prompt diagnosis with single test is the best, and that is the ACG, i.e. fetal resting state accompanies no fetal movement burst while multiple movement bursts are recorded in the non-reactive FHR (Fig. 3).

In addition, resting fetal state is separated from fetal hypoxia by the presence of normal baseline variability. The continuous fetal respiration traces 1 Hz spikes in fetal movement channel without FHR acceleration but character-

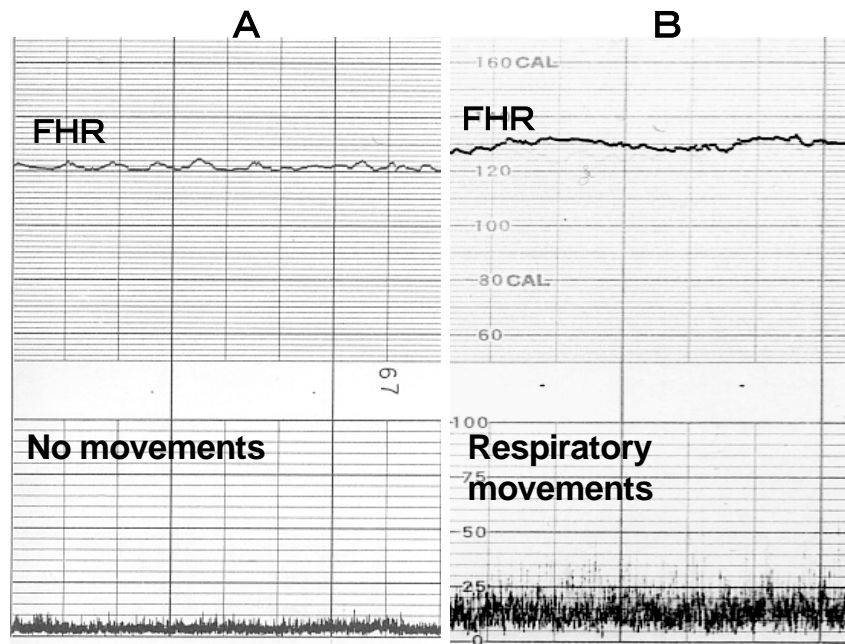


Fig. (5). Continuous fetal respiratory movements.
 A: Normal fetal resting state.
 B: Continuous fetal respiratory movements of which interval was 1 second, i.e. the frequency was 1 Hz.

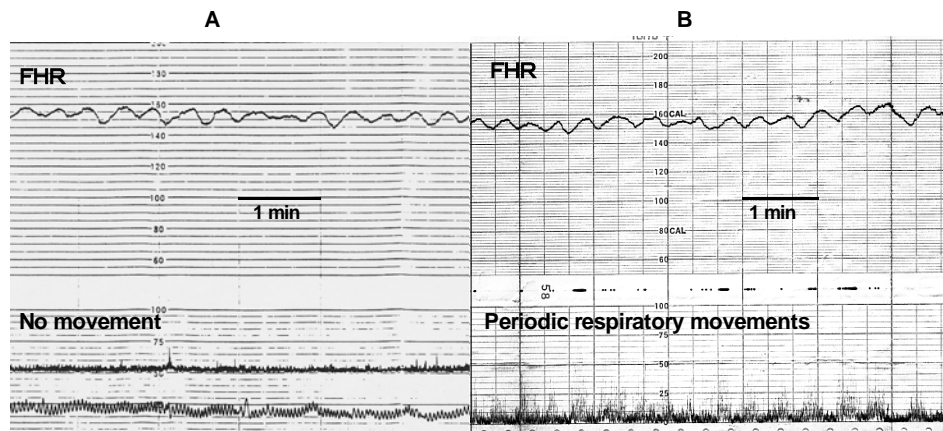


Fig. (6). Sinusoidal FHR: (A) true ominous one before fetal demise, and (B) false positive physiologic one of normal vaginal delivery which was differentiated from the ominous one by the periodic fetal respiratory movements synchronized with physiologic sinusoidal FHR in the ACG.

ized by elevated FHR baseline and preserved baseline variability (Fig. 5).

False Positive Physiological Sinusoidal FHR

True sinusoidal FHR appeared in severe fetal anemia in fetomaternal transfusion, hemolytic disease of Rh isoimmunization, Parvo B19 virus infection or severe hypoxia, where fetal or neonatal demise was frequent. Pulsed Doppler revealed high systolic velocity of fetal middle cerebral artery (MCA) in fetal anemia. Two to 6 cycles per minute sine wave like oscillation was continuously recorded in FHR baseline but no fetal movement burst appeared in the ACG, (Fig. 6A) and cured by intrauterine blood transfusion or emergency cesarean section followed by neonatal transfusion.

There is a physiological benign sinusoidal FHR in normal pregnancy followed by normal vaginal delivery and

normal neonate. A physiological false positive sinusoidal FHR was differentiated from true ominous one when periodic fetal respiratory movements which repeated as periodic increase and decrease of 1 Hz respiratory movement spikes synchronized to sinusoidal FHR were recorded on the ACG (Fig. 6B) [11]. The false-positive sinusoidal FHR was also diagnosed by the analysis of frequency power spectrum of FHR [14].

Sinus Bradycardia

Continuous FHR bradycardia appears in severe fetal hypoxia which should be differentiated from atrio-ventricular (A-V) block and sinus bradycardia. The A-V block is diagnosed using ultrasonic M-mode, while sinus bradycardia was diagnosed with the ACG, and FHR curve rose against fetal movement bursts in the fetal sinus bradycardia, i.e. the FHR was reactive to fetal movements in the ACG [15].

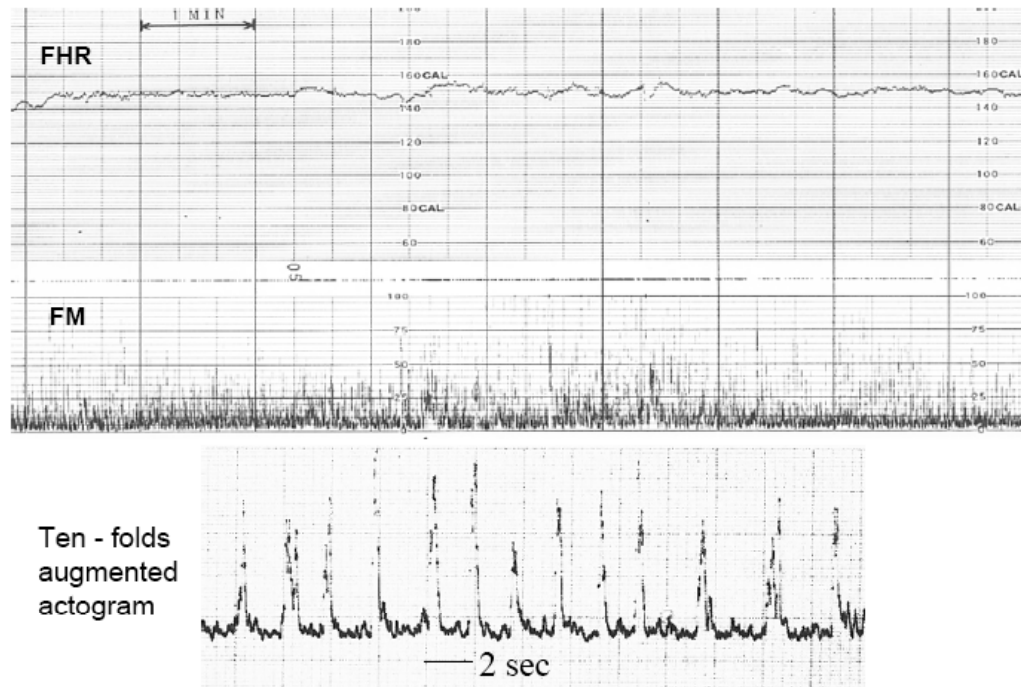


Fig. (7). Fetal hiccupping movements of which interval was 2 seconds, i.e. the frequency was 0.5 Hz. No FHR acceleration was found in spite of no hypoxia. The hiccupping duration was 20 minutes or more and repeated twice in a day-time. It was normal physiological phenomenon because of normal outcome.

Table 2. Ranking of CNS Lesions by the Fetal Behavior vs. A/B Ratio

Fetal CNS Lesions	#Fetal Functions [16]					Ranking	
	1	2	3	4	5	By Fetal Functions	By A/B Ratios
Excencephaly	+	-	-	-	-	1	1(0)
Pena Shokeir	+	+	-	-	-	2	2(0.41)
Dandy-Walker	+	+	+	-	-	3	3(0.78)
IVH	+	+	+	+	+	4	4(0.99)
Lissencephaly	+	+	+	+	-	4	5(1.9)
+: present, -: absent							(): A/B ratio
# The fetus was evaluated by 5 fetal functions in B-mode studies [16, Morokuma]							
1. The movement of fetal extremities							
2. Fetal Breathing movement							
3. Alteration of EM and NEM periods							
4. REM and SEM patterns							
5. The concurrence of regular mouthing movement with the NEM period							

Fetal disorders were evaluated by the A/B ratios of ACG [7] of which ranking was the same as that of fetal function in this table

Fetal Hiccupping Movement

Fetal hiccupping movements may be perceived as fetal movement by some pregnant women in the NST. Since the hiccupping produces no FHR acceleration, there may be false positive non-reactive FHR in common CTG, which will be followed by non-reassuring fetal status. The fetal hiccups are differentiated from actual fetal movements on the basis of ACG recording of continuous spikes with usually 2 seconds' intervals (Fig. 7).

Ranking of Fetal CNS Lesion Severity with the A/B Ratio of ACG

As the rank of A/B ratio of ACG coincided with the ranking determined using the fetal behavioral signs detected by real time B-mode studies by Morokuma [16] in 5 patients with fetal CNS lesions (Table 2), and thus the severity of 12 patients with fetal CNS lesion were reasonably determined using ACG [6].

Table 3. A/B ratios of ACG, Apgar Scores and Numerized Long Term Outcome in 20 Patients

Fetal Disorders	Weeks of	A/B	Apgar Score		Long Term
	Pregnancy	Ratio	1 min	5 min	Outcome#
loss of variability, NRFS	35	0	0	0	0
18-trisomy	29	0.15	0	0	0
PIH, FGR, LD	35	0.34	3	9	8
hydrops foetalis	26	0.42	0	0	0
osteodysplasia	29	0.5	1	4	1
excencephaly, multiple anomalies	37	0.54	1	3	3
intestinal obstruction	36	0.96	2	4	6
polydactyly	37	1.01	8	9	9
sick sinus bradycardia	39	1.34	7	9	8
endocardiac cushion defect	37	1.2	9	9	8
megacystis	38	1.22	8	9	8
myotonic dystrophy	32	1.26	9	9	6
hydronephrosis	39	1.31	9	9	9
normal pregnancy	37	1.43	8	9	10
hydrocephaly	33	1.16	8	9	7
hydrocephaly	30	0.73	3	4	4
spina bifida, ventriculomegaly	41	0.88	4	8	6
spina bifida, part. corp. call. defect	38	1.11	8	8	8
interrupted ascend. aorta, type A	40	1.34	9	9	8
placenta abruption	38	1.32	9	9	9

see Table 4

Estimation of Short and Long Term Outcome Using the A/B Ratio in Fetal Disorders

Because 1 and 5 min Apgar scores and numerized long term outcome were closely correlated with A/B ratios of ACG in 20 patients with other fetal disorders, fetal outcome was estimated using the ACG, i.e. the outcome was disturbed in various grades along with the A/B ratio less than 1.0 (Tables 3 and 4, Figs. 8 and 9) [7].

Table 4. Numerized Long Term Fetal Outcome

Long Term Status	Numeric Outcome
Intrauterine death	0
Death in day 1	1
Death within 1 week	2
Death within 1 year	3
Death within 5 years	4
Spastic quadriplegia	5
Growth retardation	6
Mental retardation	7
Well and change hospital	8
Well with mild sickness	9
Healthy	10

Anencephalic Fetal Movements

Anencephalic fetus loses most of the brain and is left with the cerebellum and brain stem. Our results show that the FHR baseline is totally flat by the loss of acceleration and the loss of baseline variability, possibly due to the defect of major brain (Fig. 10). Anencephalic neonate was unable to breathe because the loss of respiratory center, thus neonatal hypoxic bradycardia appeared possibly because of excitation in the parasympathetic center located in the medulla oblongata [17]. Severe brain loss might have caused loss of the cortical control of peripheral motion centers, which would have been excited because of the absence of brain control. Thus, fetal movements of the anencephalic fetus were vigorous, i.e. the duration of fetal movement bursts was 90 s, which was longer than the mean burst duration values of normal active state and hyperactive state (Table 1). The tracing of succeeding 2 movement bursts consisted of similar 3 parts of long, medium, and short duration of spikes that supposedly showed gradual reduction in the excitation of independent motion centers from the control of the brain (Fig. 11).

Cross Correlation of FHR and Movement Signals

The fetal movement bursts synchronized with FHR acceleration in the active fetal states, and the cross correlation coefficient of digitized FHR and movement signals was

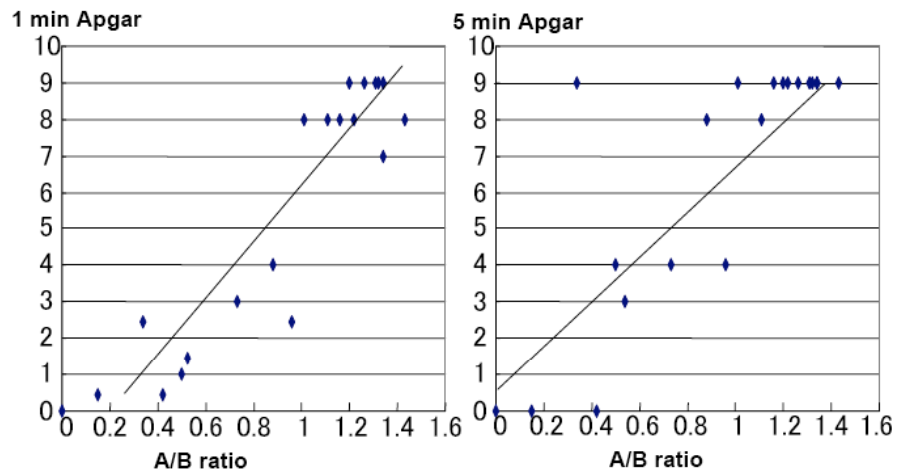


Fig. (8). Correlation of A/B ratio and 1 and 5 min Apgar score
 $X=A/B$ ratio, $Y=Apgar$ score
 1 min: $Y=7.68X-1.76$, $R^2=0.85$, $p<0.001$
 5 min: $Y=6.44X+0.68$, $R^2=0.68$, $p<0.001$
 There would be no neonatal depression, if the A/B ratio was larger than 1.

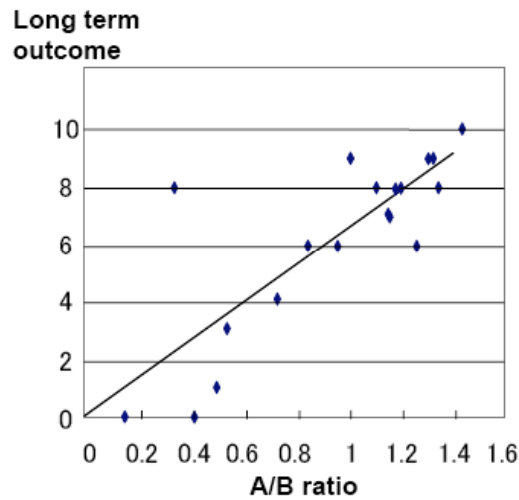


Fig. (9). Correlation of A/B ratio and numeric long term outcome (Table 4).
 $X=A/B$ ratio and $Y=$ numeric long term outcome.
 $Y=6.42X+0.05$, $R^2=0.71$, $p<0.001$.
 The outcome would be well, if the A/B ratio was more than 1.

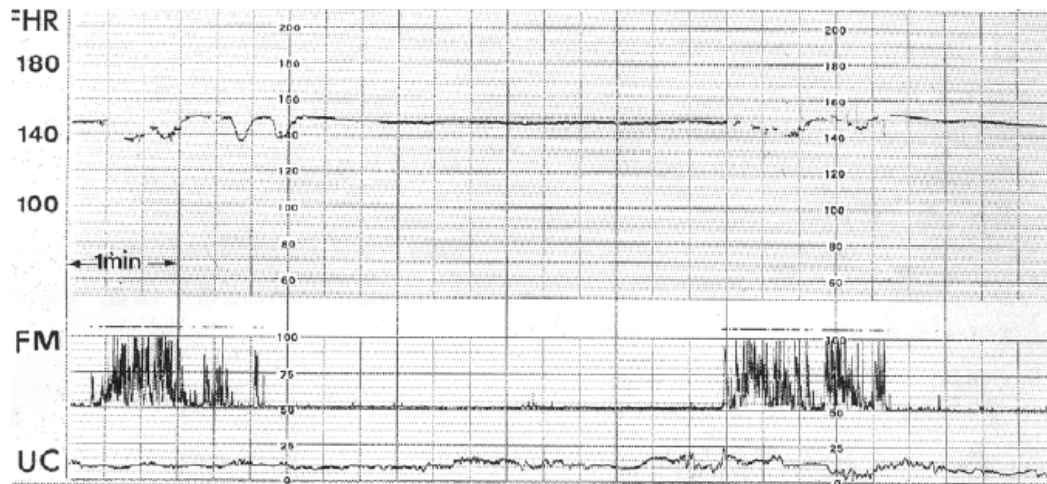


Fig. (10). Anencephalic fetal ACG. The FHR shows flat baseline without variability and no acceleration against fetal movement bursts.

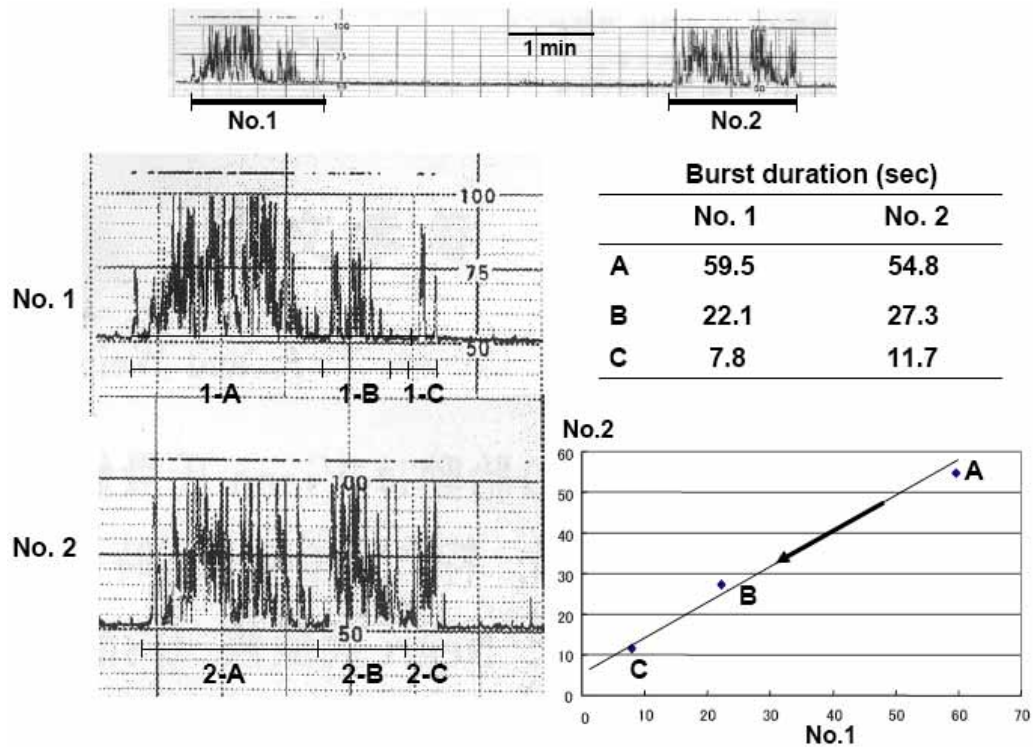


Fig. (11). Succeeding two movement bursts were constructed of similar 3 parts which gradually attenuated in anencephalic fetal ACG. The change of bursts may be due to the action of independent motion center without central nervous control.

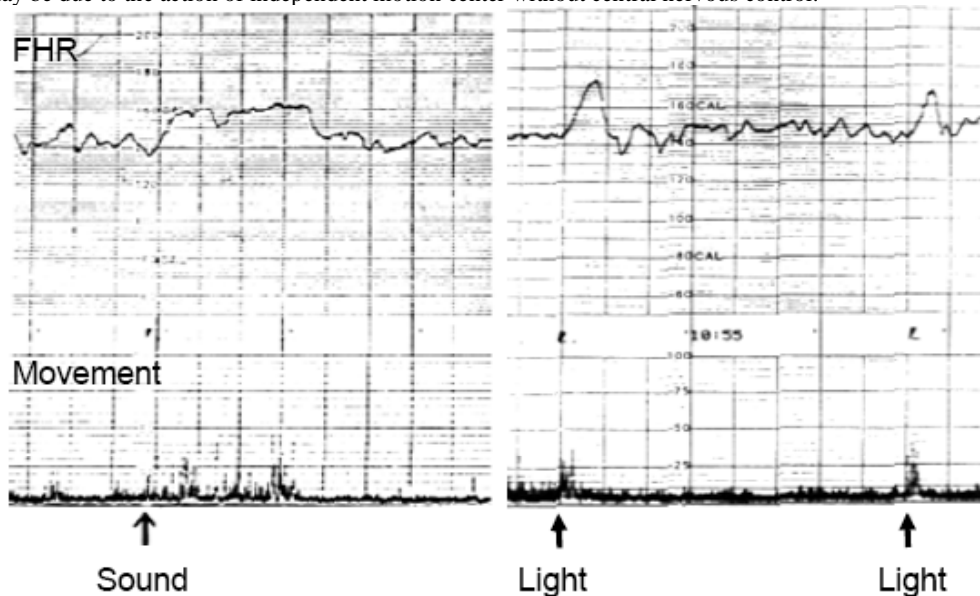


Fig. (12). Fetal responses to the sound and light were fetal movement and FHR acceleration in the late stage of pregnancy. Sound: Sine wave, 1 kHz, 80 dB, 2 second. Light: Photographic speed light, guide number 20 ISO 100.

largest when the movement signal was delayed for 7 seconds in late pregnancy. Thus, fetal movement was considered to precede FHR change. The delay time was longer in early pregnancy than in late stage [10].

Fetal Response to Acoustic and Visual Stimulation

Acoustic stimulation: The 250, 500 and 1,000 Hz sine waves oscillated in the signal generator were input in an amplifier and its output sound was radiated for 2 sec by the loud speaker on the abdomen of normal pregnant women in 28

and 40 weeks of gestation. The sound intensity was set at 80 and 60 dB which was determined at 1 meter apart from the speaker using an audiometer. Fetal response to the sound was fetal movement followed by the FHR acceleration in the ACG charts (Fig. 12). The fetuses responded to the 80 dB sound in 28 gestational weeks and 60 dB in 40 weeks.

The reduction of sound intensity was significant at 1,000 Hz, while insignificant at 250 and 500 Hz sound [9]. Fetal acoustic sensitivity would be higher at 40 weeks of gestation than at 28 weeks.

Visual stimulation: The photographic speed light penetrated a 3 cm thick meat slice. The light was flashed above the abdomen of normal pregnant women at 18 to 41 gestational weeks. Fetal response to the light was fetal movement followed by FHR acceleration in the ACG (Fig. 12). No response was observed at or before 21 weeks, and a 30 % positive response was observed at 22 weeks, subsequently the ratio increased along the progress of pregnancy, and 70 % positive response was observed at 40 to 41 weeks [9]. Fetal visual sensitivity would increase in the late stage of pregnancy.

DISCUSSION

Fetal movements are very interesting in various subjects; nature of movement itself; the possible control of lower motion center by the CNS; relation of fetal trunk and extremity movements; fetal respiratory movements (regularly continuous, periodic one associated with physiologic sinusoidal FHR, nasal or tracheal amniotic fluid flow [18]; appearance of movements in early pregnancy; fetal movements in pathological situations (aneuploidy, fetal CNS lesion, anencephaly, hypoxia, cerebral palsy, periventricular leukomalacia (PVL)); expression of fetal face (eye, REM, NREM, blink, mouth, tongue, swallow, yawn, grimace, smile, cry), movements of hands, fingers, legs, stomach, intestine and bladder; movement detection strategy (maternal perception, superficial, indirect, direct, ultrasound (real time B-mode, 4D, Doppler), RMI, fetal response to external stimuli (vibration, sound and light). Fetal movements constitute a major part of fetal life.

The ACG shows fetal trunk movements, while the fetal trunk will move simultaneously with fetal head and extremity, therefore, the ACG may conclusively express entire fetal movements, i.e. the direct recording of the movement of the fetal trunk, and indirect recording of the movement of the head and extremities. The events of rapid motion of the extremities were marked using high-speed Morse code transmission key of the telegram instead of slow press switch in the real-time B-mode study of fetal motion simultaneously with the ACG recorded on high speed chart, where spikes of ACG movement signals were fully synchronized with the event markers [1].

The reduction of A/B ratio in ACG shows the reduction of FHR acceleration standardized by the fetal movements, and therefore possibly indicating the grade of brain damage in the lesions of CNS, i.e. the acceleration develops in the relation of fetal brain activity which was minimal in anencephalic fetus who shows no acceleration and baseline variability possibly because of the loss of brain cortex including the function to develop FHR acceleration and variability [19]. The extreme reduction in A/B ratio was the non-reactive FHR, which did not accompany FHR acceleration against active fetal movement bursts, while FHR baseline variability was preserved, where frequently hypoxic FHR changes including loss of variability, late decelerations or bradycardia appeared during continuous monitoring usually within a few days after the confirmation of non-reactive FHR with the ACG, where the outcome was unfavorable despite of an emergency cesarean section [20].

Fetal sensory function was excellent in the late stage of pregnancy because lowering of the threshold, i.e. 1,000 Hz sound intensity was 80 dB to evoke fetal movement and FHR acceleration in 28 gestational weeks, while fetal response required only 60 dB sound in 40 weeks [9], which indicated that the fetus was capable to listen to weak sound in the late stage of pregnancy.

Fetal visual function started in 22 weeks of pregnancy when the retina developed in the fetal eye, and the positive response rate to fixed source of visual stimulation increased from 30 % in the early stage to 70 % at 40 weeks of pregnancy [7].

CONCLUSION

The author and colleagues created and studied the ACG. They could quantify fetal Movement, easily classify fetal behavioral states, differentiate false and truly positive FHR, including physiologic sinusoidal heart rate, outcome estimation in fetal CNS lesion and in other disorders, development of FHR acceleration induced by the movement burst, high fetal hearing and visual functions in late stage of pregnancy revealed by fetal responses to quantified audio-visual stimulations, and they studied the characteristic relation between fetal heart rate and fetal movement in their cross correlation study. Fetal outcome can be further improved by the application of the ACG results reported in our study.

CONFLICT OF INTEREST

The author declares no conflict of interest.

ACKNOWLEDGEMENT

None declared.

REFERENCES

- [1] Ota M. Evaluation of fetal movements with ultrasonic Doppler fetal actograph. *Nihon Sanka Fujinka Gakkai Zasshi* 1985; 37: 73-82.
- [2] Wheeler T, Roberts K, Peters J, Murrills A. Detection of fetal movement using Doppler ultrasound. *Obstet Gynecol* 1987; 70: 251-4.
- [3] Maeda K. Studies on new ultrasonic doppler fetal actograph, and continuous recording of fetal movement. *Nihon Sanka Fujinka Gakkai Zasshi* 1984; 36: 280-8.
- [4] Maeda K. Computerized analysis of cardiocograms and fetal movements. *Baillieres Clin Obstet Gynaecol* 1990; 4: 797-813.
- [5] Maeda K. Quantitative studies on fetal actocardiogram. *Croat Med J* 2005; 46: 769-6.
- [6] Maeda K, Morokuma S, Yoshida S, Ito T, Pooh RK, Serizawa M. Fetal behavior analyzed by ultrasonic actocardiogram in fetal central nervous system lesions. *J Perinat Med* 2006; 34: 398-403.
- [7] Maeda K, Iwabe T, Yoshida S, *et al*. Detailed multigrade evaluation of fetal disorders with the quantified actocardiogram. *J Perinat Med* 2009; 37: 392-6.
- [8] Takahashi H, Sekijima A, Kozasa A, Ito T, Maeda K. An anencephalic fetus who showed abnormal movements on actocardiogram. *Chugoku-Shikoku Godo Chiho-Bukai Zasshi* 1989; 37: 295-8.
- [9] Tatsumura M, Maeda K, Ito T, *et al*. Studies on features of fetal movement and development of human fetus with use of fetal actogram. *Nihon Sanka Fujinka Gakkai Zasshi* 1991; 43: 864-73.
- [10] Takahashi H. Studies on cross correlation coefficient of fetal heart rate and fetal movement signals detected by ultrasonic Doppler fetal actocardiograph. *Nihon Sanka Fujinka Gakkai Zasshi* 1990; 42: 443-9.
- [11] Ito T, Maeda K, Takahashi H, Nagata N, Nakajima K, Terakawa N. Differentiation between physiologic and pathologic sinusoidal FHR pattern by fetal actocardiogram. *J Perinat Med* 1994; 22: 39-48.

- [12] Nijhuis JG. Fetal behavioral states. In: Chervenak FA, Isacson CC, Campbell S, Eds. *Ultrasound in obstetrics and gynecology*. Boston, MA: Little and Brown 1993; vol 1: pp. 447-55.
- [13] Maeda K. Fetal monitoring and actocardiogram in the evaluation of fetal behavior. *Ultrasound Rev Obstet Gynecol* 2004; 4: 12-25.
- [14] Maeda K, Nagasawa T. Automatic computerized diagnosis of fetal sinusoidal heart rate. *Fetal Diagn Ther* 2005; 20: 328-34.
- [15] Minagawa Y, Akaiwa A, Hidaka T, *et al*. Severe fetal supraventricular bradyarrhythmia without fetal hypoxia. *Obstet Gynecol* 1987; 70: 454-6.
- [16] Morokuma S, Fukushima K, Yumoto Y, *et al*. Simplified ultrasound screening for fetal brain function based on behavioral pattern. *Early Hum Dev* 2007; 83: 177-81.
- [17] Maeda K, Kimura S, Fukui Y, *et al*. Studies on fetal pathophysiology. *Nihon Sanka Fujinka Gakkai Zasshi* 1969; 21: 877-86.
- [18] Utsu M, Sakakibara S, Ishida T, Chiba T. Dynamics of tracheal fluid flow in the human fetus, studied with pulsed Doppler ultrasound. *Acta Obstet Gynaecol Jpn* 1983; 35: 2017.
- [19] Takahashi H, Sekijima A, Kozasa A, Ito T, Maeda K. An anencephalic fetus who showed abnormal movements on actocardiogram. *Chugoku-Shikoku Godo Chiho-Bukai Zasshi* 1989; 37: 295-8.
- [20] Teshima N. Non-reactive pattern diagnosed by ultrasonic Doppler fetal actocardiogram and outcome of the fetuses with non-reactive pattern. *Nihon Sanka Fujinka Gakkai Zasshi* 1993; 45: 423-30.

Received: January 01, 2012

Revised: March 26, 2012

Accepted: April 16, 2012

© Kazuo Maeda; Licensee *Bentham Open*.

This is an open access article licensed under the terms of the Creative Commons Attribution Non-Commercial License (<http://creativecommons.org/licenses/by-nc/3.0/>) which permits unrestricted, non-commercial use, distribution and reproduction in any medium, provided the work is properly cited.