

# Efficacy of Piezo-Electric Surgery for Optic Canal Unroofing: Our Experience with Two Cases

M.E. Sham<sup>\*1</sup> and Sai Kiran<sup>2</sup>

<sup>1</sup>*Cranio-maxillofacial Surgeon, NO, 37, 1<sup>st</sup> Cross, Silver Oak Street, JP Nagar, Bangalore, Karnataka, India*

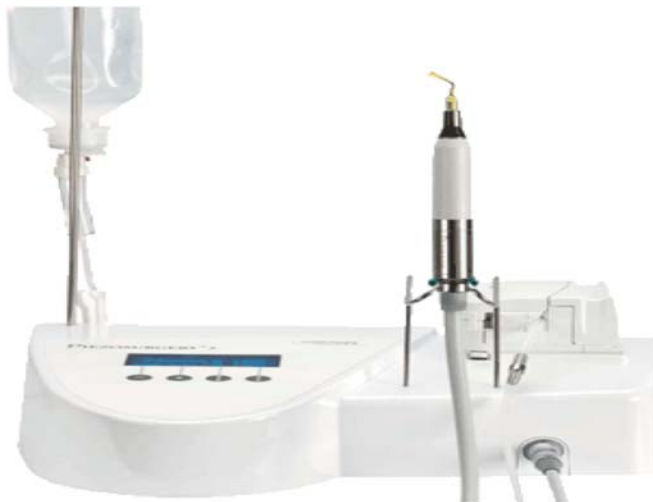<sup>2</sup>*Neurosurgeon, Department of Neurosurgery, Sri Satya Sai Institute of Higher Medical Sciences, Whitefield, Bangalore, Karnataka, India*

**Abstract:** Ultrasonic vibrations have been used to cut tissues for two decades. However, it is only in the last five years that experimental applications have been used routinely for standard clinical applications in many different fields of surgery. Surgically decompressing optic nerve, with the use of conventional drills is associated with greater risk of damage to the optic nerve itself. Developing new & precession bound safer techniques would certainly be beneficial to accomplish this task. Ultrasonic piezo bone surgery is a highly sophisticated device designed specifically for high end precession osseous surgery. In this article we describe our experience in using this device for extradural unroofing of the optic canal.

**Keywords:** Parasellar tumor, optic canal unroofing, Ultrasonic bone surgery.

## INTRODUCTION

Unroofing of the optic canal and subsequent mobilization of the optic nerve are useful techniques in the surgical treatment of parasellar tumors. There are many studies in literature advocating extradural unroofing of the optic canal for early decompression of the optic nerve [1-5]. Conventional use of drills in deroofing has its own risks of injuring the optic nerve either by iatrogenic compression or by the heat produced during drilling. This procedure must be done involving great degree of expertise. Development of Ultrasonic piezosurgery device (Fig. 1) comes in response to high end precession surgery involving osseous tissues [6-9].



**Fig. (1).** Piezo surgery unit.

Literature study in a small series has indicated use of this device for anterior clinoidectomy and opening of the internal auditory canal [10]. The piezosurgical device has proved itself to be a useful tool for selective opening of the posterior wall of the Internal auditory canal with preservation of cranial nerves in acoustic neuroma surgery. It has showed no major disadvantages or negative influence on neuromonitoring, hearing and facial nerve preservation rates. The authors in this study have concluded that piezosurgery has the potential to replace rotating burs for this indication due to its safe and precise bone drilling properties [11]. Operations on the neurocranium have high probability of injuring the dura. Schaller *et al.* [12] reported the successful use of piezoelectric surgery in the cranial base and spine in children. Five children between the age of 6 and 84 months were operated on for craniosynostosis, tethered cord, and an extraconal intraorbital tumor. The usefulness of piezoelectric bone surgery during neurosurgical procedures is presented for these cases. This technique is especially recommended when there are anatomic difficulties because of poor intraoperative visibility or the presence of delicate anatomic structures. He showed that the technique spared nerve tissue & other vital structures, improved the visualization of the surgical field which resulted in precise & micrometric cuts. Working principal of piezosurgery is ultrasonic vibrations of different of natural frequencies, specifically designed to affecting the hard tissues such as bone [6] sparing the soft-tissue [13, 14]. It was developed by an Italian oral surgeon Tomaso vercelotti in 1988 to overcome the limits of traditional instrumentation in bone surgery by modifying & improving conventional ultrasound technology [15]. The piezosurgery hand piece does not contain any rotating parts or drill attachments; thereby eliminating the risk of damage to surrounding important structures, making this device optimally precise & extremely reliable to be used in resecting bone in skull base surgeries [12]. For two decades ultrasonic vibrations have been used to cut tissue [1, 16, 17]. However, it is only in the last five - six years that experimental applications have been

\*Address correspondence to this author at the Department of Cranio Maxillofacial Surgery, Vydehi Institute of Medical and Dental Sciences. Bangalore, India; Tel: 09886232626; Fax: 08026491414; E-mail: ehtaihsham@yahoo.com

used routinely for standard clinical applications in many different fields of surgery [18-20]. Clinical use of piezo-surgery have considerably decreased the risk of damage to surrounding soft tissues and critical structures (nerves, vessels, and mucosa), particularly during osteotomy [3, 4, 10, 21-24]. The instruments used for ultrasonic cutting of bone create micro-vibrations that are caused by the piezoelectric effect first described by the French physicists Jean and Marie Curie, in 1880. The passage of an electric current across certain ceramics and crystals modifies them and causes oscillations. Voltage applied to a polarized piezoceramic causes it to expand in the direction of and contract perpendicular to polarity. A frequency of 25–29 kHz is used because the micro movements that are created at this frequency (ranging between 60 to 210  $\mu$ m) cut only mineralized tissue; neurovascular tissue and other soft tissue is cut at frequencies higher than 50 kHz [25-28]. Piezoelectric device usually consists of a hand-piece, its associated tips (Fig. 2) and a foot switch that are connected to the main power unit or console. This has a holder for the hand piece, and contains irrigation fluids that create an adjustable jet of 0–60 ml/minute through a peristaltic pump. It removes debris from the cutting area and ensures precise cutting. It also maintains a blood-free operating area because of cavitation of the irrigation solution, and gives greater visibility particularly in complex anatomical areas [5, 6]. Piezoelectric techniques were developed in response to the need for greater precision and safety in bone surgery than was unavailable with other manual and motorized instruments [18]. In this article, we describe our experience in using this device for optic canal unroofing. In our view this device is extremely precise, safer & its ease of handling makes it more reliable to be used in complex skull base surgeries.




Fig. (2). Available piezo tips.

## CLINICAL MATERIALS AND METHODS

### Patient Population

Two patients with parasellar tumors (meningioma) underwent surgery in which the ultrasonic piezo-surgery was used.

### Device Description

Ultrasonic piezo-surgery (mectron, Italy).

### Surgical Description

Several approaches to optic nerve decompression exist. In our series, a limited bone flap was created through fronto-

temporal craniotomy (Fig. 3). Following which a limited Orbital osteotomy is done, extending medially to supraorbital foramen & laterally to frontozygomatic suture. Resection of the sphenoid ridge is done to identify the lateral limit of the superior orbital fissure; this procedure is done with the piezosurgery device using titanium tips (OT6, OT5A, and OP1). After dissection and decompression of the superior orbital fissure, optic canal orifice is approached. After identifying the proximal orifice of the optic canal extradurally, bone resection using piezosurgery is initiated from the proximal surface of the canal roof by placing the tip (OP1, OT5A) of the ultrasonic bone surgery on the canal roof (Fig. 4) and applying the ultrasonic energy in moderate power to protect the tip from excess heat. Resection pattern is proximal-to-distal. The ultrasonic tip gets heated if used in high-power mode in spite of vigorous saline irrigation; thus the tips are used in moderate power in a sweeping motion. Using ultrasonic energy, the bone over optic canal could be thinned as much as required while the remnant strut could be easily fractured & removed by carefully dissecting it from the surrounding dura. Brisk bleeding is controlled by applying haemostatic material. The dura is then opened, and the tumor approached for further excision.

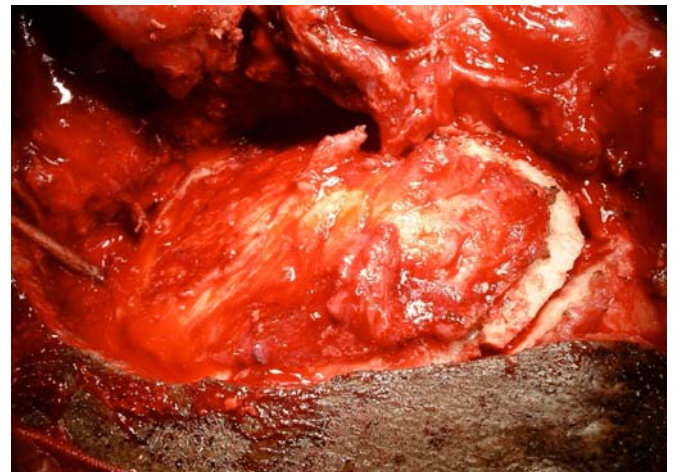


Fig. (3). Fronto-Temporal craniotomy.

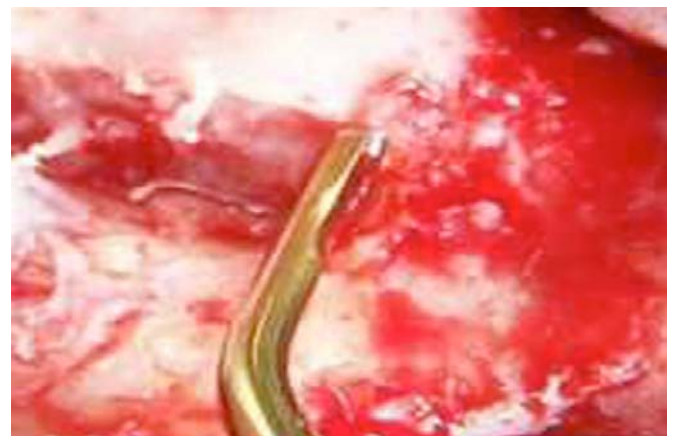
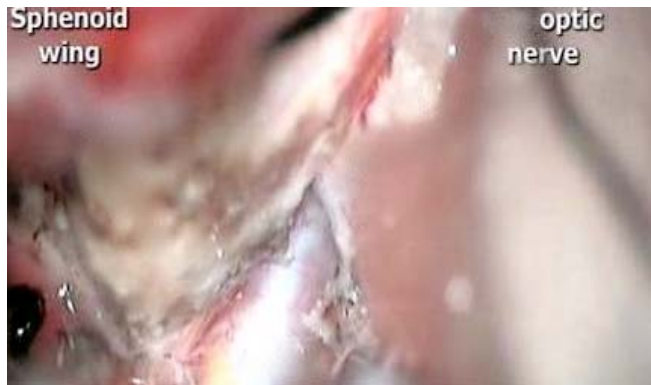
Fig. (4). Microscopic view.

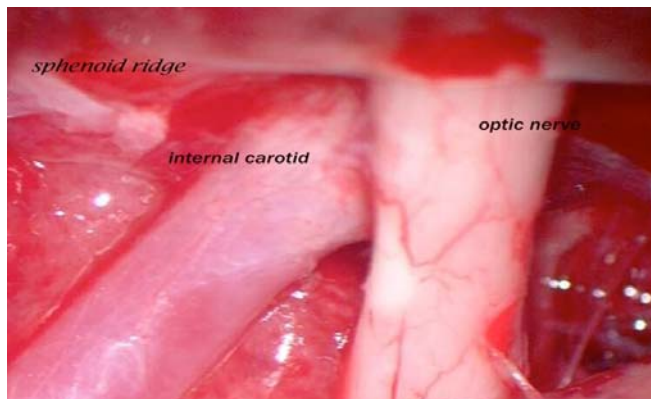
## RESULTS

Ultrasonic bone surgery device was used in two patients who underwent surgery for excision of parasellar tumors

(meningioma) with optic nerve decompression. Overall, the optic canal unroofing procedure was safely conducted without causing damage to vision. In both the cases, the optic sheath and the frontal dura were completely preserved. (Figs. 5 and 6) There was no postoperative cerebrospinal fluid leak.



**Fig. (5).** Microscopic view.



**Fig. (6).** Microscopic view.

## DISCUSSION

Osteotomy techniques consist in performing cutting actions (osteotomy) or remodeling (osteoplastic procedures) of the bone surface. All bone surgery interventions, in different specialties, originate from a combination of these two techniques. However, surgical instruments available to perform these techniques are numerous. Two basic types of instruments exist:

1. Manual instruments (scalpels, hammers, saws, etc...), characterized by considerable cutting efficacy, related to the mechanical force exerted in an instantaneous fashion, therefore, not easily controllable;
2. Motor-driven instruments, characterized by a cutting capacity produced by electric or pneumatic energy. Micro motors used in bone surgery transform the electric energy into mechanical energy; the cutting is, therefore, the result of rotation produced by the movement of the drill or by the oscillating movement of the bone saw.

Traditional motorized instruments, in producing the cutting action, generate macro vibrations that, in turn, reduce the surgical safety.

Unroofing the optic canal is a useful technique in surgical management of parasellar tumors, [1, 2, 5, 17, 26]. In parasellar tumors the optic nerve is already compressed by the tumor mass and is further vulnerable to mechanical pressure or stretching. Tumor excision/debulking without decompression can have deleterious effect on optic nerve function. Literature review shows some proportion of patients have suffered postoperative worsening of visual symptoms even when the procedure have been conducted by best of best hands [14, 21-25, 28].

Unlike traditional cutting instruments, piezosurgery offers the possibility of a cut with the following characteristics:

- *Micrometric*, inasmuch as the insert vibrates with a Range of 60-200  $\mu\text{m}$  at a modulated US frequency, which, whilst cutting, maintains the bone constantly clean, thus avoiding excessive temperatures;
- *Selective*, inasmuch as the vibration frequency is optimal for the mineralized tissues (in fact, to cut the soft tissues, different frequencies are required);
- *Safe*, inasmuch as the reduced range of the micrometric vibrations offers the possibility to perform surgery with very great precision. The cut, in fact, can be controlled easily as if drawing an outline. This enables osteotomy to be performed even in close proximity to delicate structures, such as vasculo-nervous structures, in general, without damaging them. Surgical control with piezosurgery is maximum as the strength required by the surgeon to affect a cut is far less compared to that with a drill or with oscillating saws.

In fact, burrs controlled by a micromotor require greater strength, against the rotating couple of the instrument, obtained by applying increased pressure of the hand. As a result, surgical sensitivity is reduced, especially when there are structures presenting different mineralization or even more complex soft tissues, where one runs the risk of losing control of the latter on the drill's stem. Using piezo bone surgery, we were able to unroof the optic canal without damaging the optic sheath or frontal dura, not to mention the optic nerve itself. Our technique definitely requires less expertise than that involved in the drilling technique

Ultrasonic bone surgery has another technical advantage, during the unroofing procedure; we were always able to identify the edge of the bone more so because of the cavitatory effect of ultrasonic bone surgery, [29]. The 'hammering effect' produced by the wave modulation on the insert tip hits the irrigation solution; the latter is converted in a fine spray. The sprayed molecules of the irrigation fluid hit the cutting site, cool it down and produce a temporary haemostatic effect, allowing for maximum visibility during surgery. Lastly, one of the greatest advantages of Piezosurgery is the fact it is gentler to the tissues and, in fact, induces faster healing. Histological and biomolecular studies have shown that compared to traditional techniques, the use of Piezosurgery is not only characterized by minimal postoperative bone loss but actually promotes faster healing [29, 30]. In the drilling technique, a thin layer of bone is usually left over the canal, and this shell is later removed with a curette or a micro-dissector thus, the exact location of the canal is not known during drilling, which can cause one to drill a larger area than is necessary. Therefore, because the device allows

one to avoid unnecessary bone resection around the canal, the ultrasonic bone surgery is less prone to creating an inadvertent opening into the nasal sinuses [29]. In our opinion, this incredible feature makes Piezosurgery the preferable tool in precession guided surgery.

Despite its many advantages, the ultrasonic bone surgery also has certain disadvantages. First, the hand piece is somewhat bulky, not specifically designed for neurosurgery and hinders visibility in a deep and narrow operative field. Second, because the tip is relatively smaller than larger regular drill bits, resection of a large amount of bone is time consuming. Third, any excess pressure on the tip would lead to its breakage & finally the equipment itself is expensive. We strongly advocate a collaborative use of drills & piezosurgery. In cases where excess bone debulking is necessary, an initial drill based rough bone resection followed by finer resection with an ultrasonic bone surgery would be advisable. Finally, we would like to emphasize that use of this device does not automatically protect the soft tissues if care is not taken.

## CONCLUSION

In comparison to high-speed drills & other conventional techniques, ultrasonic bone surgery can be extremely safe, technically precise & less demanding in expertise. In our experience use of ultrasonic vibrations for optic canal unroofing would certainly bring benefits by decreasing morbidity in patients who are candidates for early nerve decompression. Also to mention is the need for further technological advancement of this device & refinement in its design particularly with improvements in power and geometry of the inserts, with possible applications also specifically to cater neurosurgical needs.

## REFERENCES

- [1] Akabane A, Saito K, Suzuki Y, Shibuya M, Sugita K. Monitoring visual evoked potentials during retraction of the canine optic nerve: protective effect of unroofing the optic canal. *J Neurosurg* 1995; 82: 284-7.
- [2] Al-Mefty O. Meningiomas of the anterior cranial base, in *Operative Atlas of Meningiomas*. Philadelphia: Lippincott-Raven, 1998; pp. 1-66.
- [3] Dolenc VV. Elements of the epidural approach to the parasellar space and adjacent regions in the central skull base, in *Microsurgical Anatomy and Surgery of the Central Skull Base*. Wien: Springer-Verlag, 2003; pp. 51-72.
- [4] Lee JH, Jeun SS, Evans J, Kosmorsky G. Surgical management of clinoidal meningiomas. *Neurosurgery* 2001; 48: 1012-21.
- [5] Yonekawa Y, Ogata N, Imhof HG, *et al*. Selective extradural anterior clinoidectomy for supra- and parasellar processes. Technical note. *J Neurosurg* 1997; 87: 636-42.
- [6] Sherman JA, Davies HT. Ultracision: the harmonic scalpel and its possible uses in maxillofacial surgery. *Br J Oral Maxillofac Surg* 2000; 38: 530-2.
- [7] Horton JE, Tarpley TM Jr., Jacoway JR. Clinical applications of ultrasonic instrumentation in the surgical removal of bone. *Oral Surg Oral Med Oral Pathol* 1981; 51: 236-42.
- [8] Vercellotti T. Technological characteristics and clinical indications of piezoelectric bone surgery. *Minerva Stomatol* 2004; 53: 207-14.
- [9] Eggers G, Klein J, Blank J, Hassfeld S. Piezosurgery: an ultrasound device for cutting bone and its use and limitations in maxillofacial surgery. *Br J Oral Maxillofac Surg* 2004; 42: 451-3.
- [10] Hadeishi H, Suzuki A, Yasui N, Satou Y. Anterior clinoidectomy and opening of the internal auditory canal using an ultrasonic bone curette. *Neurosurgery* 2003; 52: 867-71.
- [11] Kaminsky J, Grauvogel J. Use of Piezosurgery for Internal Auditory Canal (IAC) opening in acoustic neuroma surgery. 61st Annual Meeting of the German Society of Neurosurgery (DGNC) as part of the Neurowoche 2010 Joint Meeting with the Brazilian Society of Neurosurgery on the 20 September 2010.
- [12] Schaller BJ, Gruber R, Merten HA, *et al*. Piezoelectric bone surgery: a revolutionary technique for minimally invasive surgery in cranial base and spinal surgery? Technical note. *Neurosurgery* 2005; 57: E410.
- [13] Gleizal A, Bera JC, Lavandier B, Beziat JL. Piezoelectric osteotomy: a new technique for bone surgery—advantages in craniofacial surgery. *Childs Nerv Syst* 2007; 23: 509-13.
- [14] Kramer FJ, Ludwig HC, Materna T, Gruber R, Merten HA, Schliephake H. Piezoelectric osteotomies in craniofacial procedures: a series of 15 pediatric patients. Technical note. *J Neurosurg* 2006; 104: 68-71.
- [15] Pavlíková G, Foltán R, Horká M, Hanzelka T, Borunská H, Sedý J. Piezosurgery in oral & maxillofacial surgery. *Int J Oral Maxillofac Surg* 2011; 40: 451-7.
- [16] Al-Mefty O. Clinoidal meningiomas. *J Neurosurg* 2003; 73: 840-9.
- [17] Day JD, Giannotta SL, Fukushima T. Extradural temporopolar approach to lesions of the upper basilar artery and infrachiasmatic region. *J Neurosurg* 1994; 81: 230-5.
- [18] Horton JE, Tarpley TM, Wood LD. The healing of surgical defects in alveolar bone produced with ultrasonic instrumentation, chisel, and rotary bur. *Oral Surg Oral Med Oral Pathol* 1975; 39: 536-46.
- [19] Vercellotti T, Pollack AS. A new bone surgery device: sinus grafting and periodontal surgery. *Compend Contin Educ Dent* 2006; 27: 319-25.
- [20] Stubinger S, Kuttenger J, Filippi A, Sader R, Zeilhofer HF. Intraoral piezosurgery: preliminary results of a new technique. *J Oral Maxillofac Surg* 2005; 63: 1283-7.
- [21] DeMonte F. Surgical treatment of anterior basal meningiomas. *J Neurooncol* 1996; 29: 239-48.
- [22] Goel A, Muzumdar D, Desai KI. Tuberculum sellae meningioma: A report on management on the basis of a surgical experience with 70 patients. *Neurosurgery* 2002; 51: 1358-64.
- [23] Jallo GI, Benjamin V. Tuberculum sellae meningiomas: microsurgical anatomy and surgical technique. *Neurosurgery* 2002; 51: 1432-40.
- [24] Rosenstein J, Symon L. Surgical management of suprasellar meningioma. Part 2: prognosis for visual function following craniotomy. *J Neurosurg* 1984; 61: 641-8.
- [25] Samii M, Ammirati M. *Surgery of Skull Base Meningiomas*. Berlin: Springer-Verlag 1992; pp. 35-41.
- [26] Takahashi JA, Kawarazaki A, Hashimoto N. Intradural en-bloc removal of the anterior clinoid process. *Acta Neurochir(Wien)* 2004; 146: 505-9.
- [27] Tobias S, Kim CH, Kosmorsky G, Lee JH. Management of surgical clinoidal meningiomas. *Neurosurg Focus* 2003; 14(6): E5.
- [28] Yasargil MG. *Microneurosurgery, Vol IVB*. Stuttgart: Thieme, 1996, pp. 134-165.
- [29] Chang HS, Joko M, Song JS, Ito K, Inoue T, Nakagawa H. Ultrasonic bone curettage for optic canal unroofing and anterior clinoidectomy Technical note. *J Neurosurg* 2006; 104(4): 621.
- [30] Crossetti E, Battiston B, Succo G. Piezosurgery in head and neck oncological and reconstructive surgery: personal experience on 127 cases. *Acta Otorhinolaryngol Ital* 2009; 29(1): 1-9.

Received: June 20, 2011

Revised: July 16, 2011

Accepted: July 19, 2011

© Sham and Kiran *et al.*; Licensee Bentham Open.

This is an open access article licensed under the terms of the Creative Commons Attribution Non-Commercial License (<http://creativecommons.org/licenses/by-nc/3.0/>) which permits unrestricted, non-commercial use, distribution and reproduction in any medium, provided the work is properly cited.