

[18F]FDG-PET as a Biomarker for Early Alzheimer's Disease

Flavio Nobili^{*1} and Silvia Morbelli²

¹Clinical Neurophysiology Unit, Dept. of Neurosciences, Ophthalmology and Genetics, ²Nuclear Medicine Unit, Department of Internal Medicine, Azienda Ospedaliera-Universitaria S. Martino, Genova, Italy

Abstract: [¹⁸Fluorine]fluorodeoxyglucose-Positron Emission Tomography (¹⁸F FDG-PET) has gained a leading role in the diagnostic assessment of patients with cognitive complaints, notably Mild Cognitive Impairment (MCI) and Alzheimer's Disease (AD). Together with morphological Magnetic Resonance Imaging (MRI) and cerebrospinal fluid biomarker assays it allows early identification of subjects with neurodegeneration of the AD-type, which is crucial in view of effective disease-modifying drugs. [18F]FDG-PET identifies hypometabolic regions in posterior cingulate-precuneus, posterior lateral and medial temporal-parietal association cortex, and in lateral frontal cortex. Hypometabolism in posterior cingulate-precuneus may be found even in MCI patients not yet converted to AD after a reasonable follow-up time and thus it might be a marker of memory deficit rather than of AD conversion. As [18F]FDG-PET is sensitive to synaptic dysfunction and depletion, hypometabolic areas can be detected before atrophy is highlighted by MRI in the same regions. The interpretation of the pathophysiological meaning of hypometabolism is discussed also in view of the most recent theory on the brain 'default mode network'. In longitudinal 1-year studies, [18F]FDG-PET has been shown an adequate tool to detect metabolic deterioration in AD patients better than amyloid-PET. It has been proposed as a surrogate biomarker to evaluate the effect of disease-modifying drugs in AD with a five times higher power than the commonly used neuropsychological scales. A flow-chart on the clinical use of [18F]FDG-PET is proposed, in which it is strongly recommended in MCI patients with suspected neurodegeneration.

Keywords: Alzheimer disease, mild cognitive impairment, FDG-PET - biomarkers.

FDG-PET: BASIC PRINCIPLES

It is known that the brain mainly uses glucose for energy production. Glucose enters the neuron-astrocyte functional unit where it is phosphorylated by a hexokinase, which is the first pivotal step of that metabolic pathway. Active energy production takes place at the synaptic terminals *via* the tricarboxylic acid pathway, requiring oxygen and leading to high ATP availability (aerobic glycolysis). This pathway is very productive but cannot quickly face the need of energy during brain activation. On turn, astrocytes mainly utilize anaerobic glycolysis which provides much less energy but it is faster. The lactate end-product is transferred to neurons and is transformed to pyruvate for more economic energy production [1, 2]. Glucose metabolism has been shown to be closely coupled to neuronal function at rest and during functional activation [3].

Labeling glucose with [18Fluorine] allows quantitative (or semi-quantitative) measurement of the local metabolism of the synaptic terminals in their neuron-astrocyte functional unit, as the greater part of glucose utilization happens at the synaptic level. Reference grey matter cerebral metabolic rate for glucose (CMR_{glc}) values ranges from about 40 to 60 mmol glucose/100 g of brain tissue/ 1 min. at rest in a normal adult; in the white matter it is about 1/3 to 1/4 as compared to the grey matter. The highest values are found in the basal ganglia, the thalami and the occipital polar and

mesial cortex, while the medial temporal cortex and the cerebellum show the lowest values. In comparison with SPECT tracers, this figure closely resembles that obtained with ^{99m}Tc-ECD, less that obtained with ^{99m}Tc-HMPAO.

By performing [18F]FDG-PET at rest, glucose uptake distribution is mainly driven by basal neuronal activity and represents general neuronal integrity [4]. For a tissue unit, reduced glucose uptake essentially stands for either a reduction in number of synapses or a reduced synaptic metabolic activity. A research focus is currently the so called 'default mode network' (DMN) of functioning of the resting brain, involving areas of the medial frontal and temporal lobes, the posterior cingulate cortex, the precuneus and the surrounding medial and lateral parietal cortex. The DMN is a still debated entity but an attractive working hypothesis and would represent a network that is active during introspection and in the absence of an active task performance (see below its possible pathophysiological meaning in Alzheimer's disease).

FDG-PET acquisition should follow the guidelines of the various Nuclear Medicine Societies (such as the Society of Nuclear Medicine in the USA and the European Association of Nuclear Medicine) [5, 6]. According to these guidelines, the subject is fasting at least 6 hours, is awake in a silent and dimly lighted room, with the eyes closed, after the procedure has been fully explained and a vein cannula, connected with saline solution, has been placed. After at least 5 minutes, 185 MBq (3D acquisition) of [18F]FDG is injected. He/she must remain 20-30 min in the same quiet condition, as the injected glucose takes this time to be fully taken up by the brain cells. Then the subject is moved to the camera room where

*Address correspondence to this author at the Department of Neuroscience, Ophthalmology and Genetics, Azienda Ospedaliera-Universitaria S. Martino, Genoa, Italy; Tel: +39 010 3537568; Fax: +39 010 5556893; E-mail: flaviomariano.nobili@hsanmartino.it

imaging starts typically 30–60 min after tracer injection, with acquisition usually ranging from 10 to 15 minutes.

FDG-PET FINDINGS IN MILD COGNITIVE IMPAIRMENT (MCI) AND EARLY ALZHEIMER'S DISEASE (AD)

Since the first FDG-PET report in AD about 30 years ago, a huge number of papers has reported -finally established- the features and the value of FDG-PET. More recently, the diagnosis effort has moved to the early stages of AD, when dementia is not present yet (i.e., the subject maintains his/her autonomy in everyday occupations). This stage is known as Mild Cognitive Impairment (MCI) since its first categorization in 1999 [7]. Previously used other terminology generated confusion, such as 'Cognitive Impairment, not Demented (CIND)', 'isolated memory deficit', and others. However, not all the individuals with MCI will develop AD (or another type of dementia). MCI has been defined as a memory deficit reported by the subject and/or by the informant and confirmed by standardized neuropsychological tests (-1.5 standard deviations below the age-matched norms, corrected for education). Dementia is excluded by confirming that the everyday life autonomy is mainly preserved. To this original concept of 'amnestic' MCI (aMCI), other concepts were added in the following years, including deficit in cognitive domains other than memory ('non-amnestic MCI', or naMCI). Both aMCI and naMCI may refer to an isolated deficit (single-domain MCI, either aMCI or naMCI) or to multiple deficit (multi-domain, either aMCI or naMCI) [8]. Such a 'working formulation' has the clear advantage to share a common language among clinicians and researchers throughout the world, but has the intrinsic limitation to give a phenomenonic rather than an etiologic diagnosis [9]. Once the patient has been labeled within a MCI category, then a specific diagnostic procedure must start to understand which disease or condition is responsible for the deficit. FDG-PET plays its major clinical role in this context by showing (or not) specific disease patterns.

Neuropsychological assessment in AD has shown that an episodic verbal memory deficit is the core for the diagnosis even at a MCI stage. Some patients (especially if younger than 65) may fail in a language or in a visuoconstruction task, maintaining a normal memory function. When a typical single-domain (even more if multi-domain) aMCI patient with a clinical suspicion of AD undergoes FDG-PET, the brain regions most frequently reported to show hypometabolism are the posterior cingulate cortex, the precuneus, the lateral parietal (inferior and superior parietal lobules), the lateral temporal, and the lateral frontal cortices. The metabolic deficit predominantly affects the so-called 'association' cortex, while primary sensorimotor cortex, visual cortex, thalami, basal ganglia and the cerebellum are relatively spared.

While lateral posterior temporal-parietal hypometabolism is an old finding deriving from early studies in the 80ies and confirming previous reports with stationary Xe-133 devices, hypometabolism in posterior cingulate and precuneus was disclosed later in the mid 90ies [10] mainly as a result of automated voxel-based analysis (VBA), since these median structures are not easily discovered by means of visual

analysis. Hypometabolism in frontal associative cortex, including lateral and orbitofrontal cortex, is classically considered to be a later phenomenon in the course of AD, but the most recent studies with last-generation PET equipments have reported early hypometabolism in lateral frontal cortex (LFC). Drzezga *et al.* [11] re-examined 8 aMCI converters and 12 aMCI non-converters with PET after 1 year. They found the metabolic decline in LFC being a specific marker of cognitive deterioration and included this area in their 'typical' pattern of converting MCI patients [12]. Interestingly, a specific covariance hypoperfusion (CBF-PET) pattern has been found in early AD, involving the Selective Reminding Test, cingulate, inferior parietal lobule, middle and inferior frontal, supramarginal and precentral gyri [13]. In a PET study in 37 aMCI patients [14], the hypometabolic pattern in left LFC and anterior cingulate gave a similar accuracy (87% vs 84%) as hypometabolism in right Brodmann Area (BA) 40 (parietal) in separating aMCI converters and non-converters, but a much higher sensitivity (75% vs 38%). Moving to the pre-symptomatic stage, the left LFC and the bilateral lateral temporal cortex were shown to predict early cognitive decline in a sample of healthy elderly subjects at high risk for AD [15]. This further points to this areas as an early hallmark of neurodegeneration. On the contrary, other authors found that left LFC hypometabolism was a feature of stable MCI patients over time [16]. The left LFC contains the language areas and, moreover, is involved in working memory, episodic memory encoding and semantic memory retrieval [17, 18]. Conversion to AD mainly entails a worsening episodic and working memory that significantly impairs the everyday functional autonomy, which is consistent with the idea that metabolic failure in these areas is a main PET hallmark of conversion.

A very frequent feature of FDG-PET scans is the strong asymmetric involvement especially in the early stages, which is generally correlated with the clinical presentation, mainly language impairment in predominantly left hemisphere hypometabolism and visuospatial impairment in predominantly right hemisphere hypometabolism. As a consequence, visual analysis of scans strongly relies on asymmetric evaluation of abnormalities (an example in Fig. 1). Early-onset AD (i.e., before the age of 60) is more often characterized by posterior lateral temporo-parietal hypometabolism as compared to late-onset AD in which medial temporal hypometabolism prevails [19].

A crucial issue is the finding of posterior cingulate hypometabolism aMCI patients who do not convert to AD after some years (from 1 to 2) of follow-up [20]. Nestor *et al.* [21] have suggested that significant hypometabolism in the posterior cingulate is typical for all MCI patients, without a direct relationship to their future conversion. In a recent SPECT study, aMCI converters and nonconverters were found to share a common retrosplenial pattern of hypoperfusion [22], suggesting that retrosplenial cortex dysfunction could be the pathophysiological correlate of memory impairment, without being a biomarker of conversion to dementia. In this view, hypometabolism in these regions seems an early marker of memory impairment rather than of AD conversion. It may be argued that the follow-up period is not long enough to allow conversion in all those aMCI patients that are already affected by AD

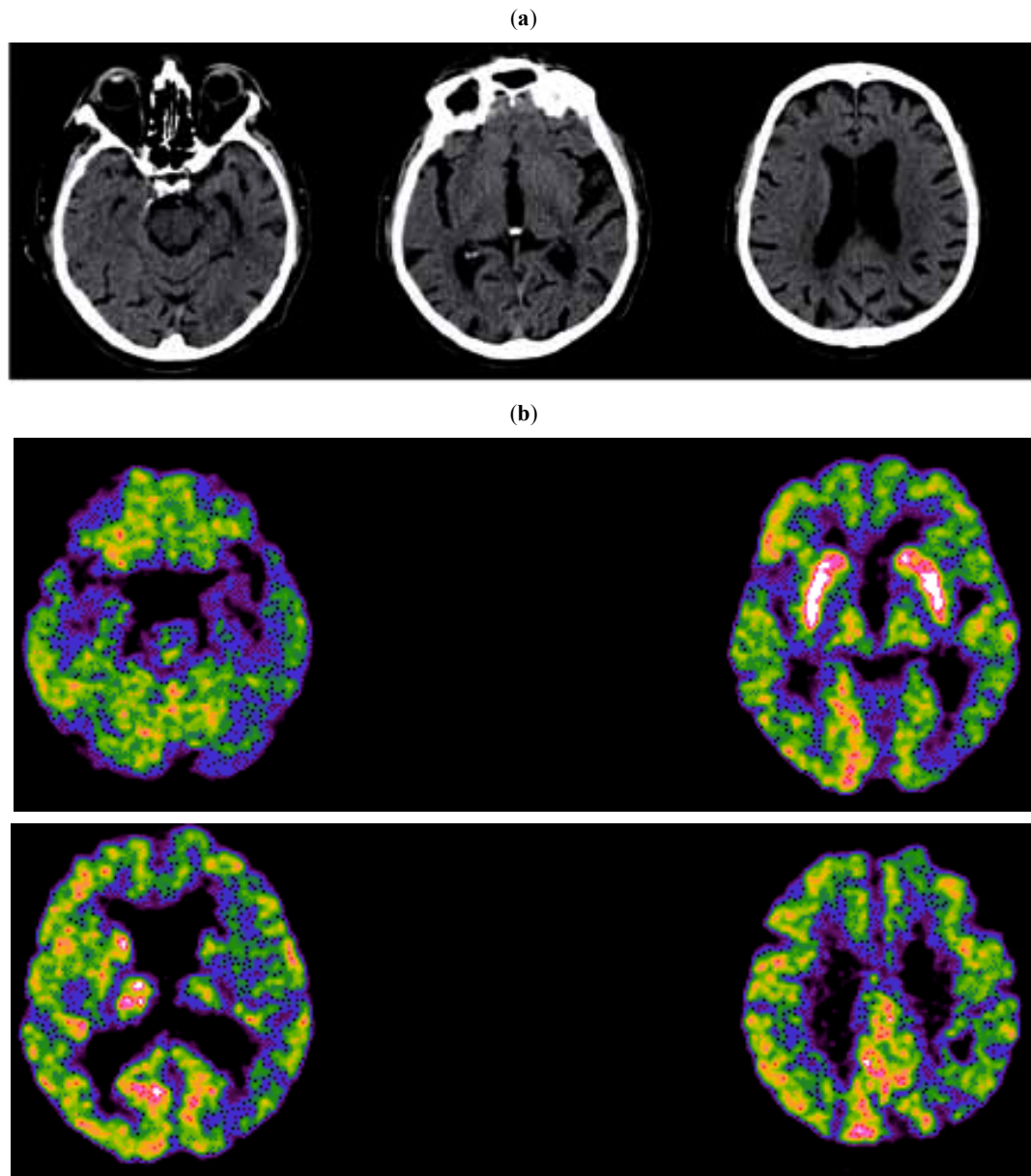


Fig. (1). The Computed Tomography (a) and the FDG-PET (b) scans of a 85-year old man with memory deficit and mild impairment in executive functions and visuospatial tasks are reported. The MMSE score was 28 and the everyday functioning was fully preserved, thus qualifying this patient as a multi-domain amnesic MCI on a clinical ground. Neuroimaging disclosed a AD-like pattern, with significant atrophy in left medial temporal lobe, lateral temporal cortex and moderate ventricular enlargement (a), and hypometabolism in several areas of the left hemisphere, notably the posterior parietal cortex, the posterior cingulate and precuneus, and medial temporal lobe (b).

pathology. This is possible, of course, although the majority of aMCI patients who convert to AD dementia do so within the first 2 years of follow-up [23]. Further studies with longer follow-up periods are needed to clarify this issue.

Since the accuracy of FDG-PET to detect AD pathology in aMCI patients is high but not absolute, efforts have been made to combine it with other biomarkers or with neuropsychological (memory) test scores. Anchisi *et al.* [16] utilised PET and the California Verbal Learning Test-long delay free recall together and showed an improvement in the detection of aMCI converters to AD, as compared to each of the two taken alone. A good discriminative value has been obtained by combining neuropsychology and MRI atrophy analyses [24], by combining neuropsychology, PET and

apolipoprotein E (ApoE) genotype [14], or PET, ApoE genotype and CSF markers [25]. It has recently been shown that baseline FDG-PET already shows an AD-hypometabolism pattern in aMCI patients who decline in memory even they are not demented yet [26]. However, the added value of neuropsychology to PET has not been confirmed by other studies [27].

A sometimes not enough stressed issue is that only some investigations employed normal controls [11, 16, 20, 26, 28-30]. Moreover, while aMCI patients are regularly followed over time to pick up conversion, normal controls are rarely monitored to confirm their normal status over time [20, 28, 30]. Moreover, studies employing normal controls were based on VBA comparison of metabolic data and assessed

differences based on two-group comparisons (various combinations of MCI non-converters, MCI converters and controls), while a three-group analysis, also including controls, would be more meaningful, better analyzing possible areas of overlap. In fact, the heterogeneous population of MCI patients tends to overlap with normal ageing on the one hand and with AD on the other hand [31]. In one such study the correct allocation of controls, aMCI non-converters and aMCI converters of FDG-PET and a memory test combined together was 100%, 91% and 82%, respectively [30]. Thus, a higher specificity than sensitivity. By meta-analysing some studies in the literature, an average value of 86% for both sensitivity and specificity and a very high negative predictive value have been computed. A normal FDG-PET in MCI indicates a low chance of progression within 1 year, even if there is a severe memory deficit on neuropsychological testing [16].

The finding of hypometabolism in the medial temporal cortex (hippocampus, parahippocampal gyrus and entorhinal cortex) is much more uncertain as it is generally not reported by early studies and by the studies employing automated voxel-based analysis (VBA), such as Statistical Parametric Mapping (SPM).

Mosconi reviewed and discussed this issue [32]. The first generations of PET equipments had relatively poor (7–10 mm) spatial resolution, a problem with small brain regions, such as the hippocampus. However, conflicting results have been reported even with newer generation instruments because just a part of the studies showed hippocampal hypometabolism in AD or MCI [15, 21, 33–35]. It is noteworthy, that these 'positive' studies all used the anatomical segmentation of hippocampus, guided by co-registered MRI/PET and the manual region of interest (ROI) method. The 'negative' results are derived from studies not using MRI co-registration [36, 37], resulting in a potentially missed target, or using axial scan acquisition and sampling procedures, where the hippocampal dimensions and slice thickness do not facilitate isotope recovery [36, 38]. Without using re-orientation on the so-called 'Onishi transaxial plan' (i.e., about 30 degrees with the nose upward with respect to the bicommissural plane), analysis of transaxial slices is inadequate to segment the hippocampus that indeed is not parallel to the bicommissural plane. Finally, some FDG-PET studies using automated voxel-based analysis (VBA) techniques [39–41] failed to report hippocampal hypometabolism, but this could be an artifact of the normalization and smoothing preliminary steps before analysis. As a matter of fact, hippocampal hypometabolism has been repeatedly shown when accurate MRI-guided segmentation of hippocampi has been performed [21, 32, 35]. This last finding is in keeping with the visual analysis of individual FDG-PET scans, as well as with previous SPECT findings [42].

Despite these arguments, hypometabolism in posterior temporo-parietal cortex and LFC association cortex remains the most easy to be defined even at a visual scan analysis, while medial temporal lobe impairment is more easily seen on Magnetic Resonance Imaging (MRI) scans. When analysed together in aMCI patients by means of VBA, the former is the main finding with FDG-PET while the latter with MRI [20]. The topographical mismatch between

MRI/pathology and PET results may be explained in terms of AD disconnection syndrome, as both the precuneus and posterior cingulate are densely interconnected with the hippocampus and parahippocampal region [43]. PET measurements of glucose consumption reflect local baseline integrated synaptic activity and therefore are mainly sensitive to synaptic dysfunction rather than to neuronal loss [2], while VBM assesses structural changes only. Neuropathological studies have shown that degeneration of neuronal synapses and neuronal processes, and the shrinkage of neuronal cell bodies of neurons, may precede the death and elimination of neurons in AD for a substantial period [44].

FDG-PET has been reported to be highly sensitive to metabolism reduction in AD patients over time, in follow-up studies lasting 1 year [11, 45]. This means that it is a suitable marker to follow the disease evolution and, as a consequence, to evaluate the potential effect of both symptomatic and neuroprotective agents [46]. It has been computed that metabolism reduction in critical regions is in the order of 16–19% over 3 years, while in healthy subjects is virtually absent in such a time span [47]. A power analysis of hypometabolic effect after 1 year has revealed that 24 to 36 AD patients are needed for each group (e.g., drug and placebo groups) to detect the strongest metabolic reduction. Just for comparison, the power of the ADAS-COG, the main neuropsychological scale used in pharmacological trials, is more than 150 patients [45].

The sensitivity of FDG-PET to detect longitudinal changes was better than that of the emerging amyloid-PET which, on the contrary, might reveal amyloid pathology earlier than FDG-PET can reveal hypometabolism in the pre-symptomatic stage. According to the available data to date, amyloid-PET would reach a 'plateau' very early in the course of the disease, thus hampering adequate sensitivity to further follow-up [48].

Present limitations of FDG-PET are that no standard analytical procedure has been established yet. In each nuclear medicine unit throughout the world, scans are analysed in very different ways, ranging from simple visual evaluation to sophisticated computer-assisted comparisons with normative database, either already available in working stations and supplied by the manufacturer or locally established. If the simple visual analysis may be too sensitive even to trivial or physiological asymmetries and impairment in median structure hypometabolism can be missed, automatic analysis suffers from opposite issues, because it is generally very specific but scarcely sensitive. Moreover, pre-disposed normative database may be inadequate for age span, number of subjects, or acquisition modalities and the quality of locally-prepared normal database depend on selection criteria for normality, its definition not being easy.

Another still unsolved question is that a large study in a sizable number of aMCI patients and controls with an adequate follow-up time (e.g., at least 2-3 years) is still lacking. All the information we have comes from studies reporting a maximum number of 40-45 aMCI subjects [14, 16], of whom about a half are converting to AD. A multi-centre study on larger series is needed. In this frame, the Neuroimaging study group of the European Alzheimer

Disease Consortium (<http://eadc.alzheimer-europe.org/>) has launched a data-sharing project across centres.

PATHOPHYSIOLOGICAL MEANING OF FDG-PET FINDINGS IN ALZHEIMER'S DISEASE

Glucose hypometabolism identified by FDG-PET scans is referred to two phenomena. The decrease in synaptic number, activity or synaptic dysfunction locally in the neurons of regions affected by Alzheimer type pathological changes and the same phenomena in distant regions but receiving projections from these primary, diseased neurons [49-53]. Thus, abnormalities in regional metabolism are thought to reflect the pattern of neuropathologic development of AD with early prominent AD changes in the medial temporal cortex and its projections to cingulate and parietotemporal association cortices [54]. It is noteworthy that cingulate and parietotemporal regions become affected themselves by the disease process probably soon after the medial temporal lobe [55]. In this view, FDG-PET findings precede neurodegeneration in these regions by showing synaptic dysfunction before cellular loss. Similarly, patients with aMCI but already affected with AD pathology may only suffer from hypometabolism in the medial temporal cortex [15, 21], while those patients with additional hypometabolism in the temporoparietal association cortex may represent a later stage of severity [14, 56].

But new scenarios have been opened since 2001 when Raichle introduced the term 'default-mode' to describe the brain function activity pattern during rest [57]. A brief description of this concept is needed to understand why it could be relevant to interpret the pathophysiology of glucose hypometabolism in AD brain. This default mode network (DMN) would include the relatively hypermetabolic brain areas of an individual that is not focused on any specific activity, entailing a relationship with the outside world, but is focused on task-independent introspection, or self-referential thought. DMN is characterized by coherent neuronal slow (0.1 Hz) to very slow (0.01 Hz) oscillations. This DMN would be deactivated during goal-oriented activity to leave space to other networks, specifically involved in a given task (so called 'task-positive networks', or TPN). It is thought that during a specific task the deactivated DMN and the TPN should be considered opposite elements of a single default network with anti-correlated components [58]. However, the hypothesis that the DMN is related to internally directed thought or that it can be an useful concept for a theory of mind is still widely debated [59, 60]. The DMN is not the only 'low-frequency' resting state. Also others have been described, such as visual and auditory networks [58].

The DMN is an interconnected and anatomically defined brain system including part of the medial temporal lobe for memory, of the medial prefrontal cortex for mental simulations, and the posterior cingulate cortex for integration, along with the precuneus and the medial, lateral and inferior parietal cortices [61]. These regions showed a greater BOLD fMRI activity during rest than during any attention-demanding task of a number of experimental paradigms [62].

How are these concepts relevant for the issue of brain hypometabolism in aMCI and AD? The Munich's research

group has recently reviewed this issue in depth [63]. It has been shown that DMN changes during a visual encoding task and is able during a non-spatial working memory task to distinguish between healthy aging, MCI and mild AD. The degree of deactivation was lower in AD patients than in MCI patients, and lower in MCI patients than in healthy controls [64]. By means of a simple sensory-motor processing task paradigm and fMRI, the decreased DMN activity in the posterior cingulate and hippocampus in healthy aging subjects as compared to AD patients was sensitive and specific enough to differentiate between the two conditions and could therefore be a promising approach to identify AD [65]. The question whether this inability to deactivate the DMN is related to structural changes and thus to the hypometabolic findings in the regions belonging to the DMN is still unanswered. Recent studies suggested that the permanent neuronal background activity of the DMN might enhance a vicious circle leading to an increased deposition of amyloid-plaques in specific cerebral regions [66-68]. The observation that the common default network pattern in young adults astonishingly resembles the pattern of amyloid plaque deposition and subsequently cortical atrophy, supports this theory [66, 69]. Even if the DMN activity would not have a causal role in inducing plaque formation, it could have a facilitating one. It has been proposed [66] that parietal memory networks, related to the medial temporal lobes, are more prone to be affected by the pathological process of plaque deposition and subsequently atrophy, thereby leading to memory decline.

CLINICAL MEANING AND SUGGESTED USE OF FDG-PET IN ALZHEIMER'S DISEASE

Despite it is a long time that FDG-PET is proficiently used in dementia, its full clinical utility was appreciated only recently. The 2001 American Academy of Neurology Practice Parameter for the diagnosis of dementia prudently stated that PET was 'just' promising but requiring further studies 'to establish the value that it brings to diagnosis over and above a competent clinical diagnosis.' [70]. Just following these statements, a study including 284 patients undergoing dementia workup, with 138 having neuropathological diagnosis was reported [71]. In that paper a typical AD pattern (i.e., parietal and temporal hypometabolism, with or without frontal involvement) showed a sensitivity of 94% and a specificity of 73% in comparison to neuropathologic diagnosis. Since then these data have been confirmed, with differences depending on comparisons with clinical or pathologic definitions of disease [14, 16, 30, 50, 72, 73]. In an attempt to clarify the sensitivity and specificity of PET, one metaanalysis published through 2003 found significant faults in the generalizability of these studies overall [72]. Sensitivity of PET was 86% (95% CI: 76-93%) and specificity was 86% (95% CI: 72-93%) [72].

For the clinical practice which suggestion on the use of FDG-PET could we give in the dementia work-up? First, it should be stressed that such an expensive and time-consuming examination with high radioactive exposure should only be managed by third-level dementia clinics in the frame of a full diagnostic work-up. This means that the access to brain FDG-PET should be evaluated by the referring physician together with the nuclear medicine

physician just in clinically definite conditions. The flow-chart includes a syndromic definition of the cognitive disorder, based on clinical examination, interview, formal neuropsychological tests and clinical scales, in a dementia-dedicated unit [9]. If a patient is definitely affected by dementia, then he/she must undergo MRI for a more precise definition of the dementia syndrome, which resolves the majority of doubts and allows an etiological diagnosis of probability, according to the current clinical criteria for AD, Lewy-body dementia (LBD), frontotemporal dementia (FTD), vascular dementia, and so on. Ancillary examinations are used to diagnose secondary dementias. If the dementia specialist is confident enough with the diagnosis, FDG-PET is unnecessary. If some differential diagnosis concern still remains (typically between AD and FTD or LBD), then a radionuclide brain examination is indicated. LBD is better identified by [123I]FP-CIT or β -CIT SPECT scan marking the Dopamine Transporter (DAT)[74]. If the dementia is severe enough (e.g., a Mini-Mental State Examination, MMSE, lower than 20), generally perfusion SPECT is adequate [75] and may be both cheaper and more widely accessible. If on the contrary the dementia is milder (e.g., MMSE>20), then FDG-PET is indicated. But the full field of application of FDG-PET is in those patients with MCI, either aMCI or naMCI, in whom a neurodegenerative process is suspected but cannot be proven on the basis of clinical and MRI only. In this setting, FDG-PET, amyloid-PET, and CSF biomarker assays are of paramount importance [76] and can allow a specific disease to be diagnosed. The use of FDG-PET in subjects with subjective memory deficit (i.e., those patients referring a memory deficit but who score within – 1.5 standard deviation from the mean of age-matched healthy control groups in memory tests) is debated and should probably be left to investigational use only at present.

REFERENCES

- Magistretti PJ, Pellerin Philos L. Trans R Soc Lond B Biol Sci 1999; 354: 1155-63.
- Magistretti PJ. Cellular basis of functional brain imaging: insight from neural-glia metabolic coupling. Brain Res 2000; 886: 108-12.
- Sokoloff L. Relation between physiological function and energy metabolism in the central nervous system. J Neurochem 1977; 29: 13-26.
- Rocher AB, Chapon F, Blaizot X, Baron JC, Chavoix C. Resting-state brain glucose utilization as measured by PET is directly related to regional synaptophysin levels: a study in baboons. Neuroimage 2003; 20: 1894-8.
- Link at the Society of Nuclear Medicine (SNM) website: <http://interactive.snm.org/docs/Society%20of%20Nuclear%20Medicine%20Procedure%20Guideline%20for%20FDG%20PET%20Brain%20Imaging.pdf>
- Varrone A, Asenbaum S, Vander Borgh T, et al. EANM procedure guidelines for PET brain imaging using [(18)F]FDG, version 2. Eur J Nucl Med Mol Imaging 2009; 36: 2103-10.
- Petersen RC, Smith GE, Waring SC, Ivnik RJ, Tangalos EG, Kokmen E. Mild cognitive impairment: clinical characterization and outcome. Arch Neurol 1999; 56: 303-8.
- Petersen RC, Negash S. Mild cognitive impairment: an overview. CNS Spectr 2008; 13: 45-53.
- Portet F, Ousset PJ, Visser PJ, et al. Report of the MCI Working Group of the European Consortium on Alzheimer's Disease (EADC): a critical review of the concept and new diagnostic Mild cognitive impairment (MCI) in medical practice. J Neurol Neurosurg Psychiatry 2006; 77: 714-8.
- Minoshima S, Giordani B, Berent S, et al. Metabolic reduction in the posterior cingulate cortex in very early Alzheimer's disease. Ann Neurol 1997; 42: 85-94.
- Drzezga A, Lautenschlager N, Siebner H, et al. Cerebral metabolic changes accompanying conversion of mild cognitive impairment into Alzheimer's disease: a PET follow-up study. Eur J Nucl Med Mol Imaging 2003; 30: 1104-13.
- Drzezga A, Grimmer T, Riemenschneider M, et al. Prediction of individual clinical outcome in MCI by means of genetic assessment and 18F-FDG PET. J Nucl Med 2005; 46: 1625-32.
- Scarmeas N, Habeck CG, Zarahn E, et al. Covariance PET patterns in early Alzheimer's disease and subjects with cognitive impairment but no dementia: utility in group discrimination and correlations with functional performance. NeuroImage 2004; 23: 35-45.
- Mosconi L, Perani D, Sorbi S, et al. MCI conversion to dementia and the APOE genotype: A prediction study with FDG-PET. Neurology 2004; 63: 2332-40.
- de Leon MJ, Convit A, Wolf OT, et al. Prediction of cognitive decline in normal elderly subjects with 2-[18F]fluoro-2-deoxy-D-glucose/positron-emission tomography (FDG/PET). Proc Natl Acad Sci USA 2001; 98: 10966-71.
- Anchisi D, Borroni B, Franceschi F, et al. Heterogeneity of brain glucose metabolism in mild cognitive impairment and clinical progression to Alzheimer disease. Arch Neurol 2005; 62: 1728-33.
- Cabeza R, Nyberg L. Imaging cognition. II. An empirical review of 275 PET and fMRI studies. J Cogn Neurosci 2000; 12: 1-47.
- Simic G, Bexheti S, Kelovic Z, et al. Hemispheric asymmetry, modular variability and age-related changes in the human entorhinal cortex. Neuroscience 2005; 130: 911-25.
- Kim EJ, Cho SS, Jeong Y, et al. Glucose metabolism in early onset versus late onset Alzheimer's disease: an SPM analysis of 120 patients. Brain 2005; 128: 1790-801.
- Morbelli S, Piccardo A, Villavecchia G, et al. Mapping brain morphological and functional conversion patterns in amnesic MCI: a voxel-based MRI and FDG-PET study. Eur J Nucl Med Mol Imaging 2010; 37: 36-45.
- Nestor PJ, Fryer TD, Smielewski P, Hodges JR. Limbic hypometabolism in Alzheimer's disease and mild cognitive impairment. Ann Neurol 2003; 54: 343-51.
- Caroli A, Testa C, Geroldi C, et al. Cerebral perfusion correlates of conversion to Alzheimer's disease in amnesic mild cognitive impairment. J Neurol 2007; 254: 1698-707.
- Mitchell AJ, Shiri-Feshki M. Temporal trends in the long term risk of progression of mild cognitive impairment: a pooled analysis. J Neurol Neurosurg Psychiatry 2008; 79: 1386-91.
- Visser PJ, Scheltens P, Verhey FRJ, et al. Medial temporal lobe atrophy and memory dysfunction as predictors for dementia in subjects with mild cognitive impairment. J Neurol 1999; 246: 477-85.
- Mosconi L, De Santi S, Brys M, et al. Hypometabolism and altered cerebrospinal fluid markers in normal apolipoprotein E E4 carriers with subjective memory complaints. Biol Psychiatry 2008; 63: 609-18.
- Pagani M, Dessi B, Morbelli S, et al. MCI patients declining and not-declining at mid-term follow-up: FDG-PET findings. Curr Alzheimer Res 2009 Nov 26 [Epub ahead of print].
- Chetelat G, Eustache F, Viader F, et al. FDG-PET measurement is more accurate than neuropsychological assessments to predict global cognitive deterioration in patients with mild cognitive impairment. Neurocase 2005; 11: 14-25.
- Mosconi L, Tsui WH, Pupi A, et al. 18F-FDG PET database of longitudinally confirmed healthy elderly individuals improves detection of mild cognitive impairment and Alzheimer's disease. J Nucl Med 2007; 48: 1129-34.
- Hunt A, Schönknecht P, Henze M, Seidl U, Haberkorn U, Schröder J. Reduced cerebral glucose metabolism in patients at risk for Alzheimer's disease. Psychiatry Res: Neuroimaging 2007; 155: 147-54.
- Nobili F, Salmaso D, Morbelli S, et al. Principal component analysis of FDG PET in amnesic MCI. Eur J Nucl Med Mol Imaging 2008; 35: 2191-202.
- Feldman HH, Jacova C. Mild cognitive impairment. Am J Geriatr Psychiatry 2005; 13: 645-55.
- Mosconi L, Tsui WH, De Santi S, et al. Reduced hippocampal metabolism in mild cognitive impairment and Alzheimer's disease: automated FDG-PET image analysis. Neurology 2005; 64: 1860-7.
- de Leon MJ, McRae T, Rusinek H, et al. Cortisol reduces hippocampal glucose metabolism in normal elderly but not in Alzheimer's disease. J Clin Endocrinol Metab 1997; 82: 3251-9.
- Ouchi Y, Nobezawa S, Okada H, Yoshikawa E, Futatsubashi M, Kaneko M. Altered glucose metabolism in the hippocampal head in memory impairment. Neurology 1998; 51: 136-42.

- [35] De Santi S, de Leon MJ, Rusinek H, *et al.* Hippocampal formation glucose metabolism and volume losses in MCI and AD. *Neurobiol Aging* 2001; 22: 529-39.
- [36] Jagust WJ, Eberling JL, Richardson BC, *et al.* The cortical topography of temporal lobe hypometabolism in early Alzheimer's disease. *Brain Res* 1993; 629: 189-98.
- [37] McKelvey R, Bergman H, Stern J, Rush C, Zahirney G, Chertkow H. Lack of prognostic significance of SPECT abnormalities in nondemented elderly subjects with memory loss. *Can J Neurol Sci* 1999; 26: 23-8.
- [38] Ishii K, Sasaki M, Yamaji S, Sakamoto S, Kitagaki H, Mori E. Relatively preserved hippocampal glucose metabolism in mild Alzheimer's disease. *Dement Geriatr Cogn Dis* 1998; 9: 317-22.
- [39] Friston KJ, Frith CD, Liddle PF, Frackowiak RSJ. Comparing functional (PET) images: the assessment of significant change. *J Cereb Blood Flow Metab* 1991; 11: 690-9.
- [40] Friston K, Ashburner J, Frith C, Poline J-B, Heather J, Frackowiak R. Spatial registration and normalization of images. *Hum Brain Mapp* 1995; 3: 165-89.
- [41] Minoshima S, Frey KA, Koeppe RA, Foster NL, Kuhl DE. A diagnostic approach in Alzheimer's disease using three-dimensional stereotactic surface projections of fluorine-18-FDG PET. *J Nucl Med* 1995; 36: 1238-48.
- [42] Rodriguez G, Vitali P, Calvini P, *et al.* Hippocampal perfusion in mild Alzheimer's disease. *Psychiatry Res* 2000; 100: 65-74.
- [43] Braak H, Braak E. Evolution of the neuropathology of Alzheimer's disease. *Acta Neurol Scand* 1996; 165 (Suppl): 3-12.
- [44] Price JL, Morris JC. Tangles and plaques in non demented aging and "preclinical" Alzheimer's disease. *Ann Neurol* 1999; 45: 358-68.
- [45] Alexander GE, Chen K, Pietrini P, Rapoport SI, Reiman EM. Longitudinal PET evaluation of cerebral metabolic decline in dementia: a potential outcome measure in Alzheimer's disease treatment studies. *Am J Psychiatry* 2002; 159: 738-45.
- [46] Pupi A, Mosconi L, Nobili FM, Sorbi S. Toward the validation of functional neuroimaging as a potential biomarker for Alzheimer's disease: implications for drug development. *Mol Imaging Biol* 2005; 7: 59-68.
- [47] Smith GS, de Leon MJ, George AE, *et al.* Topography of cross-sectional and longitudinal glucose metabolic deficits in Alzheimer's disease. Pathophysiologic implications. *Arch Neurol* 1992; 49: 1142-50.
- [48] Engler H, Forsberg A, Almkvist O, *et al.* Two-year follow-up of amyloid deposition in patients with Alzheimer's disease. *Brain* 2006; 129: 2856-66.
- [49] Friedland RP, Brun A, Budinger TF. Pathological and positron emission tomographic correlations in Alzheimer's disease. *Lancet* 1985; i: 228.
- [50] Hoffman JM, Welsh-Bohmer KA, Hanson M, *et al.* FDG PET imaging in patients with pathologically verified dementia. *J Nucl Med* 2000; 41:1920-8.
- [51] Matsuda H. The role of neuroimaging in mild cognitive impairment. *Neuropathology* 2007; 27: 570-7.
- [52] Mielke R, Schröder R, Fink GR, Kessler J, Herholz K, Heiss WD. Regional cerebral glucose metabolism and postmortem pathology in Alzheimer's disease. *Acta Neuropathol* 1996; 91: 174-9.
- [53] Valla J, Berndt JD, Gonzalez-Lima F. Energy hypometabolism in posterior cingulate cortex of Alzheimer's patients: superficial laminar cytochrome oxidase associated with disease duration. *J Neurosci* 2001; 21: 4923-30.
- [54] Brun A, Englund E. Brain changes in dementia of Alzheimer's type relevant to new imaging diagnostic methods. *Prog Neuropsychopharmacol Biol Psychiatry* 1986; 10: 297-308.
- [55] Braak H, Braak E. Neuropathological staging of Alzheimer-related changes. *Acta Neuropathol* 1991; 82: 239-59.
- [56] Chetelat G, Desgranges B, de la Sayette V, Viader F, Eustache F, Baron JC. Mild cognitive impairment: Can FDG-PET predict who is to rapidly convert to Alzheimer's disease? *Neurology* 2003; 60: 1374-7.
- [57] Raichle ME, MacLeod AM, Snyder AZ, Powers WJ, Gusnard DA, Shulman GL. 'A default mode of brain function'. *Proc Natl Acad Sci USA* 2001; 98: 676-82.
- [58] Broyd SJ, Demanuele C, Debener S, Helps SK, James CJ, Sonuga-Barke EJS. 'Default-mode brain dysfunction in mental disorders: a systematic review'. *Neurosci Biobehav Rev* 2009; 33: 279-96.
- [59] Fair DA, Cohen AL, Dosenbach NU, *et al.* The maturing architecture of the brain's default network. *Proc Natl Acad Sci USA* 2008; 105: 4028-32.
- [60] Morcom AM, Fletcher PC. Does the brain have a baseline? Why we should be resisting a rest. *Neuroimage* 2007; 37: 1073-82.
- [61] Buckner RL, Andrews-Hanna JR, Schacter DL. "The brain's default network: anatomy, function, and relevance to disease". *Ann N Y Acad Sci* 2008; 1124: 1-38.
- [62] Shulman GL, Fiez JA, Corbetta M, *et al.* Common blood flow changes across visual tasks: II. Decreases in cerebral cortex. *J Cogn Neurosci* 1997; 9: 648-63.
- [63] Wermke M, Sorg C, Wohlschläger AM, Drzezga A. A new integrative model of cerebral activation, deactivation and default mode function in Alzheimer's disease. *Eur J Nucl Med Mol Imaging* 2008; 35(Suppl 1): S12-S24.
- [64] Rombouts SA, Barkhof F, Goekoop R, Stam CJ, Scheltens P. Altered resting state networks in mild cognitive impairment and mild Alzheimer's disease: an fMRI study. *Hum Brain Mapp* 2005; 26: 231-9.
- [65] Greicius MD, Srivastava G, Reiss AL, Menon V. Default-mode network activity distinguishes Alzheimer's disease from healthy aging: evidence from functional MRI. *Proc Natl Acad Sci USA* 2004; 101: 4637-42.
- [66] Buckner RL, Snyder AZ, Shannon BJ, *et al.* Molecular, structural, and functional characterization of Alzheimer's disease: evidence for a relationship between default activity, amyloid, and memory. *J Neurosci* 2005; 25: 7709-17.
- [67] Cirrito JR, Yamada KA, Finn MB, *et al.* Synaptic activity regulates interstitial fluid amyloid beta levels *in vivo* [see comment]. *Neuron* 2005; 48: 913-22.
- [68] Selkoe DJ. Amyloid beta-peptide is produced by cultured cells during normal metabolism: a reprise. *J Alzheimer Dis* 2006; 9: 163-8.
- [69] Scahill RI, Schott JM, Stevens JM, Rossor MN, Fox NC. Mapping the evolution of regional atrophy in Alzheimer's disease: unbiased analysis of fluid-registered serial MRI [see comment]. *Proc Natl Acad Sci USA* 2002; 99: 4703-7.
- [70] Knopman DS, DeKosky ST, Cummings JL, *et al.* Practice parameter: Diagnosis of dementia (an evidence-based review). Report of the Quality Standards Subcommittee of the American Academy of Neurology. *Neurology* 2001; 56: 1143-53.
- [71] Silverman DH, Small GW, Chang CY, *et al.* Positron emission tomography in evaluation of dementia: Regional brain metabolism and long-term outcome. *JAMA* 2001; 286: 2120-7.
- [72] Patwardhan MB, McCrorg DC, Matchar DB, Samsa GP, Rutschmann OT. Alzheimer disease: operating characteristics of PET—A meta-analysis. *Radiology* 2004; 231: 73-80.
- [73] Jagust W, Reed B, Mungas D, Ellis W, Decarli C. What does fluorodeoxyglucose PET imaging add to a clinical diagnosis of dementia? *Neurology* 2007; 69: 871-7.
- [74] McKeith I, O'Brien J, Walker Z, *et al.* DLB Study Group. Sensitivity and specificity of dopamine transporter imaging with 123I-FP-CIT SPECT in dementia with Lewy bodies: a phase III, multicentre study. *Lancet Neurol* 2007; 6: 305-13.
- [75] Dougall N, Nobili F, Ebmeier KP. Predicting the accuracy of a diagnosis of Alzheimer's disease with 99mTc HMPAO single photon emission computed tomography. *Psychiatry Res* 2004; 131: 157-68.
- [76] Dubois B, Feldman HH, Jacova C, *et al.* Research criteria for the diagnosis of Alzheimer's disease: revising the NINCDS-ADRDA criteria. *Lancet Neurol* 2007; 6: 734-46.

Received: October 1, 2009

Revised: November 23, 2009

Accepted: January 7, 2010

© Nobili and Morbelli; Licensee Bentham Open.

This is an open access article licensed under the terms of the Creative Commons Attribution Non-Commercial License (<http://creativecommons.org/licenses/by-nc/3.0/>) which permits unrestricted, non-commercial use, distribution and reproduction in any medium, provided the work is properly cited.