

Differential Diagnosis Between Neurodegenerative Dementia Disorders and Parkinson's Disease Using ^{99m}Tc -HMPAO SPECT

Barbara Palumbo^{*,1}, Donatella Siepi¹, Serena Amici² and Helmut Sinzinger³

¹Nuclear Medicine Section, Department of Surgical, Radiological and Odontostomatological Sciences, University of Perugia, Perugia, Italy

²Neurology Unit, Azienda USL 2, Perugia, Italy

³Department of Nuclear Medicine, Medical University of Vienna, Austria

Abstract: *Introduction and Objective:* To investigate perfusion in dementia and Parkinson's disease (PD) we performed ^{99m}Tc -HMPAO brain SPECT with semiquantitative analysis of Brodmann areas in different aged patients.

Materials and Methods: We retrospectively evaluated 104 patients, 30 with Alzheimer's disease (AD), 26 with frontotemporal dementia (FTD), 25 with mild cognitive impairment (MCI), 23 with PD, undergoing ^{99m}Tc -HMPAO brain SPECT. SPECT data of 3D ROIs of predefined Brodmann's area templates were compared with those of a database of age and sex-matched healthy subjects. Median values and inter-quartile ranges were used to summarize ROIs of Brodmann areas (L= left, R= right) in the different groups; Kruskal-Wallis test evaluated difference between medians ($p < 0.05$ as level of significance).

Results: Different Brodmann areas were significantly hypoperfused in the different pathological categories. Both Areas 37 (temporal gyrus) and 39 (angular gyrus) of AD patients were hypoperfused ($p < 0.05$) compared with MCI and FTD, both Areas 40 (supramarginal gyrus) and Area 39 L of AD patients were ($p < 0.01$) hypoperfused comparing with PD; in FTD both Areas 47 (frontal association cortex) showed significantly decreased ($p < 0.05$) perfusion compared with MCI and Area 11 R (frontal-orbital gyrus) comparing with PD.

Conclusion: Perfusion impairment of specific parietal and temporal areas characterized AD, while frontal area hypoperfusion was present in FTD. No specific hypoperfusion pattern was evident for MCI and PD.

Keywords: Alzheimer's disease, brain SPECT, mild cognitive impairment, frontotemporal dementia, Parkinson's disease, ^{99m}Tc -HMPAO.

INTRODUCTION

Nuclear medicine techniques have been increasingly used to increase diagnostic accuracy in neurodegenerative diseases [1-6]. Parkinson's disease (PD) has been extensively investigated by using brain neurotransmission SPECT both with ^{123}I -labelled dopamine transporter ligands and dopamine D2 receptor radiolabelled ligands [1-3] to detect dopaminergic system impairment, that represents the main pathological feature of disease. Dementia disorders have been evaluated in the literature by brain perfusion SPECT and ^{18}F -fluoro-deoxy-glucose (^{18}F FDG) cerebral PET (4-6), being these diagnostic imaging modalities able to contribute to the differential diagnosis. Hypoperfusion of the different Brodmann areas may reflect functional impairment, thus causing different characteristic symptoms of cognitive decline [4]. Many papers studied perfusion or decreased metabolism in patients with various neurological pathologies

also comparing nuclear medicine modalities with radiological ones [4-10], but the different perfusion or metabolic patterns of Brodmann areas were not shown. In particular to our knowledge no data are available investigating perfusion in the different Brodmann areas in dementia and PD, to contribute to their differential diagnosis. With this aim, we performed ^{99m}Tc -HMPAO brain SPECT with semiquantitative analysis of Brodmann areas in patients with Alzheimer's disease (AD), frontotemporal dementia (FTD) mild cognitive impairment (MCI) and Parkinson's disease (PD).

MATERIALS AND METHODS

Among subjects consecutively referred to the Neurology Unit (Azienda USL 2, Perugia, Italy) and undergoing ^{99m}Tc -HMPAO brain SPECT to contribute to the clinical diagnosis, we retrospectively investigated 104 patients, being clinical data of these subjects retrospectively available. Thirty individuals resulted affected by Alzheimer's Disease (AD) according to the National Institute of Neurological and Communicative Disorders and Stroke and the Alzheimer's Disease and Related Disorders Association (NINCDS ADRDA) criteria [11, 12], 26 by FTD according to Lund and Manchester criteria [13], 25 by MCI according to European

*Address correspondence to this author at the Nuclear Medicine Section, Department of Surgical, Radiological and Odontostomatological Sciences, University of Perugia, Ospedale Santa Maria della Misericordia, Località S. Andrea delle Fratte I-06124, Perugia, Italy; Tel/Fax: 0039-075-5783900; E-mail: barbara.palumbo@unipg.it

Alzheimer's Disease Consortium (EADC) criteria [14], 23 by Parkinson's disease (PD) according to the Consensus Statement of the Movement Disorder Society on Tremor [15] and the Hoehn & Yahr staging scale [16], not showing cognitive decline.

AD patients (16 males, 14 females) had an age range of 69-84 years and the disease duration varied between 1 up to 3 years. The Mini Mental State Examination (MMSE) scores ranged from 10 to 24, Clinical Dementia Rating (CDR) scores were 1-2 and Hamilton Depression Rating Scale (HDRS) scores were <18. Patients with FTD (14 males, 12 females) were 67-82 years old, with MMSE scores of 9-24 and CDR scores of 1-2. MCI patients (12 males, 13 females) had an age range of 64-85 years, MMSE scores of 25-28 and CDR score of 0.5.

All PD patients (10 males, 13 females, range of age 65-84 years) had a H&Y score ≤ 2 , indicating an early stage of the disease. Patients presented very mild symptoms (generally mild bradykinesia and rigidity) with aging brain without cognitive decline, as evidenced by the neuropsychological assessment (MMSE > 27). ^{123}I -FP-CIT brain SPECT was performed to complete the diagnostic work-up to confirm PD, as previously described [1].

All dementia and PD patients had a brain CT scan or MRI negative for focal lesions and showed findings consistent with age (atrophy).

Brain Single-Photon Emission Tomography (SPECT) with $^{99\text{m}}\text{Tc}$ -hexamethyl-propylenamine-oxime (HMPAO) (GE Healthcare, Milwaukee, WI, USA) was carried out in all patients to contribute to the clinical diagnosis. All patients signed a written informed consent. An intravenous administration of 740 MBq of the radiopharmaceutical was performed in each patient in an antecubital vein cannulated 10 min before the scan, the subject being in dorsal decubitus in a room with ambient noise and light under control.

Images were acquired 60 minutes after radiopharmaceutical injection by a dual head gamma-camera (Millennium VG, General Electric Medical System, Milwaukee, WI, USA) equipped with high resolution collimators. A 15% window centered on the 140keV photopeak for $^{99\text{m}}\text{Tc}$ was used. One hundred and twenty projections were carried out with a 128x128 matrix for 25sec per view in a step-and-shoot mode over a 360° orbit with zoom factor 1.5; total acquisition time was 27 minutes. Acquisition was three-dimensionally reconstructed by filtered back projection by means of a Butterworth filter (cut-off frequency 0.5, order 10). Chang's attenuation correction was carried out. Oblique reorientation for transaxial, coronal, and sagittal planes was performed. Images were elaborated by NeuroGam program (Segami Corporation, Columbia, MD, USA), a software application able to map the SPECT brain images into a stereotactic atlas (Talairach) [4].

Three-dimensional volume of the brain was reoriented defining a line that fitted the inferior pole of the occipital lobe and the inferior edge of the frontal lobe; this line was automatically rendered horizontal. Raw data were corrected for lateral deviations defining a line above the interhemispheric fissure and automatically orienting this line in the vertical plane. In the reoriented image the intermediate

level of the pons and anterior plane of the temporal lobes were defined thus defining the vertical anterior commissure line (AC) and the posterior commissure line (PC). The volume of analysis was limited in the lateral planes, superior and inferior planes of the brain. Therefore, the Talairach technique rendered the brain volume into a normalized volume, thus allowing a voxel by voxel comparison of radiopharmaceutical uptake in the brain cortex with a normal data-base of subjects (volumetrically corrected) including normal adults aged 18-45 years and normal subjects older than 45 years. For each patient volumetric reconstructions of the qualitative analysis were obtained, with the cortical perfusion level represented by a colorimetric continue scale (from orange to blue) and volumetric reconstructions of the semiquantitative analysis where regions with perfusion values 2 or 3 standard deviations (SD) above the normal mean values were coloured in red and fuchsia, respectively, and areas with perfusion values 2 or 3 SD below normal mean values in light blue and blue, respectively, as previously described [4]. In Fig. (1) a semiquantitative analysis of a patient with AD is reported.

A predefined Brodmann's area template was used for the semiquantitative analysis to define with high reproducibility the exact localization of hypoperfusion areas. A comparison between perfusion SPECT data of these 3D ROIs and those of the data base of healthy subjects of the same age and gender (as provided by manufacturers) was carried out. Results were expressed as standard deviation difference with respect to normal subjects.

Median values and inter-quartile ranges were used to summarize radiopharmaceutical uptake in the different ROIs in the four groups of patients studied; statistical difference between medians was evaluated by Kruskal-Wallis test, considering $p < 0.05$ as level of significance.

RESULTS

The different groups of patients examined showed significant and specific hypoperfusion patterns in the different Brodmann areas.

AD patients had significant hypoperfusion ($p < 0.05$) in both Areas 37 (temporal gyrus) and 39 (angular gyrus) [median and inter-quartile range 37L: -1.7 (-2.1 - -0.8); 37R: -1.6 (-2.1 - -0.7); 39L: -2.4 (-3.2 - -1.4); 39R: -1.7 (-2.8 - -1.0)] with respect to MCI [37L: -1.0 (-1.7 - -0.4); 37R: -0.9 (-1.8 - -0.5); 39L: -1.5 (-2.3 - -0.7); 39R: -1.0 (-1.7 - -0.4)] and FTD [37L: -1.1 (-1.7 - -0.9); 37R: -1.1 (-1.7 - -0.4); 39L: -1.6 (-2.4 - -0.8); 39R: -0.9 (-2.3 - -0.7)] subjects. Furthermore AD patients presented significantly ($p < 0.01$) reduced perfusion in both Areas 40 (supramarginal gyrus) [40L: -2.6 (-3.4 - -1.8); 40R: -2.0 (-3.2 - -1.4)] compared with MCI patients [40L: -1.6 (-2.5 - -1.2); 40R: -1.8 (-2.7 - -0.7)] and in Area 39 L [39L: -2.4 (-3.2 - -1.4)] compared with PD [39L: -1.2 (-2.0 - -0.9)].

FTD subjects showed significantly decreased perfusion ($p < 0.05$) in both Areas 47 (frontal association cortex) [47L: -2.0 (-2.7 - -1.5); 47R: -1.7 (-2.1 - -0.5)] versus MCI [47L: -1.2 (-2.0 - -0.7); 47R: -0.7 (-1.5 - -0.4)] and in Area 11 R (frontal-orbital gyrus) [11R: -0.5 (-0.6 - 0.8)] versus PD [11R: 0.4 (-0.7 - 0.5)].

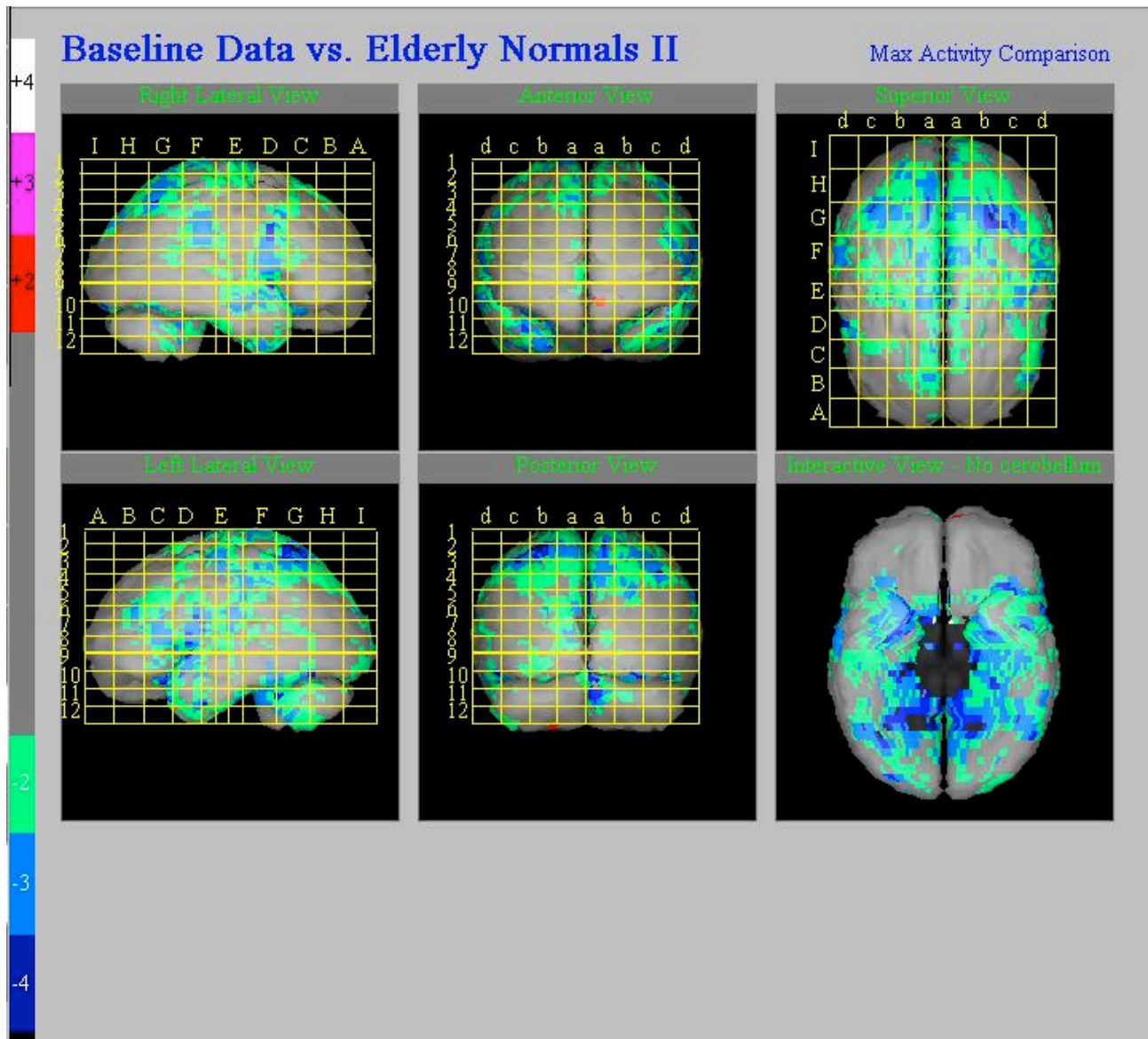


Fig. (1). Brain ^{99m}Tc-HMPAO SPECT of a patient with AD. Volumetric reconstruction of the semiquantitative analysis. On the left part of the figure the colour bar indicating the decrease in standard deviations (SD) with respect to normal sex and age-matched control subjects is reported. A significant hypoperfusion (<2-3 SD with respect to healthy subjects of the same age and gender) is shown in the parietal, occipito-parietal and temporal regions (including Brodmann areas 37, 39 and 40 were significantly different as compared to other patients).

No significantly impaired areas were observed in FTD with respect to AD. The MCI group had diffuse hypoperfusion in specific Brodmann areas.

The Median values and inter-quartile ranges of the different Brodmann areas significantly hypoperfused in the different categories of the patients studied are reported in Table 1.

DISCUSSION

The main result of this study was that only AD was characterized by a definite hypoperfusion pattern as defined by Brodmann areas with respect to all the other groups (FTD, MCI and PD), showing significantly decreased perfusion in bilateral angular, supramarginal and left fusiform gyri. The left angular gyrus (Brodmann area 39) is

located close to the supramarginal gyrus in the parietal lobe and is involved in sentence generation, number processing and calculation. Supramarginal gyrus (Brodmann area 40) is involved in language perception and processing. Brodmann area 37 is an occipito-temporal area of the cortex known as fusiform gyrus, involved in processing of colour information, face and body recognition as well as word recognition. The impairment of these Brodmann areas in our patients seems to represent a functional marker of AD, particularly because all these three areas are polymodal associative cortices that are directly connected with the hippocampus and the amygdala and correspond to stage III of Braak and Braak stage of amyloid plaque deposition [17]. Neurofibrillary changes confined to the entorhinal region and an abundance of cortical amyloid in cases of presenile and senile dementia were present [17].

Table 1. Median Values and Inter-Quartile Ranges of the Different Hypoperfused Brodmann Areas in the Different Categories of Patients Studied

Brodmann Area	AD	FTD	MCI	PD
11 Right	-0.3 (-0.8 – 0.8)	-0.5(-0.6 – 0.8) [‡]	-0.2(-0.8 – 0.3)	0.4(-0.7 – 0.5)
11 Left	-0.3 (-0.9 – 0.5)	-0.2(-1.1 – 0.1)	-0.4 (-1.0 – 0.4)	0.2(-0.9 – 0.4)
37 Right	-1.6 (-2.1 – -0.7)*	-1.1(-1.7 – -0.4)	-0.9(-1.8 – -0.5)	-1.5(-1.9 – -0.6)
37 Left	-1.7 (-2.1 – -0.8)*	-1.1(-1.7 – -0.9)	-1.0(-1.7 – -0.4)	-1.5(-1.9 – -0.6)
39 Right	-1.7(-2.8 – -1.0)*	-0.9(-2.3 – -0.7)	-1.0(-1.7 – -0.4)	-1.5(-2.5 – -0.8)
39 Left	-2.4(-3.2 – -1.4) [°]	-1.6(-2.4 – -0.8)	-1.5(-2.3 – -0.7)	-1.2(-2.0 – -0.9)
40 Right	-2.0(-3.2 – -1.4) [□]	-1.8(-2.8 – -0.7)	-1.8(-2.7 – -0.7)	-1.8(-2.7 – -0.7)
40 Left	-2.6(-3.4 – -1.8) [□]	-2.1 (-3.0 – -1.3)	-1.6(-2.5 – -1.2)	-2.5(-3.5 – -1.1)
47 Right	-1.6 (-1.9 – 0.1)	-1.7 (-2.1 – -0.5) [*]	-0.7(-1.5 – -0.4)	-1.6(-1.9 – -0.5)
47 Left	-1.8 (-2.4 – -0.4)	-2.0(-2.7 – -1.5) [*]	-1.2(-2.0 – -0.7)	-1.7(-2.5 – -0.9)

[‡]p < 0.05 versus PD.

*p < 0.05 versus FTD and MCI.

[°]p < 0.01 versus PD.

[□]p < 0.01 versus MCI.

^{*}p < 0.05 versus MCI.

FTD had a significant hypoperfusion pattern only compared with MCI (in the Frontal Association cortex) and PD (in the frontal-orbital gyrus). The frontal association area of the brain contributes to plan movements. It is also involved in personality, control of emotions and expression of emotional behaviour. The association area of the frontal lobe is also where planning occurs. Frontal-orbital gyrus is a brain area involved in decision making and emotion control. Impairment of brain areas belonging to the Frontal Cortex is consistent with the pathophysiology of FTD, a dementia disorder predominantly characterized by behavioural disturbance, cricity and emotion control loss. It is of interest that impairment of these brain regions was present in our patients only in comparison with less cognitively impaired groups of subjects, i.e. MCI and PD.

The inferior frontal and orbitofrontal gyri are part of the anterior network that is specifically damaged in FTD (anterior cingulate, fronto-insular, orbito-frontal and cingulo-frontal cortices) [18]. This network is involved in social and emotional behaviour and empathy and has its neural correlate in reduction of von Economo neurons in the above described cortical regions [19].

Furthermore, MCI and PD patients were not significantly different and they did not evidence any area of specific decrease in perfusion able to distinguish them from AD and FTD. This could be explained because MCI is characterized by a mild cognitive decline consisting in particular in selective memory loss that is associated with only hippocampal and entorhinal cortex hypoperfusion, difficult to be detected for the intrinsic limitation technique. In addition, PD patients enrolled in this study were cognitively normal, thus without specific cortical involvement. Furthermore, it is of interest that the diffuse hypoperfusion found in these two groups might be a result of hypoactivation secondary to hippocampal pathology in MCI and to basal ganglia pathology in PD patients.

Although many papers evaluated the role of brain perfusion SPECT and ¹⁸FDG PET in AD and other dementia categories [4-6], thus reaching definite and homogeneous conclusions, the data available on brain perfusion and metabolism in PD are more conflicting. Some authors described cortical areas of hypermetabolism as a feature of PD, while others observed cortical hypometabolic regions [20, 21]. Furthermore, to our knowledge wide literature in evaluating and comparing AD and PD perfusion data is not available, in particular considering the different impairment of Brodmann areas in these pathological categories.

Borghammer *et al.* [20] in an interesting paper using simulated data demonstrating that the described subcortical hypermetabolism in PD [22, 23] could be related to an artefact of biased global mean (GM) normalization and that low-magnitude, extensive cortical hypometabolism was best identified by alternative data-driven normalization methods. Therefore, the authors hypothesized that PD was characterized by extensive cortical hypometabolism without subcortical hypermetabolism and tested it on 3 independent samples of PD patients, by comparing SPECT CBF images of 32 early-stage and 33 late-stage PD patients with those of 60 matched-controls and ¹⁸FDG PET images of 23 late-stage PD patients with those of 13 controls. Three different normalization methods were used: GM normalization, cerebellum normalization and reference cluster normalization as previously described [24]. Standard voxel-based statistics (fMRIstat) and principal component analysis (SSM) were carried out as statistical analysis. Furthermore, a meta-analysis of all quantitative CBF and CMRglc studies in the literature in PD was performed. Voxel-based analysis with GM normalization and the SSM method provided a similar performance, being both able to detect decreases in small cortical clusters and concomitant increases in extensive subcortical regions. By using cerebellum normalization more widespread cortical decreases were observed but no

subcortical increase. Furthermore, the authors showed that in all comparisons, the Yakushev method, a cluster normalization method [24], identified nearly identical patterns of very extensive cortical hypometabolism. Finally, a meta-analysis of available literature investigating quantitative regional cerebral blood flow (CBF) evaluated by brain perfusion SPECT and glucose consumption (CMRglc) evaluated by ¹⁸F-DG PET, evidenced that global CBF and CMRglc values were decreased in PD. Basing on these results, Borghammer *et al.* [20] concluded that PD most likely presented widespread cortical hypometabolism, even at early disease stages, while extensive subcortical hypermetabolism was not a likely characteristic of PD.

In our study dementia patients, either with AD or FTD, presented specific regions of hypoperfusion compared with the other groups. On the other hand PD did not show any hyperperfused area comparing with the other groups of patients studied and the perfusion pattern we obtained in this group was similar to that of MCI subjects, less cognitively impaired with respect to overt dementia patients. The limitations of the study were that we included few PD patients (n = 19) because only subjects without cognitive impairment were enrolled in the study; also Lewy Body Dementia patients were excluded from this paper as we examined only very few subjects (n = 5).

Finally, it has to be mentioned that, even though the spatial and contrast resolution of FDG-PET is better than that of SPECT and there is a tendency in the current literature to perform brain PET despite perfusion SPECT, we performed perfusion SPECT in our patients. Reason is that we agree with Borghammer *et al.* [6] who stated that SPECT will continue to play a role for its wider availability and lower cost with respect to PET.

CONFLICT OF INTEREST

The authors confirm that this article content has no conflict of interest.

ACKNOWLEDGEMENTS

Declared none.

REFERENCES

- Palumbo B, Fravolini ML, Nuvoli S, *et al.* Comparison of two neural network classifiers in the differential diagnosis of essential tremor and Parkinson's disease by 123I-FP-CIT brain SPECT. *Eur J Nucl Med Mol Imaging* 2010; 37: 2146-3.
- Brajkovic LD, Svetel MV, Kostic VS, *et al.* Dopamine transporter imaging (123) I-FP-CIT (DaTSCAN) SPECT in differential diagnosis of dopa-responsive dystonia and young-onset Parkinson's disease. *Hell J Nucl Med* 2012; 15 (2): 134-8.
- Seifert KD, Wiener JI. The impact of Da Tscan on the diagnosis and management of movement disorders: A retrospective study. *Am J Neurodegener Dis* 2013; 2(1): 29-34.
- Tranfaglia C, Palumbo B, Siepi D, Sinzinger H, Parnetti L. Semi-quantitative analysis of perfusion of Brodmann areas in the differential diagnosis of cognitive impairment in Alzheimer's disease, fronto-temporal dementia and mild cognitive impairment. *Hell J Nucl Med* 2009; 12(2): 110-4.
- Herholz K. Perfusion SPECT and FDG-PET. *Int Psychogeriatr* 2011; Suppl 2: S25-31.
- Borghesani PR, DeMers SM, Manchanda V, *et al.* Neuroimaging in the Clinical Diagnosis of Dementia: observation from a Memory Disorders Clinic. *J Am Geriatr Soc* 2010; 58 (8): 1453-8.
- Palumbo B, Angotti F, Marano GD. Relationship between PET-FDG and MRI Apparent Diffusion Coefficients in brain tumors. *Q J Nucl Med Mol Imaging* 2009; 53 (1): 17-22.
- Palumbo B. Brain tumour recurrence: brain single-photon emission computerized tomography, PET and proton magnetic resonance spectroscopy. *Nucl Med Commun* 2008; 29 (8): 730-6.
- Palumbo B, Lupattelli M, Pelliccioli GP, *et al.* Association of (99m) Tc-MIBI brain SPECT and proton magnetic resonance spectroscopy ((1)H-MRS) to assess glioma recurrence after radiotherapy. *Q J Nucl Med Mol Imaging* 2006; 50(1): 88-93.
- Brockmann K, Reimold M, Globas C, *et al.* PET and MRI reveal early evidence of neurodegeneration in spinocerebellar ataxia type 17. *J Nucl Med* 2012; 53(7): 1074-80.
- McKhann G, Drachman D, Folstein M, *et al.* Clinical diagnosis of Alzheimer's disease: report of the NINCDS-ADRDA Work Group under the auspices of Department of Health and Human Services Task Force on Alzheimer's Disease. *Neurology* 1984; 34(7): 939-44.
- Blacker D, Albert MS, Bassett SS, *et al.* Reliability and validity of NINCDS-ADRDA criteria for Alzheimer's disease. The National Institute of Mental Health Genetics Initiative. *Arch Neurol* 1994; 51(12): 1198-204.
- The Lund and Manchester Groups. Clinical and neuropathological criteria for frontotemporal dementia. *J Neurol Neurosurg Psychiatr* 1994; 57(4): 416-8.
- Portet F, Ousset PJ, Visser PJ, *et al.* MCI Working Group of the European Consortium on Alzheimer's Disease (EADC). Mild cognitive impairment (MCI) in medical practice: a critical review of the concept and new diagnostic procedure. Report of the MCI Working Group of the European Consortium on Alzheimer's Disease. *J Neurol Neurosurg Psychiatr* 2006; 77(6): 714-8.
- Deuschl G, Bain P, Brin M. Consensus Statement of the Movement Disorder Society on tremor. *Ad hoc Scientific Committee. Mov Disord* 1998; 13 Suppl 3: 2-23.
- Hoehn M, Yahr MD. Parkinsonism: onset, progression, and mortality. *Neurology* 1967; 17: 427-42.
- Braak H, Braak E. Neurofibrillary changes confined to the entorhinal region and an abundance of cortical amyloid in cases of presenile and senile dementia. *Acta Neuropathol* 1990; 80(5): 479-86.
- Seeley WW, Crawford R, Rascofsky K, *et al.* Frontal paralimbic network atrophy in very mild behavioral variant frontotemporal dementia. *Arch Neurol* 2008; 65(2): 249-55.
- Seeley WW, Carlin DA, Allman JM, *et al.* Early frontotemporal dementia targets neurons unique to apes and humans. *Ann Neurol* 2006; 60: 660-7.
- Borghammer P, Chakravarty M, Jonsdottir KYr, *et al.* Cortical hypometabolism and hypoperfusion in Parkinson's disease is extensive: probably even at early stage. *Brain Struct Funct* 2010; 214(4): 303-17.
- Borghammer P. Perfusion and metabolism imaging studies in Parkinson's disease. *Dan Med J* 2012; 59 (6): B4466.
- Eckert T, Barnes A, Dhawan V, *et al.* FDG PET in the differential diagnosis of parkinsonian disorders. *Neuroimage* 2005; 26: 912-21.
- Huang C, Tang C, Feigin A, *et al.* Changes in network activity with the progression of Parkinson's disease. *Brain* 2007; 130: 1834-46.
- Yakushev I, Hammers A, Fellgiebel A, *et al.* SPM-based count normalization provides excellent discrimination of mild Alzheimer's disease and amnesic mild cognitive impairment from healthy aging. *Neuroimage* 2009; 44: 43-50.