

## Skull Base Surgery of the Temporal Bone

Amy L. Rutt<sup>1</sup>, Mary J. Hawkshaw<sup>2</sup> and Robert T. Sataloff<sup>\*,2</sup>

<sup>1</sup>Department of Otolaryngology – Head and Neck Surgery, Huron Valley-Siani Hospital, Detroit Medical Center/Wayne State University, 1 William Carls Drive, Commerce, MI 48382, USA

<sup>2</sup>Department of Otolaryngology – Head and Neck Surgery, Drexel University College of Medicine, 1721 Pine Street, Philadelphia, PA 19103, USA

**Abstract:** *Objectives:* The aim of this study was to review major temporal bone cases performed by one surgeon, and to highlight pitfalls and progress in the surgical management of previously “unresectable” neoplasms.

*Design:* Retrospective case series review.

*Setting:* Tertiary referral center.

*Participants:* Nine patients who underwent total en bloc temporal bone resection for malignancy of the ear and temporal bone.

*Main Outcome Measures:* Histories, surgical techniques, postoperative complications and outcomes, and changes in the approach to total en bloc resection of the temporal bone were analyzed.

*Results:* With combinations of extensive surgery, radiation therapy, and chemotherapy, some patients with aggressive skull base neoplasms once deemed “unresectable” survive and appear free of disease. Total en bloc temporal bone resection was developed over 25 years ago. Additional experience has led to significant modifications in the technique, some of which have not been published previously.

*Conclusion:* The morbidity and mortality associated with malignancy of the temporal bone may justify extensive surgery. In the hands of an experienced skull base team, total temporal bone resection can be performed successfully. This approach offers hope for survival in some patients with malignancy of the temporal bone.

**Keywords:** Skull base surgery, temporal bone resection, cancer of the temporal bone, temporal bone malignancy.

### INTRODUCTION

Temporal bone malignant neoplasms remain particularly challenging problems for otolaryngologists. Traditionally, surgical excision of the temporal bone has been subtotal. Consequently, it has been hampered by transgression of tumors and incomplete excision. The emergence of skull base surgery as a distinct discipline that incorporates neurotological, neurosurgical, and head and neck surgical skills has opened new frontiers in surgery of anatomically complex areas of the skull base. In an effort to improve upon treatment results, a new approach to temporal bone resection was devised and performed first in the anatomy laboratory, then in humans. In 1984 Graham, Sataloff, Kemink *et al.*, published the first report of total en bloc resection of the temporal bone and carotid artery [1]. Two additional cases were performed by the author (RTS) in 1984, and others have been operated upon at our center since that time. This experience and additional cadaver dissection have resulted in modifications of the technique and recognition of additional pitfalls.

Accurate assessment and treatment planning for temporal bone malignancies are dependent on CT scanning of the bone erosion, and MR imaging of soft tissue involvement. Biopsy and clinical staging based on involvement of the ear, surrounding structures, and lymph nodes are required, of course. However, preoperative assessment often underestimates tumor extent. Though Leonetti *et al.* [2], found fairly good correlation between CT scanning, MR imaging, and intraoperative findings, they emphasized critical exceptions in their series of 26 patients. Three patients had infratemporal fossa extensions without radiographic evidence, only 8 of 16 patients with posterior extension into the mastoid were identified, and superior extension was underestimated in nine patients. Surgically proven otic capsule involvement was not seen radiographically in four patients, and carotid canal extension was found in six patients who were believed to be clear in this area on MR imaging. These patients did poorly because their disease was more advanced. The only radiographic overestimation occurred in the otic capsule in which only one of three patients had actual invasion. Other studies also have reported difficulty estimating tumor extent with radiographs [3, 4].

All treatment for temporal bone cancer is based on whether the carcinoma has extended beyond the external auditory canal. In the development of surgery for temporal

\*Address correspondence to this author at the Department of Otolaryngology – Head and Neck Surgery, Drexel University College of Medicine, 1721 Pine Street, Philadelphia, PA 19103, USA; Tel: (215) 732-6100; Fax: (215) 545-3374; E-mail: RTSataloff@PhillyENT.com

bone carcinoma, larger operations have evolved as surgical techniques for dura repair, carotid bypass, and reconstruction have developed. The three operations utilized include: (1) piecemeal removal, (2) subtotal total temporal bone resection (STBR), and (3) total temporal bone resection (TTBR) [5, 6].

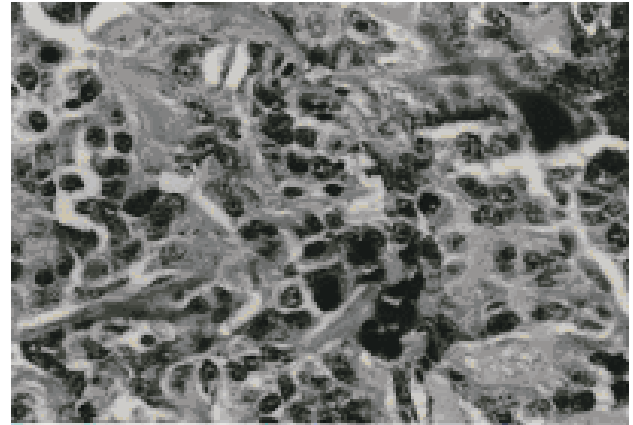
This paper focuses on the TTBR, which means complete removal of the petrous bone and related neural and vascular structures. The basic technique was published by Sataloff *et al.* in 1987 [7] and included important modifications of the technique described in the original paper [1]. Most of the techniques described in that article are still the standard, but there have been important modifications and refinement. The goal of surgery is en bloc resection of the temporal bone “without seeing tumor”[7]. This procedure is appropriate for fully informed patients with tumors traditionally considered unresectable and lethal, who have no metastatic disease, are in good health, and are willing to accept the formidable morbidity and mortality to achieve a chance of cure. Occasionally, there also may be a role for subtotal temporal bone resection, as noted in cases 8 and 9 below.

Using traditional approaches less extensive than TTBR, it may be extremely difficult, or impossible, not to violate a tumor margin, especially if tumor size is underestimated by imaging studies. A partial mastoidectomy to expose the sigmoid sinus, for example, may expose air cells in continuity with the middle ear or mastoid tumor. Carotid artery dissection necessarily comes in close contact with the anterior extension of middle ear tumors. Even with a large resection, some piecemeal resection may be necessary, especially in the occipital condyle, clivus, carotid canal, or cavernous sinus [8, 9]. The senior author (RTS) has made some previously unreported changes in his protocol: (1) the procedure has been extended to include the cavernous sinus and clivus in selected cases; (2) preoperative carotid artery screening is performed with temporary balloon occlusion rather than a Silverstone clamp; and (3) the carotid artery is occluded radiographically below the ophthalmic artery within a few days before the definitive resection, and (4) carotid artery bypass grafting, if necessary, should be from the contralateral internal carotid artery to the ipsilateral internal carotid artery with the graft passing across the head, removing this life-sustaining graft from the surgical field. Because much of the external carotid artery system is sacrificed during this operation, and because substantial manipulation is required to extract the temporal bone, risk to a graft based on the ipsilateral carotid artery is excessively high.

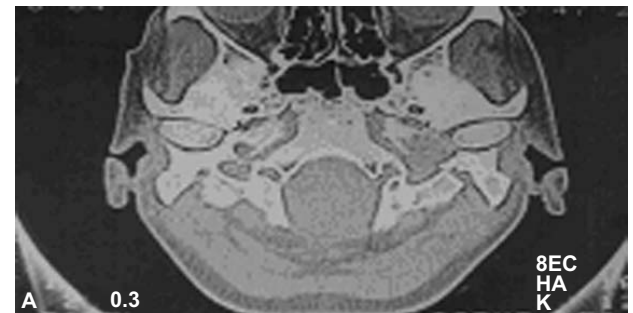## REVIEW OF CASES

The originally published temporal bone resection cases included two patients; one with squamous cell carcinoma and one with extensive basal cell carcinoma [1]. The quality of life following the procedure was adequate, and the cosmetic deformity was acceptable. Longer follow-up was deemed necessary to determine the value and overall impact of the approach to cancer of the temporal bone on disease free interval and patient survival, but these cases were not published until five years after the surgery had been performed; and the patients were free of tumor [1].

The first patient after the original publication (case 1) treated by the author (RTS) with total temporal resection was a 37-year-old female, who developed a painful external auditory canal polyp. Biopsy revealed osteogenic sarcoma (Fig. 1A). CT scan (Fig. 1B) confirmed malignant destruction of the temporal bone, but metastatic workup revealed no evidence of the lesion outside the primary site.



**Fig. (1A).** Biopsy of the external auditory canal “polyp” shows high grade osteogenic sarcoma.

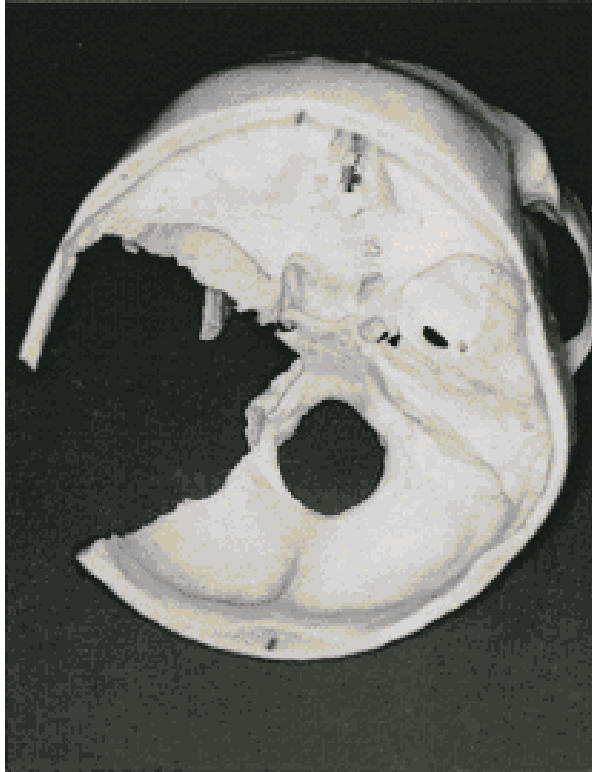


**Fig. (1B).** Preoperative CT scan.

The patient underwent total temporal bone resection (Fig. 1C). The last bone cut transgressed tumor adjacent to the cavernous sinus, but this tumor was recognized and resected immediately. The final pathologic evaluation revealed no evidence of tumor in the margins at any other site. Facial nerve grafting was performed using the greater auricular nerve placed between the brainstem and the distal nerve segments.

The postoperative course was complicated by pneumonia that was followed by a lung abscess requiring chest tube drainage. A persistent cerebrospinal fluid rhinorrhea occurred and was due to total removal of the bony Eustachian tube with closure by muscle packing alone. This leak was repaired transorally by dividing the soft palate, everting the Eustachian tube mucosa, and oversewing the opening of the Eustachian tube in the nasopharynx. Meningitis also occurred and responded to medical therapy, although a stroke resulted in left arm weakness.

After the hospital discharge, the patient was followed with bone scans, MRI, and CT scans every two months. She

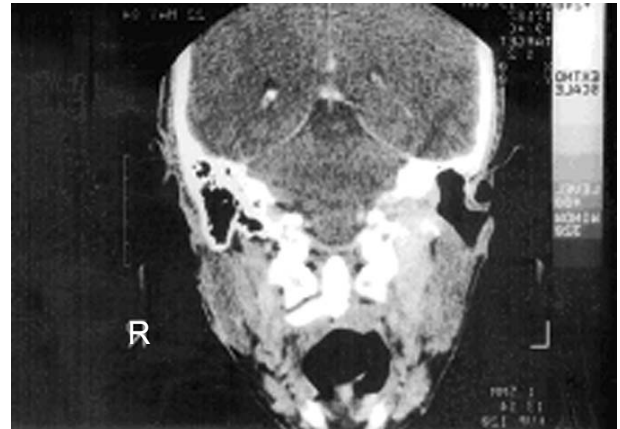


**Fig. (1C).** Skull showing the bone cuts and segment of the skull base removed for TTBR.

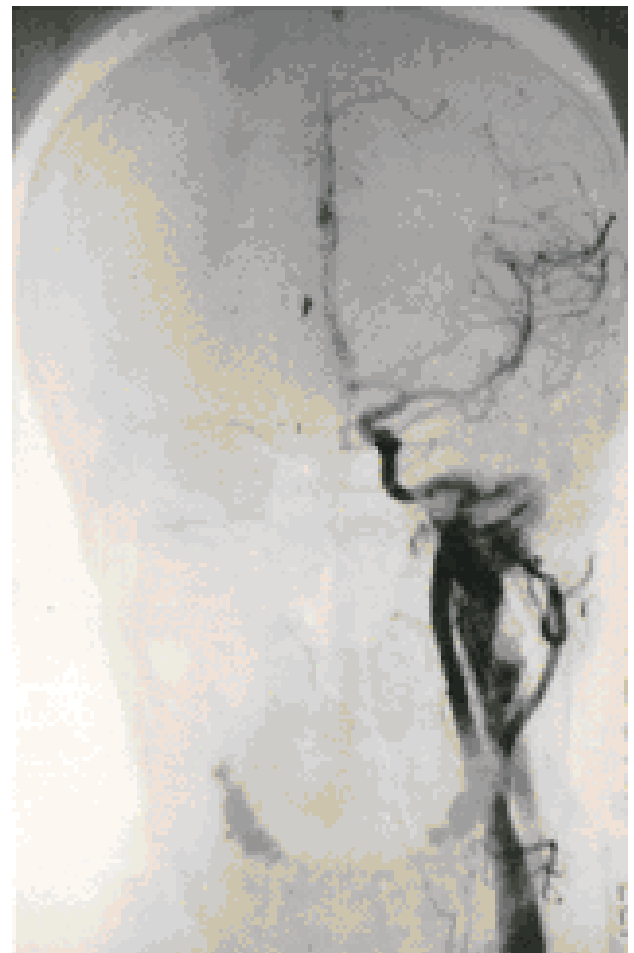refused radiation and chemotherapy to which she had agreed preoperatively. Eleven and one-half months after surgery, there was regional recurrence of tumor. She underwent resection of the ascending ramus of her mandible and all gross tumor. This included resection of the facial nerve graft previously placed, but no further attempt was made to regraft the nerve. Surgery was followed by 6,900 rads of radiation therapy [10]. She refused chemotherapy and eventually died of distant metastatic disease.

Case 2 is a 54 year old male who had undergone resection for a left glomus jugulare tumor seven years prior to his current surgery and who is the only patient on whom this procedure has been performed for histologically benign disease. His facial nerve had been injured in the mastoid region at the time of his original operation, and the previous surgeon had reportedly attempted facial nerve grafting as a secondary procedure. In the several months preceding his current surgery, he had developed spontaneous hemorrhage from his left ear and paralysis of cranial nerves IX, X, and XI. His CT scan and angiogram revealed recurrent glomus jugulare with intracranial extension (Fig. 2A, B). The tumor extended from the cavernous sinus to below the level of the first cervical vertebrae. Medially, it crossed the midline anterior to the foramen magnum and involved the contralateral brainstem.

The patient underwent surgery that was initially planned as a total temporal bone resection with preservation of the sixth cranial nerve. The procedure was modified from the original description by occluding the carotid artery



**Fig. (2A).** CT scan of Case 2 reveals recurrent glomus jugulare tumor (arrows).



**Fig. (2B).** Angiogram of Case 2 shows a large recurrent glomus tumor.

intracranially below the ophthalmic artery rather than intratemporally. His intra-operative course was complicated by massive cerebral swelling following occlusion of the venous sinuses. This necessitated a change in approach because deep brain retraction was rendered unsafe. It also necessitated partial temporal lobectomy and partial

cerebellar hemispherectomy (silent areas). A portion of the tumor approximately three cubic millimeters in size was left surrounding a brainstem draining vein. It was felt unsafe to remove it even with the laser because of unacceptable risk to brainstem vasculature. Postoperative irradiation for minimal residual tumor was planned. The patient awakened within two hours of surgery and recovered well. His principle complication was a salivary fistula. This was repaired at the bedside. He received radiation therapy (6,000 rads) without complication.

Lessons learned by Sataloff and Myers from the first two cases resulted in technical modifications [10-12]. A CSF leak in Case 1 was due to total removal of the bony Eustachian tube and closure by muscle packing alone. This complication has been avoided by suturing the Eustachian tube transcranially during the primary procedure if all of the Eustachian tube bone has been removed. The cartilaginous Eustachian tube is not strong enough to support the muscle packing independently.

Case 1 also developed a stroke, probably due to embolization of clot within the occluded internal carotid artery. This led to the change in procedure order described initially: intracranial occlusion of the carotid at the beginning of the procedure (now prior to the procedure). Other possible sources of stroke included retractor ischemia, and every precaution must be taken to avoid unnecessary pressure or prolonged retraction.

Case 2 developed a salivary fistula. He collected fluid under his flap which was thought initially to be a CSF leak. The tension caused by the fluid collection appeared to place excessive stress on the ear canal closure. The fluid was drained by aspiration, and tests revealed that it was saliva, not CSF. Although it was treated by continued aspiration and pressure, the ear canal closure broke down and leaked saliva. This was repaired at the bedside, and no further difficulty was encountered [11].

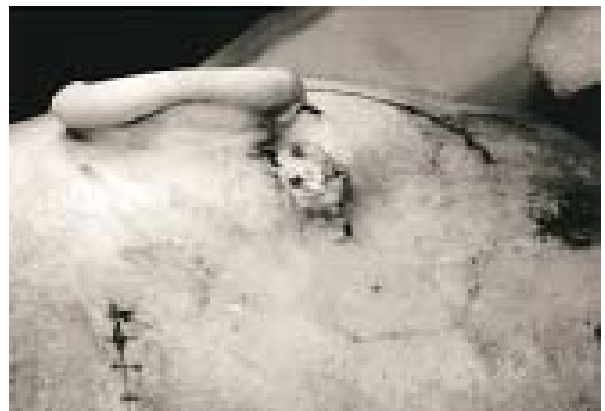Despite vigorous pulmonary toilet, cases 1 and 2 developed pneumonia. Although these patients are well ventilated while on the respirator, they aspirated around their tracheotomy cuffs because of their lower cranial nerve paralysis. As tracheotomy cuffs do not prevent aspiration, frequent suction, coughing, deep ventilation, and upright positioning are the primary methods of preventing this problem. Because of cranial surgery and lumbar drainage, the patients cannot be turned down for chest percussion and postural drainage. Hence, the senior author has been more aggressive in using fiberoptic bronchoscopy early and often for pulmonary toilet, and routinely performs cricopharyngeus myotomy at the time of the original procedure. More recently we have also performed thyroplasty at the initial sitting, with the understanding that revision with arytenoid adduction or arytenoidopexy may be required in the future, when the patient can be operated upon under local anesthesia.

In addition, brain injury may be caused by spinning a cotton paddy in the drill, and may be prevented by shielding the shaft of the burr with the plastic cover from an intravenous catheter or with fine tubing when it is used between the brainstem and the temporal bone.

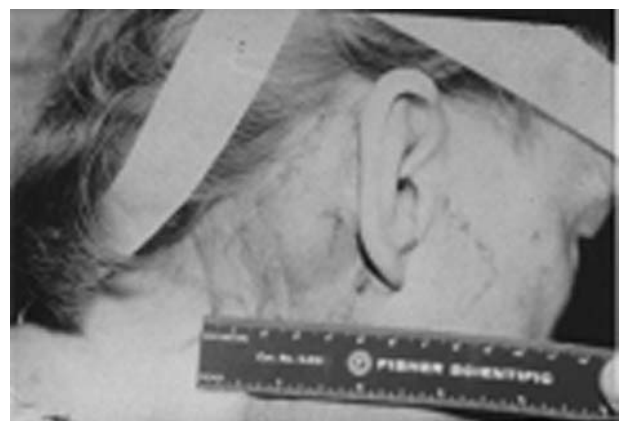Seizures are a potential problem, but antiseizure medication is not used routinely. Rather it is prescribed if seizures occur or if EEG shows seizure foci. Meningitis is another potential complication. Although neither case 1 nor case 2 demonstrated clinical signs of meningitis, both eventually had positive cultures from their lumbar drainage collections. They were treated with antibiotics on the basis of the cultures and developed no clinical signs of infection [11].

Case 3 was a 62 year old female in whom squamous cell carcinoma of the right external auditory canal developed in 1982. Initially, before being referred to our center, she had undergone 6,000 rads of radiation therapy. Thereafter, she had had a right radical neck dissection for persistent tumor high in the neck. The surgeon reported, "unresectable tumor at the skull base". The neck mass recurred, and she was treated with an additional 6,000 rads of radiation therapy (total 12,000 rads). At the end of this treatment, she was referred to the author (RTS) for further management. At that time, she had a 2 cm ulcer over her mastoid bone surrounded by radiation reaction (Fig. 3A, B). Multiple biopsies revealed squamous cell carcinoma. Extensive work-up, including open liver biopsy, revealed no evidence of spread outside the primary site. An angiogram revealed adequate arterial flow from the left internal carotid artery, and CT scan showed tumor in the pneumatized spaces (Fig. 3C).

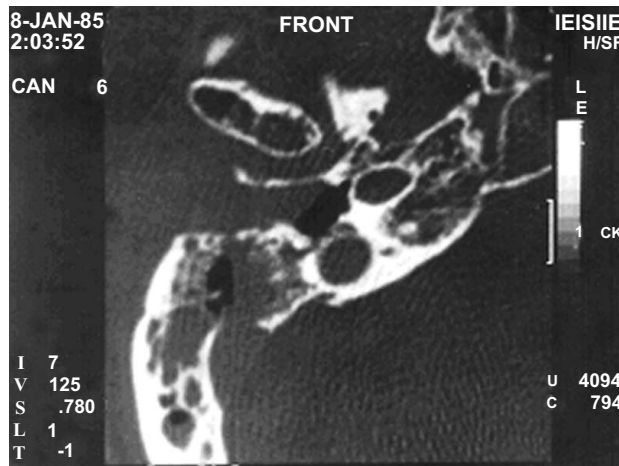
(A)



(B)



**Fig. (3).** (A, B) 2 cm malignant ulcer of the mastoid surrounded by radiation reaction.



**Fig. (3C).** CT scan reveals persistent squamous cell carcinoma of right external auditory canal, middle ear, and mastoid with a defect in the sigmoid plate.

In 1985, she underwent a total temporal bone resection. Her postoperative course during the first two weeks was excellent, and she was responsive within the first 24 hours and was alert and able to mouth words within the first week after surgery. Early venography revealed thrombophlebitis in her legs; this was treated with a Greenfield filter without complications. Temperature elevation within the first week was evaluated with early bronchoscopy, and pneumonia was not a problem. The patient’s mental status continued to improve for two weeks. Her first lumbar drain was kept in place for one week. A second lumbar drain was placed immediately and kept in place for an additional week.

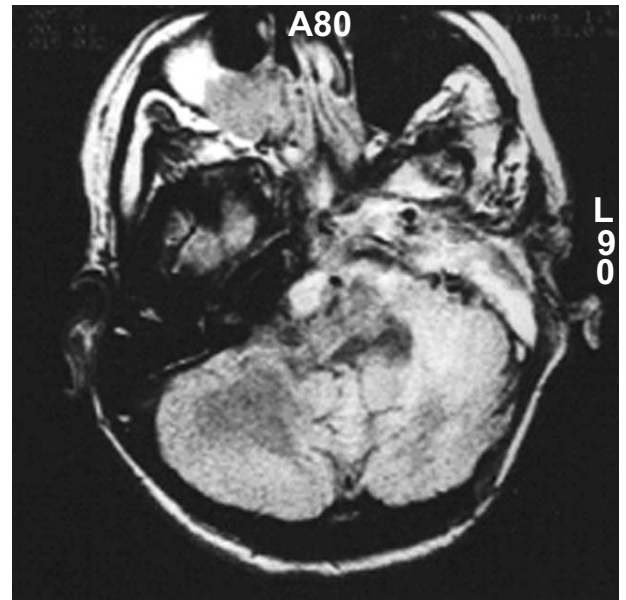
Because of the patient’s excellent progress, her fluid restriction was relaxed slightly and lumbar drain removed. Within the next 48 hours, hydrocephalus and marked cerebral edema developed resulting in left hemiplegia. A ventriculoperitoneal shunt was placed, but her neurological level remained depressed. Six months following surgery, she developed metastatic tumor low in the posterior triangle of the neck. She experienced a progressive downhill clinical course and died of distant metastases 14 months following surgery.

Case 4 was a 39 year old female with a six year history of left otalgia, hearing loss, positional vertigo, globus sensation on the left side, and voice change with marked loss of range with intermittent hoarseness. She also had intermittent velopharyngeal insufficiency with nasal regurgitation and intermittent cough. Her symptoms progressed gradually over the six year period. She had seen several physicians, and had been treated with symptomatic therapy, surgery for her contralateral sphenoid sinus disease, and left myringotomy and tube placement.

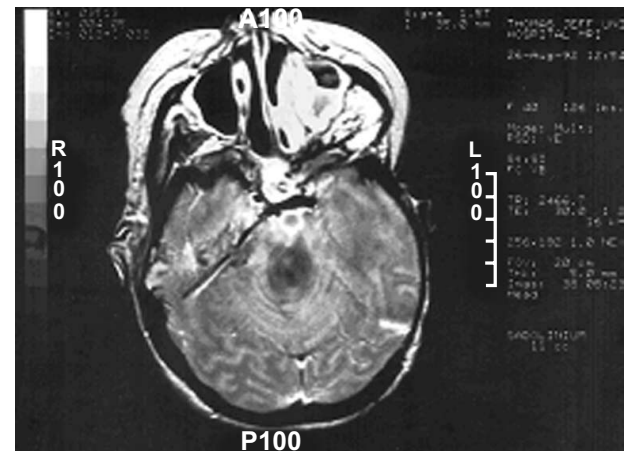
Otoscopic examination was normal on the right; the left ear had a myringotomy tube in the anterior inferior quadrant of the tympanic membrane. Her gag reflex was reduced on the left. She had somewhat decreased palatal motion bilaterally, but marked palatal paresis on the left. Her nasopharynx contained a mass on the left, extending to the midline and including the region of the torus tubaris. Laryngeal examination revealed left vocal fold paralysis.

Although her compensation was unusually good, her vocal range was markedly diminished. The mass was biopsied.

The pathology report indicated that the tumor was a high grade mucoepidermoid carcinoma. CT and MRI revealed a destructive lesion extending just beyond midline of the nasopharynx and involving the left internal carotid artery (Fig. 4A). The tumor appeared to have invaded the skull base and extended through the foramen lacerum, and the posterior aspect of the cavernous sinus (Fig. 4B). There was invasion of the anterior portion of the petrous apex. Angiogram revealed no tumor blush. The diagnosis was changed after review to adenocarcinoma of the skull base.



**Fig. (4A).** Tumor approaching the midline



**Fig. (4B).** Tumor invasion of skull base, foramen lacerum, and posterior aspect of cavernous sinus

This patient’s tumor traditionally was considered unresectable. Her operation took 30 hours and involved resection of her skull base, cranial nerves VI through XII, her entire temporal bone, part of her neck, pharynx, the lower half of her cavernous sinus, the lateral wall of her sphenoid sinus, and the clivus to the midline. This was the

largest skull base resection performed to the best of our knowledge, and it was an extension of the procedures published previously [1, 7]. This procedure has not been reported, and the technique for partial cavernous sinus resection we believe to be new. It is described in case 6 below.

Preoperatively, the patient had a Silverstein clamp placed with subsequent development of a right facial paresis and aphasia the day after occlusion, as she was being placed on the stretcher to go to the operating room, she suffered a stroke due to embolization of a clot from her cervical carotid artery. She had left frontoparietal craniotomy and carotid artery ligation just proximal to the PCA and her aphasia and paresis improved significantly. Subsequently, she suffered deep depression for several weeks while trying to determine whether or not to undergo the full surgery in an attempt to stave off the mortality of this aggressive tumor. She elected to proceed with the surgery.

This procedure, included tracheotomy, Frost stitch, cricopharyngeal myotomy, posterior fossa and middle fossa craniotomy, total en bloc resection of the temporal bone, resection of lateral process of C-1, partial resection of the nasopharynx; sphenoidotomy and partial resection of the cavernous sinus; resection of the superior petrosal, transverse, and inferior petrosal sinuses and jugular bulb; partial resection of the clivus, partial neck dissection, fascia lata dural graft, facial nerve interposition graft, resection of cranial nerves VI through XII, temporalis muscle flap, resection of the skull base to 4mm of the foramen magnum, partial mandibulectomy infratemporal fossa resection, bronchoscopy and myringotomy. Extraordinary bleeding was encountered intraoperatively from the basilar venous system along the clivus. This was difficult to control because it was unsafe to retract or put pressure on the anterior portion of the brainstem. Blood loss was 47 units before the operation was completed and the bleeding was controlled.

During the first three weeks of the patient's postoperative period, she was maintained in the intensive care unit. The surgical sites healed well.

However, during the early postoperative period, the patient had fever spikes that were evaluated carefully. Her neurological status was suboptimal. She blinked on command and was able to move her legs and withdraw her upper extremities to pain. Postoperative MR initially showed an infarct about 1 cm deep in the anterior brainstem region without damage to the more superficial brainstem adjacent to the clivus. This area was deemed responsible for her neurological impairment. Subsequently, the patient's neurologic status gradually worsened, and she had fluid drainage that appeared to be infected from the lumbar spine drain. Antibiotics were adjusted. The patient had positive cultures for methicillin resistant staphylococcus aureus (MRSA) in the oropharynx, nasopharynx, and spinal fluid. The patient's state one month postoperatively was deemed consistent with a "coma vigil state" or the locked-in syndrome. The patient was maintained on IV antibiotics for MRSA for a period of six weeks. She had persistent mental status changes and spiking temperatures. She had undergone radiation treatment totaling 6,500 rads external beam radiation postoperatively. During radiation therapy, her neurologic status changed minimally.

Brain MR scans carried out at intermittent periods during the hospital stay showed increasing areas of infarction involving not only the immediate surgical area, but also extending deeper into the posterior fossa. The patient was accepted for placement into a rehabilitation hospital. There was no improvement in her mental status. The patient died from pneumonia one year and seven months following surgery. She had no evidence of recurrent or residual tumor.

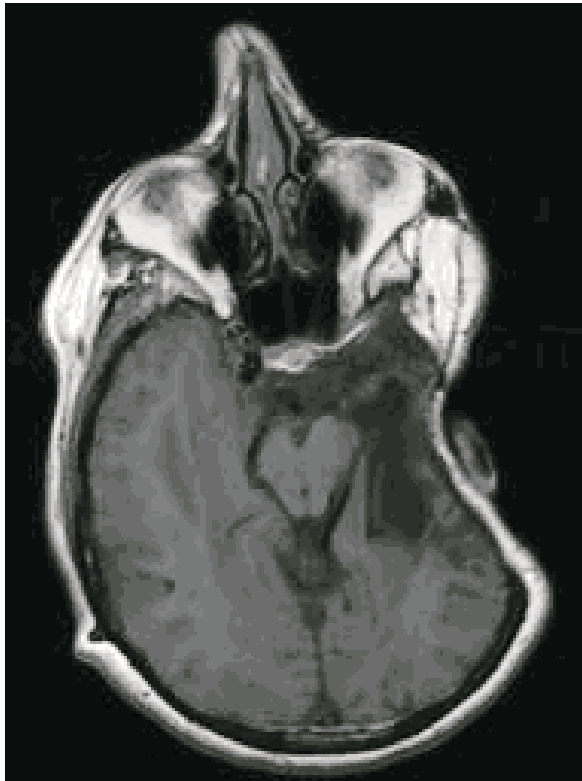Case 5 is a 25 year old female with complaints of chronic left ear pain and fullness over sixteen months. During that time period she was pregnant and delivered a healthy boy. She also complained that she heard her heartbeat in her left ear almost constantly. She had noticed weakness in her left shoulder and upper arm. Her complaint of dysphonia and dysphagia had prompted her referral to the author (RTS).

Examination revealed a left hypomobile eardrum with serous otitis media and retraction. Her heartbeat tinnitus seemed to be less audible to her with carotid compression. Audiogram revealed a conductive hearing loss in the left ear and normal hearing in the right ear. Examination of the nasopharynx showed a midline mass extending from the skull base nearly to the end of the soft palate, more prominent on the left but crossing the midline. She had palatal deviation to the right and tongue deviation to the left with atrophy. Cranial nerves IX-XII on the left were very paretic or paralyzed. Her swallowing evaluation revealed pooling of liquids in the left piriform sinus. There was evidence of slight penetration without aspiration. Stroboscopy revealed left vocal fold paralysis with complete failure of glottic closure.

CT of the temporal bones with and without contrast revealed a multilobulated lesion that extended from the nasopharynx into the left carotid space, areas of bony expansion and erosion, and with extension into the left hypotympanum. MRI of the brain and IAC's with and without contrast revealed a multilobulated mass in the left jugular fossa. Transtympanic biopsy confirmed a diagnosis of Grade 2 chondrosarcoma. This large tumor covered a vertical distance of approximately 6 cm extending from the level of the horizontal portion of the facial nerve in the ear, inferiorly to approximately the third cervical vertebrae. The tumor extended posteriorly from an area just posterior to the transverse process of C2, and anteriorly to an area just anterior to the posterior wall of the temporomandibular joint.

Neck dissection and parotidectomy were performed to approach the tumor from below, and the carotid artery was ligated in the neck. A limited mastoidectomy was performed to visualize and determine the superior extent of the tumor. Sarcoma was found to have extended from the hypotympanum underneath the facial nerve, and to have invaded the mastoid air cells low on the left. The tumor extended through the obturator foramen and was in contact with the horizontal portion of the facial nerve. The tumor was visualized, but not disturbed. A wide craniotomy involving the posterior fossa and middle fossa was extended anteriorly, and the carotid artery was clipped below the ophthalmic artery. The tumor approached the foramen magnum and filled the area between C-2 and the skull base, extending to the deep layer of the deep cervical fascia and involving the carotid sheath. It extended anteriorly into the infratemporal fossa and invaded the temporomandibular joint from the temporal bone. There

was tumor extending through the jugular foramen intracranially. Simultaneous intracranial and extracranial visualization permitted the bony incision adjacent to the foramen magnum, between C-2 and the skull base, to be made and extended anteriorly using a chisel. This bony incision was carried to the skull base near the ptergoid plate. The next bony incision was made from the temporomandibular joint across the middle cranial fossa floor to a point in the superior petrosal sinus approximately .5 cm posterior to the cavernous sinus. A vertical incision (all with chisels) from the middle fossa floor to the lateral skull base incision near the pterygoids was then made. The final incision was made through the anterior portion of the posterior fossa aspect of the temporal bone, including the inferior petrosal sinus. Gross total tumor resection was accomplished (Fig. 5). A facial nerve graft was intended; however, shortly after the temporal bone and skull base resection, cerebellar swelling was noted and the surgery was concluded rapidly. This patient, a Jehovah's Witness, required the operation to be performed "bloodless", without the option of transfusion or use of a cell saver.



**Fig. (5).** MRI showing a portion of the area of resection, approximately six months following surgery.

During the patient's hospital stay, she experienced multiple complications, including left vocal fold paralysis, left facial paralysis, and persistent dysphagia that delayed reinstatement of an oral diet.

Two months later she underwent direct microlaryngoscopy with left vocal fold injection. Six months later, she had undergone left arytenoidopexy, thyroplasty,

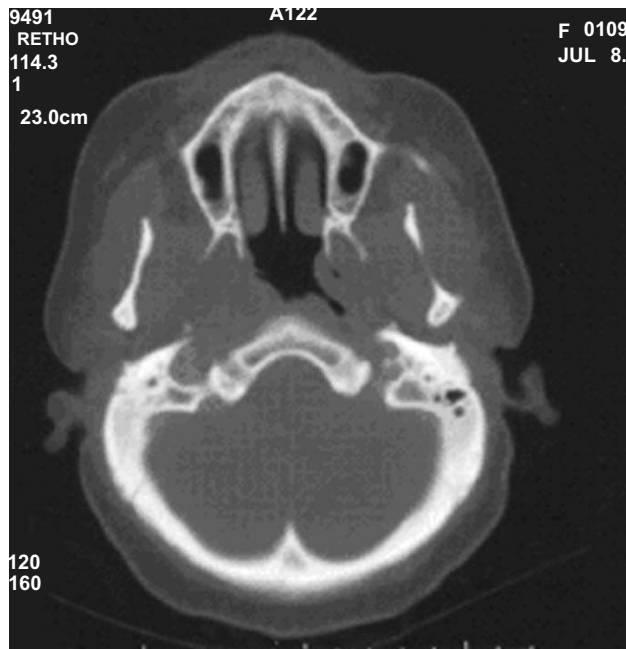
cricothyroid subluxation, and a tracheotomy scar revision with excision of an epithelial tract. She had been able to maintain oral nutrition. One year later she underwent a left revision thyroplasty for treatment of dysphonia and aspiration. Three years after the initial surgery a left facial sling with gor-tex implant was performed for facial paralysis. Approximately two weeks later she suffered a seizure and the sling was released with return of her preoperative facial contour. A revision of the left facial sling was performed two months later. Four years following her resection, her voice was strong and she was eating a normal diet. A facial reanimation on the left using a facial sling, left rhytidectomy, left revision vocal fold medialization using fat were accomplished. More than five years after surgery, she is doing well, performing all of her normal activities and has remained free of tumor.

Case 6 is a 43 year old female with a history of nasopharyngeal squamous cell carcinoma that had been resected in 1999. She did well after resection and a course of radiation therapy. Three years later, she developed increasing frontal and temporal headaches and right facial pain. MRI revealed recurrent tumor. She presented to the senior author (RTS) complaining of right sided hearing loss and aural fullness which she said had been present for 22 years. She had had two sets of myringotomy tubes. She also had had a cholesteatoma of her right ear been treated with three partial mastoidectomies and one radical mastoidectomy for recurrence. She also complained of recent right otalgia, which she described as "sharp, stabbing pain" lasting for a couple of seconds. She had occasional right-sided tinnitus described as ringing/swishing. For several years she had had lightheadness occurring several times per week. Recently, she had been experiencing loss of balance and found herself leaning to the right, although she had not fallen.

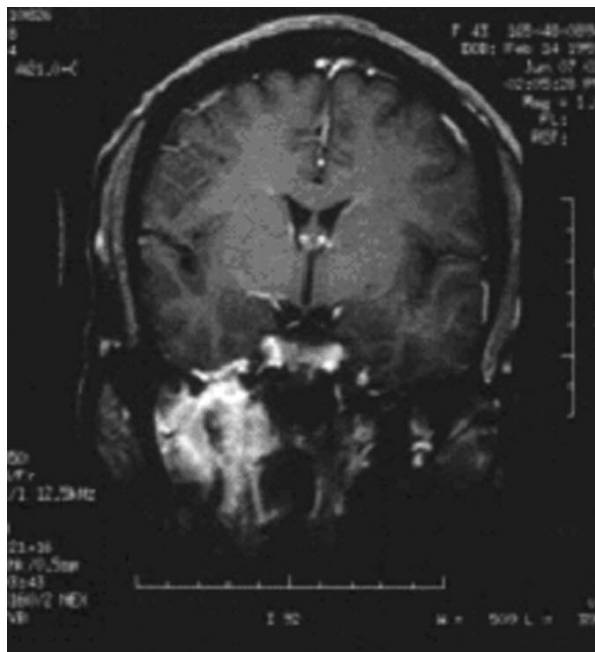
Examination revealed a small right mastoid cavity. An audiogram revealed right-sided moderate to severe mixed hearing loss. Romberg (with eyes closed) produced a fall to the left. She had trismus. There was a palpable right nasopharyngeal mass that extended to the upper pole of her tonsil.

CT of the skull base and upper thorax revealed a right nasopharyngeal tumor extending from the tonsillar pillar into the parapharyngeal space and eroding through the foramen ovale (Fig. 6A), as seen on prior MRI, and obstructing the right Eustachian tube. MRI (Fig. 6B) demonstrated an increase in size and a decrease in definition of the right parapharyngeal space compared with previous studies, suggesting aggressive neoplasm. MRI of the neck showed increase in size of the inferior aspect skull base mass, and a lesion in the mandible to the left of the midline of uncertain etiology, but possibly representing a neoplasm. Whole body bone imaging showed two abnormal foci of activity in the left side of the mandible worrisome for metastatic disease.

Her preoperative diagnosis was poorly differentiated squamous cell carcinoma of the nasopharynx, oropharynx, skull base, temporal bone, middle cranial fossa floor and involving the inferior aspect of the cavernous sinus. She underwent a middle and posterior fossa craniotomy; ligation of the internal and external carotid arteries, transverse sinus, and partial ligation of the cavernous sinus; total temporal



**Fig. (6A).** Preoperative CT showing partial destruction of the right side of the skull base.



**Fig. (6B).** MR showing portion of the tumor.

bone, skull base, and right venous outflow system resection; partial mandibulectomy, parotidectomy, neck dissection, partial pharyngectomy, and facial nerve graft. As with all the TTBR, the craniotomy permitted a large, curvilinear dural incision that started over the temporal lobe and finished in the posterior fossa posterior to the sigmoid sinus, permitting division of the tentorium to provide broad exposure of the skull base. Care is taken to divide the transverse sinus anterior to its junction with the vein of Labbé whenever possible; in an effort to preserve venous drainage of the

temporal and parietal lobes. She also underwent percutaneous endoscopic gastrostomy, tracheotomy, tarsorrhaphy, and lumbar drain placement. The operating time was approximately 24 hours. A Greenfield filter had been placed pre-operatively. The technique used for partial cavernous sinus resection in this case and case 4 was novel. Initially, complete cavernous sinus resection had been planned. Intraoperative findings in both patients revealed tumor attached to the cavernous sinus inferiorly, but without definite invasion into the sinus. In each patient, the cavernous sinus was elevated off bone medially using a Freer elevator. It was then possible to place a straight Kelly clamp longitudinally along the sinus at about its vertical midportion, resect the inferior one half of the sinus, and suture the sinus. This allowed resection of the portion involved with tumor that had invaded through the middle fossa floor, but the nerves within the sinus that control the eye (which run in the superior portion of the sinus) were preserved, reducing dramatically the morbidity of this portion of the procedure.

The patient had a complicated clinical course, but her complications were manageable. She recovered from pneumonia. A corneal ulcer developed despite tarsorrhaphy and aggressive eye care, but it healed. She also had a CSF leak and a heel ulcer postoperatively, as well as a small area of breakdown on her helix. One month after resection she was brought back to the operating room for fever spikes and a collection of fluid in the right infratemporal fossa. A small area at the superior aspect of her right neck incision was opened. Using blunt dissection, her abscess cavity was opened and drained. Two months following resection, she developed CSF otorrhea, and an oral cutaneous fistula. The patient underwent right posterior and middle fossa craniotomy with removal of bone plates, repair of CSF leak, revision right external auditory canal occlusion, and right external ear (helix) debridement for an ulcer. She also had an oral cavity debridement, curettage of pharyngeal fistula, and FESS with right maxillary antrotomy.

Four months later, MRI of the brain revealed less mass effect and shift of midline structures when compared to prior studies. The large fluid-containing areas within the right middle cranial fossa had decreased considerably, and as a result there was concavity of the right side of her skull. The area of the apparent mass lesion, which contained a large amount of hemorrhage, had decreased in size. There was diffuse meningeal enhancement, which included the cervical canal. The symmetric and diffuse fashion of the enhancement suggested it was related to meningeal fibrosis. She never regained acceptable function and expired about one year after surgery.

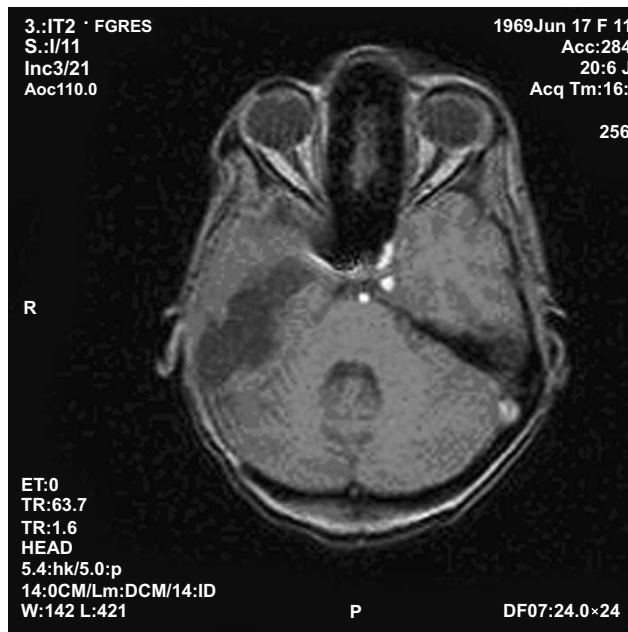
Case 7 is a 36 year old female who complained of right tinnitus and diminished hearing, with constant otalgia and aural stuffiness. She had episodes of dizziness with changes in position such as bending over or changing from sitting to standing position. Her right tympanic membrane was immobile. Weber lateralized to the right. Rinne (mastoid) revealed air equal to bone conduction on the right. Her palate deviated slightly to the left. Gag reflex was diminished on the right.

MRI and CT of the brain and internal auditory canals revealed a right skull base tumor measuring at least 5 cm



with a small area of extra-axial extension into the right posterior fossa over the cerebellar hemisphere (Fig. 7A, B). There was no evidence of intracerebral metastasis, mass effect or vasogenic edema. CT demonstrated an aggressive lesion that eroded the right mastoid air cells and petrous region of the temporal bone. The ossicles were intact but surrounded by soft tissue. CT and MRI of the neck showed a 3.3 cm x 2.2 cm mass lesion centered just below the right skull base, with erosion of the right temporal bone. The tumor was a chondrosarcoma of the skull base.

(A)



(B)

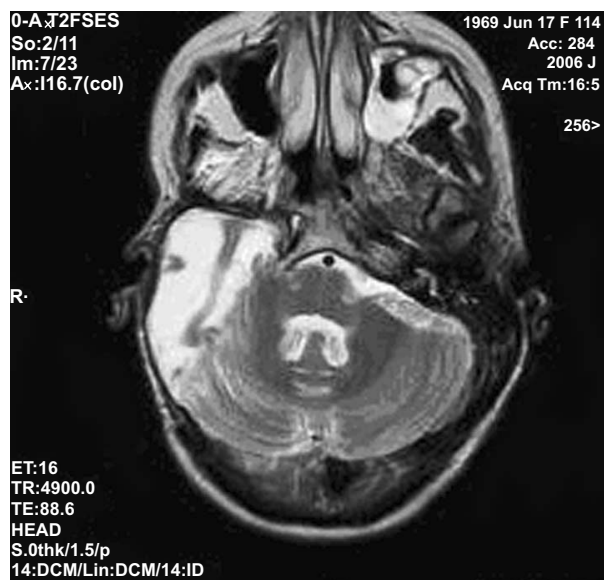
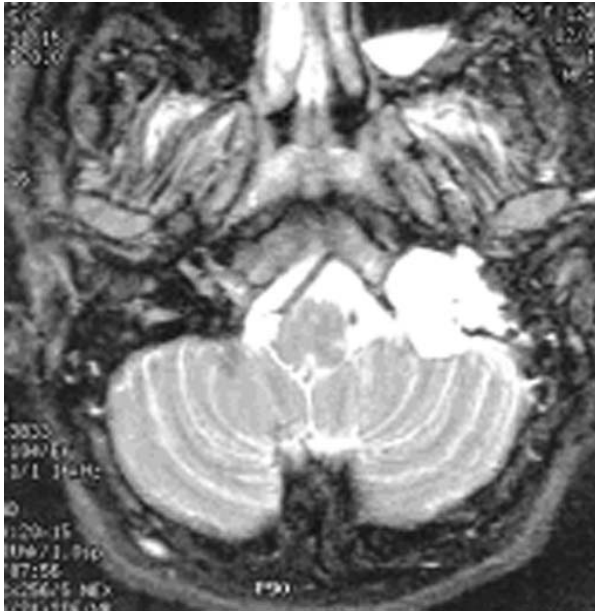
Fig. (7). (A, B) Right skull base tumor with a small area of extra-axial extension into the right posterior fossa over the cerebellar hemisphere.

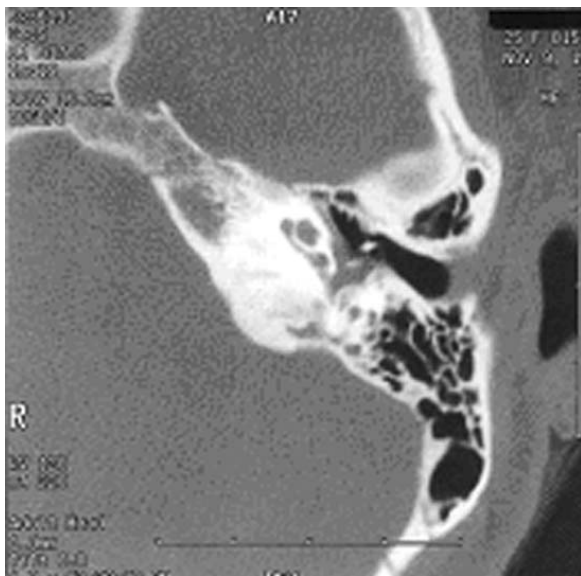
Middle and posterior fossa craniotomy were performed. Extensive bone was removed from the midline and posterior fossa. The tentorium was divided. Partial superficial parotidectomy was performed to identify the facial nerve. The mandibular condyle and a portion of the ascending ramus were resected to provide adequate access to the infratemporal fossa. A radical neck dissection was also performed. The internal carotid artery was dissected to the skull base. As the skull base was approached, tumor was encountered extending through the skull base for a distance of 1-2 cm inferiorly and for a distance of approximately 4 cm from anterior to posterior, involving the soft tissues of the neck. The tumor was adherent to and involved the vertebral artery. The lateral process of the first cervical vertebra was resected, and the vertebral artery was dissected free from tumor. The dissection was carried anteriorly, and the tumor was found to have eroded a substantial portion of bone in the skull base, extending anteriorly from the region of the vertebral artery to the jugular foramen, and nearly to the carotid artery. Tumor had grown through this area into the soft tissue of the infratemporal fossa. The craniotomy was completed with opening of the posterior fossa floor for nerve resections. There the tumor was found eroding through dura and extending intracranially in the area of the jugular foramen. Total temporal bone resection was performed, leaving a few millimeters of bone adjacent to the foramen magnum. The skull base was removed in continuity with the infratemporal fossa, mandible and neck tissues. There was a positive margin at the Eustachian tube. There was tumor within the soft tissue of the Eustachian tube. A sleeve resection of the residual tissue in this area was performed secondarily after the main specimen had been removed. The entire bony Eustachian tube had been removed with the specimen. The Eustachian tube was sutured closed to prevent CSF leak, and a muscle graft was placed. During the course of the dissection, the uninvolved portion of the tenth cranial nerve was preserved for facial nerve graft. A cable graft was performed from the seventh cranial nerve stump near the brain stem to the facial nerve in the parotid gland. Cricopharyngeus myotomy was performed to help rehabilitate swallowing.

She also received radiation therapy and underwent adjuvant chemotherapy four months after resection. Sixteen months after chemotherapy, MRI demonstrated no evidence of residual or recurrent tumor. The patient is doing very well other than her swallowing problems and her stable cranial nerve VII deficits, for which she has compensated, 20 months after resection.

Case 8 is a sixty-six-year old female who had complained of sudden onset of hearing loss in her left ear, imbalance, left otalgia and facial pain. Otoscopic examination revealed two bony protuberances in her left ear canal, extending from the posterior canal wall and partially obscuring visualization of the tympanic membrane. Hitselberger's sign was positive on the left. Weber lateralized to the right. She was totally deaf on the left. She had a grade VI/VI left facial paralysis with good Bell's phenomenon. Tandem Romberg was slightly unsteady with her eyes open, and she fell with her eyes closed. MRI scan (Fig. 8) revealed a 2.5 cm x 1.5 cm x 1.5 cm enhancing mass in the jugular foramen and non-specific



**Fig. (8A).** MRI demonstrating the mass in jugular foramen.



**Fig. (8B).** CT destruction lesion within left temporal bone.

enhancement of the seventh and eighth cranial nerves in the internal auditory canals, geniculate ganglion, and descending portion of the nerve. There was also enlargement of the third division of the fifth cranial nerve in the region of the foramen ovale. CT of the neck demonstrated a destructive soft tissue lesion within the left temporal bone (Fig. 8B) consistent with a stage IV adenocarcinoma involving her jugular fossa, skull base, ear, infratemporal fossa, and deep lobe of the parotid gland. It had not responded to stereotactic radiosurgery performed prior to her consultation with us and had continued to grow over a five month period. She elected to proceed with an attempt at total resection. She was prepared for total temporal bone resection en bloc with middle and posterior fossa craniotomy, although only a

modified resection was required. The tumor was removed (in its entirety with margins) using a sub-total resection without total temporal bone resection, because its superior aspect did not extend above the inferior aspect of the cochlea in the middle ear. The middle fossa floor was preserved.

An incision was made incorporating her previous mastoidectomy incision and extended into her neck. A mastoidectomy was performed to visually confirm the tumor size and location. Dissection was carried through the facial nerve and the cochlea. The sigmoid sinus was skeletonized, and a dissection plane was created between the medial aspect of the sigmoid sinus and the dura. Drills were used to circumscribe the area of the tumor (with 1 cm margins) as it extended into the hypotympanum from the jugular bulb. The anterior incision was carried through the carotid artery which had been occluded with coils pre operatively, and the dissection was extended anteriorly to a generous cuff of normal bone. The tumor was followed medially, resecting the medial aspect of the jugular bulb and entering the cranium, where a portion of tumor extended and was left undisturbed to be resected later during the operation. The tumor was then elevated from the jugular bulb region and dissected inferiorly. The lateral wall of the jugular bulb was resected with the tumor, leaving a good medial margin of uninvolved tissue. Total parotidectomy was performed. The tumor extended inferiorly and medially into the infratemporal fossa, nearly to the midline; and all involved tissue was resected with adequate margins.

The success of the maneuver in the infratemporal fossa obviated the need for total en bloc temporal bone resection. The cerebellar dura was opened between the sigmoid sinus and the inner ear, after partial removal of the labyrinth, providing adequate access to the posterior fossa. Residual tumor (still in continuity with the rest of the specimen) could not be removed in the region of the jugular bulb without resection of cranial nerves IX-XII as anticipated preoperatively. However, it was removed easily through this approach using chisels and a drill to obtain good bony margins. Radical neck dissection was performed. Bone of the lateral processes of the highest two cervical vertebrae was removed to gain access to the tumor, as it coursed along the most inferior aspect of the skull base. The tumor was removed almost entirely in continuity, en bloc. Upon inspection following neck dissection, there was area suspicious for residual tumor adjacent to the cervical vertebra. Further resection was carried out cautiously in this area. The ear canal was sewn shut internally with the everted edges in two layers. The craniotomy defect was repaired using homograft fascia lata and a large abdominal fat graft harvested through an incision in the left lower quadrant of the abdomen. The abdominal incision was closed, compression dressing applied, and the neck, mastoid, and craniotomy sites were closed with occlusive dressing applied. Final diagnosis was poorly differentiated (stage-IV) adenocarcinoma.

Postoperatively, she developed wound necrosis in her radiated field which required surgical debridement and closure. She succumbed to metastatic disease six months after surgery, without evidence of local recurrence.

Case 9 is a 52 year old gentleman who was diagnosed in 1995 with a nasopharyngeal tumor. The pathology report

suggested that the lesion was metastatic. He underwent maximum radiation therapy, radiation seed implantation, and an extended course of chemotherapy. He stated that he had been doing fine until in 2002, when a "bone chip" migrated down through his nose which caused a perforation in his palate. The surgical attempts to close his palatal perforation had been unsuccessful, and he was fitted with a palatal prosthesis. He had a gastric feeding tube in place, but was able to drink by mouth. He had developed a right tympanic membrane perforation after radiation and had undergone myringoplasty. He had a ventilating tube in his left ear because of chronic otitis media that also developed after radiation. Two months before he presented to the author (RTS), he complained of a lump on the cartilage of his right external ear. The lesion was excised, drained, and received a steroid injection without resolution. The ear mass actually had gotten larger, and he underwent a CT of the brain and temporal bones, and a biopsy of his ear mass. CT demonstrated a new right mastoid and external auditory canal mass with invasion of the sigmoid sinus, and opacification of the right tympanic cavity. PET scan revealed a highly metabolically active right temporal mass associated with destruction of the mastoid process and extension into the external auditory canal. There were metabolically active foci felt to be extension of the mass rather than separate metastases. There was no additional metastatic disease on complete whole body imaging.

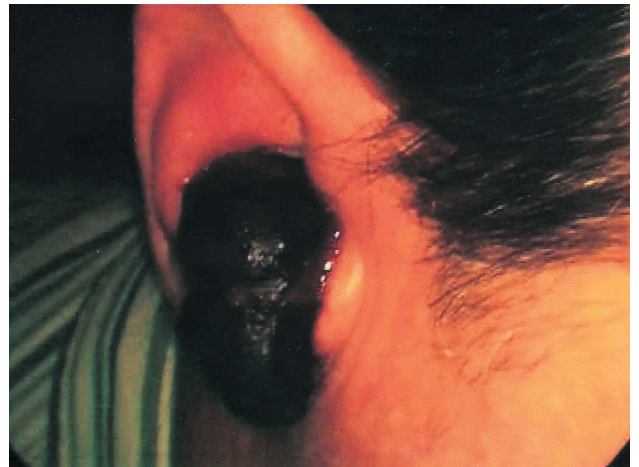
The patient stated that the tumor had grown approximately 2cm over the past two weeks and that he had no hearing in his right ear. He denied tinnitus or dizziness at present. However, at the time of onset of the tumor, he had experienced dizziness that had since abated.

Otoscopic examination revealed his right concha and lobe obscured with a neoplasm filling and protruding from his external auditory canal (Fig. 9). His audiogram revealed high frequency sensorineural hearing loss bilaterally with a low frequency conductive component on the right. His oral cavity revealed a 2cm by 1cm soft palatal defect adjacent to the hard palate. His maximum mouth opening was 1.4cm. His voice was husky, but vocal fold motion was present bilaterally. Gag reflex was intact. His neck was thickened by radiation changes and free of palpable nodes. He had a grade II-III/VI carotid bruit on the left. He fell to the left with Tandem Romberg with his eyes closed and was unsteady with his eyes open.

He was taken to the operating room for excisional biopsy (more than 3 cm of tumor were removed) to establish definitive pathology prior to a tentative skull base resection. Frozen section and subsequent permanent section were read as chondrosarcoma, and were reviewed by pathologists at three institutions.

His subsequent procedure consisted of a tracheotomy, right neck dissection with ligation of the internal carotid artery. En bloc resection was recommended, but the patient had elected subtotal temporal bone resection. At the conclusion of the procedure, extensive bone had been drilled largely around the tumor, and all apparent tumor had been resected; but the tumor had been transgressed at its most medial point over about 1 cm square. The facial nerve was resected with the tumor. A large meatoplasty was also performed. Postoperatively, the pathologic diagnosis was

changed to grade IV fibroblastic osteosarcoma, confirmed at Mayo Clinic.



**Fig. (9).** Neoplasm protruding from the external auditory canal.

Three weeks after the resection he was sent for an oncology consultation regarding the appropriate role of radiation and chemotherapy. The patient completed a postoperative course of external beam radiotherapy to the right side of the skull base and the right infratemporal region. He did well throughout treatment without any major acute toxicity. Two months after his last radiation treatment, he had right-sided facial pain, dry mouth and difficulty swallowing, which had been present prior to surgery. Nutritionally, he depended on a PEG tube. There were no other significant developments.

Ten months after the skull base surgery, he experienced a cerebral vascular accident. Five days later, he expired secondary to major cerebral anoxia.

## DISCUSSION

Temporal bone malignancy is rare, with squamous cell carcinoma the most common cancer of the external auditory canal, middle ear, and mastoid. Carcinoma of the temporal bone accounts for less than 0.2% of all tumors of the head and neck. Approximately 200 new cases of temporal bone cancer are diagnosed each year across the United States. That number includes cancers arising from skin of the pinna that spread to the temporal bone; primary tumors of the external auditory canal, middle ear, mastoid, or petrous apex; and metastatic lesions to the temporal bone [13]. There is no gender predominance, and most cases occur in the fifth and sixth decades of life. Definitive information about the treatment and prognosis of squamous cell carcinoma of the temporal bone is not easy to obtain due to a multitude of factors: the rarity of its malignancy, the lack of an accepted staging system (prior to 1990), and the wide variety of individualized treatments. Also, many authors include tumors of multiple histology in their reports of treatment outcomes, which further complicates the issue [14].

Chronic suppurative otitis media and the resulting chronic inflammation may lead to squamous metaplasia and carcinoma. Human papillomavirus has been implicated also in squamous cell carcinomas of the middle ear [15]. Lim *et al.* [16] reported a series of temporal bone cancers in seven

patients who had undergone radiotherapy for nasopharyngeal carcinoma and with poor outcomes.

Defining specific etiologic factors for cancers in this area is very difficult. However, fair-skinned Caucasians are more prone to nonmelanomatous skin cancers throughout the body, especially areas exposed to ultraviolet radiation including the region of the ear. A genetic predisposition to skin cancer may also exist. Chronic otitis media and cholesteatoma are common in patients with temporal bone cancers and have been implicated as etiologic factors [17, 18].

Extremely low incidence, high frequency of ear infections, and absence of specific symptoms make the malignancy difficult to recognize. Other factors may contribute to the challenge. Rarity of the disease and nonspecific presentation requires a high level of suspicion on the part of the otorhinolaryngologist. Most of the time, it is the prolonged symptomatology unresponsive to treatment that prompts further investigation; thus, the diagnosis is often delayed from one month to four years [13, 19, 20]. The red flags should be history of persistent aural discharge associated with change in quality and/or quantity, development or increase in otalgia, cranial nerve VII paralysis, aural or mastoid polyp, and vertigo. If, complete resolution does not occur after two-to-three weeks of vigorous medical therapy, it might be advisable to offer biopsy surveillance for temporal bone malignancy. Multiple authors have cautioned against reliance on a single biopsy results. They recommended strongly obtaining multiple deep biopsies including a cuff of normal tissue, even if general anesthesia or CT guidance is required. Inadequate biopsy may show only extensive inflammation and lead to delayed or missed diagnosis [12, 21-24].

The assessment of tumor invasion into soft tissue along fascial planes, perineural spread, and CNS infiltration is accomplished best with MRI [25, 26]. MRI with contrast is now the study of choice for evaluation of the skull base, especially the common sites of invasion: the petroclinoid fissure and foramen lacerum. Despite the great sensitivity of radiological studies, intra-operative evaluation is of undisputed importance. Multiple authors recognized the limitations of current radiography [14].

Rarity of the disease poses challenges not only with the development of a uniform classification, but also with management strategies. Despite technological advances, skull base surgery continues to be complex. It requires operative efforts between a patient and an extensive team of professionals. The goal of management is to be curative; yet, due to the nature of the temporal bone, the complex excision of tumor, whether piecemeal or en bloc, is often difficult once the tumor extends beyond the external auditory canal [14].

For extensive disease of the middle ear or involvement of the pneumatized spaces, TTBR may provide better oncologic control. In the original description of the procedure by Graham and Sataloff, the vascular and neural structures of the petrous apex are included with the resection. The goal of the procedure is en bloc removal of the tumor without tumor transgression, providing tumor free margins [14].

TTBR is a formidable procedure, which commonly requires 18-24 hours, and is associated with substantial blood loss (although the author, R.T.S. has performed one case successfully without transfusion in a Jehovah's witness). It should be performed only as a curative operation in patients who are physiologically and psychologically prepared to tolerate the procedure and a prolonged recovery. Paralysis of cranial nerves VI-XII is planned, and the patient and family must be thoroughly informed before this method is chosen. If the tumor encroaches upon the internal carotid artery, preoperative balloon test occlusion should be performed to determine the perfusion capacity of the contralateral side. This will help determine whether the patient is able to tolerate the resection of the internal carotid artery or will require intracranial bypass surgery [14].

To date, there have been no treatment-control studies reported. Most of the many treatment approaches are based on individual experience. In 1994, Prasad and Janecka [27] attempted to gain perspective on the role of surgery in the management of malignant tumors of the temporal bone. They reviewed the available literature and selected 26 publications that had comparable data. From the data analysis of 144 patients, they made the following suggestions: (a) tumors limited to the external auditory canal have a 50% overall cure rate after mastoidectomy or lateral temporal bone resection (LTBR) or subtotal temporal bone resection (STBR); (b) addition of radiation therapy after LTBR does not appear to be advantageous; (c) compared with mastoidectomy and LTBR, STBR improves survival once the tumor involves the middle ear. It may appear that conclusions made from such an in-depth study would hold true, and indeed, multiple authors continue to use their suggestions. However, upon a closer examination, one finds that for each treatment modality the patients' sample size remained small. The staging system they used was limited: tumor confined to the external auditory canal, tumor extended into the middle ear, and tumor invading the petrous apex. Moreover, the radiation protocols and techniques have changed. Furthermore, multiple studies (prospective and retrospective) published since 1994 have disputed their conclusions [14].

Several factors are associated with decreased survival rates. These include the local extent of the tumor, facial paralysis, positive margins, dural involvement, and lymph node metastasis. Some studies have found that advanced age (less than 60-65 years old) [28, 29] multiple cranial nerve involvement, moderate-to-severe pain, and female sex may worsen prognosis [30, 31].

Squamous cell carcinoma of the temporal bone remains a complex, challenging and incompletely understood disease. However, it is not hopeless. Through aggressive treatment, even rare patients with advanced disease can be cured. Nevertheless, considerably more experience is needed before optimal treatment for all stages can be established with confidence [14].

Primary sarcomas of the temporal bone are even more rare than primary carcinomas, but some are aggressive and lethal, such as osteogenic sarcoma. The literature contains scattered small series, case reports, and literature reviews of temporal bone sarcomas; however, most have too few cases to determine scientifically a superior treatment approach.

However, most studies provide an opinion or theory on how to handle these rare and aggressive tumors [14]. Nonrhabdomyosarcoma sarcomas are usually treated with wide and/or radical surgical resection with varying protocols utilizing pre and postoperative radiation and chemotherapy. Proton beam radiation has been used increasingly to treat chondrosarcomas and osteosarcomas of the temporal bone and skull base, with encouraging results. Further research and wider application may confirm this as a good radiation modality for all skull base sarcomas [14].

Chondrosarcomas account for 0.1% of all head and neck tumors and almost 6% of all skull base lesions [32]. There are few different theories proposed as to how chondrosarcomas develop in the temporal bone. The bones of the skull base mature predominantly by endochondral ossification while the bones of the skull vault develop primarily by intramembranous ossification [33]. The areas of the petro-occipital, sphenoccipital, and sphenopetrosal synchondroses, as well as a large part of the petrous portion of the temporal bone, are sites in the mature skull that underwent endochondral development [34]. It is hypothesized that islands of residual endochondral cartilage may be present in these areas and that chondrosarcomas may arise from pluripotent mesenchymal cells involved in the embryogenesis of the skull base and temporal bone. Lastly, metaplasia of mature fibroblasts has been implicated as an inciting mechanism in the development of chondrosarcomas [35, 36].

Primary chondrosarcoma develops *de novo* in normal bone. Most temporal bone chondrosarcomas arise in this manner. Rarely, there are secondary chondrosarcomas which arise from preexisting cartilaginous tumors or abnormalities. Chondrosarcoma has been reported in association with Paget's disease, Maffucci syndrome, osteochondrogenous exostoses, Ollier's disease, and osteochondromas [37, 38].

Several clinical presentations have been reported for chondrosarcomas of the skull base. The symptoms correlate with the anatomic site of destruction or compression. Initial complaints may include hearing loss, pulsatile tinnitus, vertigo/unsteadiness, aural fullness, and headache. Multiple cranial neuropathies are common and present as diplopia, facial pain, paraesthesias, hemifacial spasm, facial paresis, dysphagia, hoarseness, shoulder weakness, and hemi-tongue weakness and atrophy. A comprehensive neurotologic work-up is indicated when temporal bone lesions are suspected. The work-up includes pure tone and speech audiometry, CT of the temporal bones and brain, MRI/MRA, as well as any other tests that are indicated clinically [34, 39].

Treatment approaches have evolved throughout the years and include combinations of surgical debulking, complete surgical excision, radiation, and chemotherapy. Although most studies report a treatment bias, the paucity of patients with chondrosarcoma of the temporal bone makes it impossible to perform prospective trials that could lead to definitive treatment conclusions. Anecdotal protocols are common. Due to a concern that surgical debulking violates tumor boundaries and oncologic principles, the concept of total en bloc resection with total gross removal of disease has been suggested as the preferred surgical procedure when removing chondrosarcoma of the skull base and temporal bone [14].

Osteosarcoma is a highly aggressive malignant tumor that usually presents in the metaphysis of long bones. The majority of cases occur between the ages of 10 and 30 years with the median age of 28. There are about 7,400 new cases and 4,200 deaths from osteosarcoma occurring annually in the United States. Approximately 10% of cases occur in the head and neck, and this accounts for about 900 new cases per year [40, 41]. In a review of world literature, Sataloff *et al.* [11] found 19 reported cases of osteosarcoma involving the temporal bone, with the largest series reporting three cases. An additional three have been reported since then for a total of 22 cases [11, 41-43]. Almost every bone of the skull has been involved as a primary site; however, the mandible was clearly the most common primary location in the head and neck [40, 44-46].

Osteosarcoma is thought to arise from immature bone-forming cells or through neoplastic differentiation of other mesenchymal cells into osteoblasts. Histologically, a tumor is considered to be an osteosarcoma if it demonstrates malignant spindle cells producing osteoid in various stromal backgrounds. Subtypes are based on the predominant characteristic of the cells and stroma and include osteoblastic, chondroblastic, fibroblastic, small cell, and telangiectatic [43-46].

In most studies of head and neck osteosarcoma, the most common presentation is pain and swelling over the area of the bone containing the lesion [41]. In their review of 19 patients with osteosarcoma, Sataloff *et al.* [11] demonstrate that the most common presenting symptoms or signs were a mass in the temporal fossa, mastoid, or external ear canal in 84% (16/19), facial paralysis in 47% (9/19), conductive hearing loss in 37% (7/19), otalgia in 32% (6/19), bloody or purulent otorrhea in 16% (3/19), and other cranial nerve deficits in 16% (3/19) [10]. As with other skull base and temporal bone malignancies, symptoms caused by cranial nerve deficits are determined by the site of tumor involvement.

Again, only 22 cases of osteosarcoma of the temporal bone have been reported in the English literature since 1910 [11, 40-44]. Over that time, treatment has widely varied and follow-up was inconsistent or not reported in nearly one-third of the cases. Consequently, treatment protocols for temporal bone osteosarcoma have to be extrapolated from series reporting osteosarcomas located in the head, neck, and other body sites. Most recent reports including Sataloff *et al.* [11, 12] and Sharma *et al.* [41] support the radical resection of temporal bone osteosarcoma with the use of adjuvant radiation and chemotherapy.

Glomus jugulare tumors are rare, but when they occur, as in case 2, hearing loss and tinnitus are frequently the only symptoms. This peculiar neoplasm arises from cells around the jugular bulb and expands to involve the neighboring structures [47]. In doing so, the neoplasm most frequently extends to the floor of the middle ear, causing conductive hearing loss and pulsating tinnitus. As the disease progresses, it may appear as chronic otitis media and may even extend through the eardrum and appear to be granulation tissue in the ear canal. Unsuspecting biopsy of this apparent granulation tissue may cause profuse bleeding because of the marked vascularity of the tumor. As the

disease extends, it may destroy portions of the temporal bone and jugular bulb and can extend intracranially [14].

Radiological evaluation is now the mainstay of glomus tumor diagnosis. CT of the temporal bone is used to assess bone erosion, and MRI, MR angiography, traditional arteriography and retrograde jugular venography are used to define the extent of the neoplasm. Four vessel arteriograms are now being recommended by some otologists because of the high incidence of associated tumors. Up to 10% of patients with glomus tumors will have associated bilateral glomus tumors, glomus vagale, carotid body tumor, or thyroid carcinoma [47]. Biopsy is used appropriately to rule out other lesions and in patients who are not surgical candidates prior to instituting palliative radiation therapy [14].

### SUMMARY

The optimal management of temporal bone cancer remains unclear because of continued debate regarding staging, the utility of preoperative radiographic evaluation, the value of non-surgical management with radiation and/or chemotherapy, nomenclature of surgical procedures, and the use of adjuvant radiation. The limited number of cases of temporal bone malignancies at each individual institution precludes definitive conclusions regarding the optimal management protocol [13].

Total en bloc temporal bone resection can be performed successfully in the hands of an experienced skull-base surgical team. This procedure allows resection of extensive, carefully selected, malignant tumors, and maybe appropriate very rarely for histologically benign but biologically aggressive neoplasms. Each new case brings about refinements in technique. Protection against deep vein thrombosis preoperatively has become routine. Carotid balloon occlusion testing also has become routine. Experience has shown that it is possible to extend resection beyond the midline, if necessary; and when the inferior aspect of the cavernous sinus is involved, partial resection of the sinus with preservation of nerves is possible. The interest, expertise, and active participation of the operating room nursing team are critical to the success of this surgery. Not only intraoperative nursing participation, but also preoperative assessment and postoperative support require special expertise and dedication. Close cooperation and extensive communication among the surgeons, nurses, and consultants are essential [12]. Mortality and morbidity are high, and ideal candidates are young, healthy people with localized disease considered lethal, and regarded traditionally as unresectable. Rarely, intra-operative evaluation and modification to a somewhat less extensive procedure is appropriate. However, in general, patients and the health care team should be prepared to proceed with the total en bloc resection "without seeing tumor" in order to give these patients with deadly disease at least some chance of cure.

### REFERENCES

- [1] Graham MD, Sataloff RT, Kemink JL, *et al.* Total en bloc resection of the temporal bone and carotid artery for malignant tumors of the ear and temporal bone. *Laryngoscope* 1984; 94(4): 528-33.
- [2] Leonetti JP, Smith PG, Kletzker GR, *et al.* Invasion patterns of advanced temporal bone malignancies. *Am J Otol* 1996; 17: 438-42.
- [3] Kenyon GS, Marks PV, Scholtz CL, *et al.* Squamous cell carcinoma of the middle ear: a 25 year retrospective study. *Ann Otol Rhinol Laryngol* 1985; 94: 273-77.
- [4] Pfreundner L, Schwager K, Willner J, *et al.* Carcinoma of the EAC and middle ear. *International J Radiat Oncol Biol Phys* 1999; 44: 777-88.
- [5] Moffat DA, Chiossone-Kerdel JA, Da Cruz M. Squamous cell carcinoma. In: Jackler RK, Driscoll CLW Eds. *Tumors of the Ear and Temporal Bone*. Philadelphia: Lippincott, Williams, and Wilkins 2000: pp. 67-83.
- [6] Moffat DA, Grey P, Ballagh RH, *et al.* Extended temporal bone resection for squamous cell carcinoma. *Otolaryngol Head Neck Surg* 1997; 116: 617-23.
- [7] Sataloff RT, Myers DL, Lowry LD, *et al.* Total temporal resection for squamous cell carcinoma. *Otolaryngol Head Neck Surg* 1987; 96: 5-14.
- [8] Pomeranz S, Sekhar LN, Janecka IP, *et al.* Classification, technique, and results of surgical resection of petrous bone tumors. In: Sekhar LN, Janecka IP Eds. *Surgery of cranial base tumors*. New York: Raven Press 1993: pp. 317-35.
- [9] Barrs DM. Temporal bone carcinoma. *Otolaryngol Clin North Am* 2001; 34(6): 1197-218.
- [10] Sataloff RT, Myers DL. Total temporal bone resection. *Cadernu Otorinolaringol* 1987; 95(5-6): 321-32.
- [11] Sataloff RT, Myers DL, Spiegel JR, Roberts BR, Telian S. Total temporal bone resection for osteogenic sarcoma. *Ear Nose Throat J* 1988; 67: 626-51.
- [12] Sataloff RT, Roberts BR, Myers DL, Spiegel JR. Total temporal bone resection: a radical but life saving procedure. *AORN J* 1988; 48(5): 932-48.
- [13] Antonio SM, Hirsch BE. Malignant tumors of the temporal bone. *EMedicine*. Available from: <http://www.emedicine.com/ent/topic476.html> [Retrieved on Aug 15, 2007].
- [14] Sataloff RT, Sataloff J. *Hearing Loss*. 4<sup>th</sup> ed. Boca Raton, FL: CRC Press 2006; pp. 545-602.
- [15] Jin YT, Tsai Li C, Chang KC, *et al.* Prevalence of human papillomavirus in middle ear carcinoma associated with chronic otitis media. *Am J Pathol* 1997; 150: 1327-33.
- [16] Lim LH, Goh YH, Chan YM, *et al.* Malignancy of the temporal bone and external auditory canal. *Otolaryngol Head Neck Surg* 2000; 122(6): 882-86.
- [17] Morton RP, Stell PM, Derrick PP. Epidemiology of cancer of the middle ear cleft. *Cancer* 1984; 53: 1612-17.
- [18] Moffat DA, Wagstaff SA, Hardy DG. The outcome of radical surgery and postoperative radiosurgery for squamous carcinoma of the temporal bone. *Laryngoscope* 2005; 115(2): 341-7.
- [19] Chen KTK, Dehner LP. Primary tumors of the external (auricle and auditory canal) and middle ear. I: Introduction and clinicopathological study of squamous cell carcinoma. *Arch Otolaryngol* 1978; 104: 253-59.
- [20] Wagenfeld DJH, Keane T, van Nostrand AWP, Bryce DP. Primary carcinoma involving the temporal bone: analysis of twenty-five cases. *Laryngoscope* 1980; 90: 912-19.
- [21] Lewis JS. Surgical management of tumor of the middle ear and mastoid. *J Laryngol Otol* 1983; 97: 299-311.
- [22] Gacek MR, Gacek RR, Gantz B, McKenna M, Goodman M. Psuedoepitheliomatous hyperplasia *versus* squamous cell carcinoma of the external auditory canal. *Laryngoscope* 1998; 108: 620-3.
- [23] Moffat DA, Wagstaff SA. Squamous cell carcinoma of the temporal bone. *Curr Opin Otolaryngol Head Neck Surg* 2003; 11: 107-11.
- [24] Suzuki K, Takahashi M, Ito Y, *et al.* Bilateral middle ear squamous cell carcinoma and clinical review of an additional 5 cases of middle ear carcinoma. *Auris Nasus Larynx* 1999; 26: 33-8.
- [25] Baker S, Latack JT. Magnetic resonance imaging of the head and neck. *Otolaryngol Head Neck Surg* 1986; 95: 82-9.
- [26] Levine PA, Paling MR, Black WC, Cantrell RW. MRI *vs* high resolution CT scanning: evaluation of the anterior skull base. *Otolaryngol Head Neck Surg* 1987; 96: 200-67.
- [27] Prasad S, Janecka IP. Efficacy of surgical treatment for squamous cell carcinoma of temporal bone: a literature review. *Otolaryngol Head Neck Surg* 1994; 110: 270-80.
- [28] Ruben RJ, Thaler SU, Holzer N. Radiation induced carcinoma of the temporal bone. *Laryngoscope* 1977; 87: 1613-21.

- [29] Liu FF, Keane TJ, Davidson J. Primary carcinoma involving the petrous temporal bone. *Head Neck* 1993; 15: 39-43.
- [30] Birzgalis AR, Keith AO, Farrington WT. Radiotherapy in treatment of middle ear and mastoid carcinoma. *Clin Otolaryngol* 1992; 17: 113-16.
- [31] Manolidis S, Pappas D, Von Doersten P, *et al.* Temporal bone and lateral skull base malignancy: experience and results with 81 patients. *Am J Otol* 1998; 19: S1-S15.
- [32] Koch BB, Karnell LH, Hoffman HT, *et al.* National Cancer Database Report on chondrosarcoma of the head and neck. *Head Neck* 2000; 22: 408-25.
- [33] Lau DPC, Wharton SB, Antoun NM, *et al.* Chondrosarcoma of the petrous apex. Dilemmas in diagnosis and treatment. *J Laryngol Otol* 1997; 111: 368-71.
- [34] Watters GWR, Brookes GB. Chondrosarcoma of the temporal bone. *Clin Otolaryngol* 1995; 20: 53-58.
- [35] Coltrera MD, Gooze PB, Harrist TJ, *et al.* Chondrosarcoma of the temporal bone. Diagnosis and treatment of 13 cases and review of the literature. *Cancer* 1986; 58: 2689-96.
- [36] Siedman MD, Nichols RD, Raju UB, *et al.* Extracranial skull base chondrosarcoma. *Ear Nose Throat J* 1989; 68: 626-32.
- [37] Brown E, Hug EB, Weber AL. Chondrosarcoma of the skull base. *Neuroimaging Clin North Am* 1994; 4: 529-41.
- [38] Burkey BB, Hoffman HT, Baker SR, *et al.* Chondrosarcoma of the head and neck. *Laryngoscope* 1990; 100: 1301-05.
- [39] Kveton JF, Brackmann DE, Glasscock ME, *et al.* Chondrosarcoma of the skull base. *Otolaryngol Head Neck Surg* 1986; 94: 23-31.
- [40] Mark RJ, Sercarz JA, Tran L, *et al.* Osteogenic sarcoma of the head and neck. The UCLA experience. *Arch Otolaryngol Head Neck Surg* 1991; 117: 761-66.
- [41] Sharma SC, Handa KK, Panda N, *et al.* Osteogenic sarcoma of the temporal bone. *Am J Otolaryngol* 1997; 18(3): 220-23.
- [42] Goh YH, Chong VFH, Low WK. Temporal bone tumours in patients irradiated for nasopharyngeal neoplasm. *J Laryngol Otol* 1999; 113: 222-28.
- [43] Nora FE, Unni KK, Pritchard DJ, *et al.* Osteosarcoma of extragnathic craniofacial bones. *Mayo Clin Proc* 1983; 58: 268-72.
- [44] Kassir RR, Rassekh H, Kinsella JB, *et al.* Osteosarcoma of the head and neck: meta-analysis of nonrandomized studies. *Laryngoscope* 1997; 107: 56-61.
- [45] Hazarika P, Nayak DR, Sahota JS, *et al.* Osteogenic sarcoma of the sphenoid bone: an extended lateral skull base approach. *J Laryngol Otol* 1995; 109: 1101-04.
- [46] Garrington GE, Scofield HH, Cornyn J, *et al.* Osteosarcoma of the Jaws. Analysis of 56 cases. *Cancer* 1967; 20(3): 377-91.
- [47] Glasscock ME. Surgery of glomus tumors of the temporal bone. Paper presented at: Middle Section Meeting. American Laryngological, Rhinological, and Otological Society, Inc., Indianapolis, IN. January 1979.

---

Received: January 22, 2009

Revised: November 4, 2009

Accepted: November 10, 2009

© Rutt *et al.*; Licensee Bentham Open

This is an open access article licensed under the terms of the Creative Commons Attribution Non-Commercial License (<http://creativecommons.org/licenses/by-nc/3.0/>) which permits unrestricted, non-commercial use, distribution and reproduction in any medium, provided the work is properly cited.