



The Open Dentistry Journal

Content list available at: <https://opendentistryjournal.com>



SYSTEMATIC REVIEW

Assessment of Peri-implant Buccal Bone Thickness Using Digital Imaging Techniques: A Systematic Review and Meta-analysis

Lauren Bohner^{1,2,*}, Marcel Hanisch², Israel Chilvarquer³, Johannes Kleinheinz² and Pedro Tortamano¹

¹Department of Prosthodontics, School of Dentistry, University of São Paulo, São Paulo, SP, Brazil

²Department of Craniomaxillofacial Surgery, Hospital University Münster, Germany

³Department of Stomatology, School of Dentistry, University of São Paulo, São Paulo, SP, Brazil

Abstract:

Objectives:

This systematic review aimed to answer the following focused question: Do the currently available imaging techniques provide accuracy in the assessment of peri-implant buccal bone thickness?

Methods:

A search strategy was conducted in eight electronic databases, followed by an additional manual search in grey literature and references of selected articles. Studies evaluating the accuracy of imaging techniques to measure peri-implant buccal bone thickness were included. Individual risk of bias was assessed by the Quality Assessment Tool for Diagnostic Accuracy Studies-2 (QUADAS-2). Meta-analysis was performed to evaluate CBCT accuracy. The overall effect size was determined by means of the Z-test. Q test was used to evaluate the homogeneity of effect sizes among studies and I² was applied to determine the variance within studies.

Results:

After an initial screening, 83 studies were further selected for full reading and 13 of them were considered eligible for this review. In sum, the accuracy of Cone-beam Computed Tomography (CBCT), of ultrasound, and of computed tomography were assessed. There was no statistically significant difference between CBCT and the gold standard (p=0.81). The mean difference between measurements of bone thickness obtained by CBCT and the goldstandard was -0.0.3mm [95%CI -0.29;0.253mm].

Conclusion:

CBCT showed acceptable accuracy for assessing peri-implant bone. No meaningful conclusion could be drawn about other techniques.

Keywords: Dental implants, diagnostic imaging, cone-beam computed tomography, diagnostic x-ray, ultrasonic imaging.

Article History

Received: January 06, 2020

Revised: February 27, 2020

Accepted: March 08, 2020

1. INTRODUCTION

As far as the long-term outcome of dental implants is concerned, the health of soft and hard peri-implant tissues is essential to ensure a successful result [1, 2]. In this sense, one of the main factors responsible for their integrity is the bone volume surrounding dental implants [3 - 8]. A thin buccal bone is known to be a risk factor for the long-term stability of peri-implant tissues and may jeopardize esthetic and biological out-

comes [9 - 11]. Thus, assessment of buccal bone thickness during maintenance consultations is essential to prevent complications [1, 12].

Recently, Cone-beam Computed Tomography (CBCT) has allowed the non-invasive assessment of buccal bone thickness after implant placement [9, 13]. Despite the well-validated reliability of CBCT, limitations regarding image quality have been shown as a result of artifacts associated with dental implants [14]. Hence, especially in cases in which bone is thinner than 1mm, this may not be accurately detectable in tomographic images [15]. An additional aspect to consider is the ionizing radiation-induced by CBCT [16] which prevents its use for periodical monitoring of dental implants [17].

* Address correspondence to this author at the Department of Prosthodontics, School of Dentistry, University of São Paulo, Av. Prof. Lineu Prestes, 2227, 05508-000 São Paulo, SP, Brazil; Tel: +55 11 3091 7885, Fax: +55 11 3091 7640; E-mail: lauren@usp.br

In this regard, novel digital modalities focusing on peri-implant bone assessment have been evaluated to overcome these limitations [18 - 20]. Despite the promising results, the accuracy of new tridimensional techniques has not yet been validated in the literature. Previous systematic reviews have addressed the use of digital technologies for pre- and post-operative assessment of dental implants [17, 21, 22]. Their accuracy in measuring peri-implant buccal bone thickness, however, has not yet been determined.

Considering that limiting factors can hamper the accuracy of CBCT, and that efforts have been made to find new techniques for measuring peri-implant bone thickness, the present study aimed to answer the following focused question: do the currently available tridimensional imaging techniques provide enough accuracy to assess peri-implant buccal bone thickness?

2. METHODS

2.1. Protocol and Registration

This systematic review was reported according to recommendations of “The Preferred Reporting Items for Systematic Reviews and Meta-Analyses”(PRISMA [23] and it is registered at PROSPERO under the reference number CRD42016044049.

2.2. Eligibility Criteria

PICO (P= patients; I= intervention; C= comparison; O= outcome) was defined as: tridimensional digital images of peri-implant bone (P), in which buccal bone thickness was measured (I) and compared with a physical or histological gold standard (C) in order to determine the accuracy (O) of the imaging device. Accuracy was determined as the measurement error between the evaluated technique and a gold standard. In turn, this was defined as direct or histological measurements of peri-implant bone thickness.

Inclusion criteria comprised studies evaluating the accuracy of tridimensional imaging techniques to assess peri-implant buccal bone thickness. No restriction on time or language was applied. The following parameters were considered as the exclusion criteria: 1) Case reports, literature reviews, letters or abstracts; 2) Assessment of further bone parameters other than buccal bone thickness; 3) Assessment of diagnostic methods not considered reliable for clinical use.

2.3. Information Sources

A main search strategy was developed according to PICO as following:

(((((“Dental Implants”[Mesh]) OR “Dental Implants, Single-Tooth”[Mesh] OR “Dental Implantation” OR “Dental Implant”)) AND (“Bone-Implant Interface”[Mesh] OR bone OR “peri-implant bone” OR “buccal bone” OR “cortical bone” OR “bone dimension” OR “bone thickness”)) AND (“Tomography, X-Ray Computed”[Mesh] OR “Tomography”[Mesh] OR “Spiral Cone-Beam Computed Tomography”[Mesh] OR “Ultrasonography”[Mesh] OR “Radiography, Dental”[Mesh] OR ultrasound OR “magnetic

resonance” OR “CBCT” OR “digital volume tomography” OR “MRT” OR “Tridimensional Image”)) AND ((“dimensional measurement accuracy” OR accuracy)).

This search was applied in PubMed (Medline) databases and used as a reference for the additional Science Direct, Scopus, Embase and Web of Science databases. In addition, gray literature was explored in ProQuest, Scholar Google and OpenGrey sources. All searches were conducted from July until November 2019, and updated in February 2020. The authors did not contact study authors to identify additional studies. A reference manager software (EndNote Web, Thomson Reuters) was used to organize references and remove duplicates.

2.4. Study selection and Data collection process

Study selection was performed in duplicate by two independent reviewers. First, studies were screened according to titles and abstracts. Those studies that met the inclusion criteria were selected for full-text reading. Based on the inclusion and exclusion criteria defined, articles considered eligible for this review were selected. When sufficient data were provided, studies presenting a similar methodology were included in the quantitative analysis. In case of disagreement between two reviewers, a third reviewer was consulted to achieve a decision.

Data were extracted from the included articles by the first reviewer and checked by the second reviewer.

2.5. Data Items

The following data were considered of interest to answer the focused question: study data (author, year and country), sample features (sample size and type) and assessment (imaging technique, exposure parameters, bone thickness definition, gold standard), and measurement details (points of evaluation, number of examiners and repeatability), findings and conclusion.

2.6. Risk of Bias in Individual Studies

The methodological risk of bias assessment was carried out using the “Quality Assessment Tool for Diagnostic Accuracy Studies-2” (QUADAS-2) [24]. The validated tool consisted of checking questions related to the study design regarding four domains: “patient selection”, “index test”, “reference standard”, and “flow and timing”. The risk of bias is determined by checking each question as “yes”, “no” or “unclear”. The final result categorized the risk of bias as “high”, “low” or “unclear” [24]. Review Manager 5.3 software (RevMan 5.3, The Nordic Cochrane Centre, Copenhagen, Denmark) was used to perform the quality assessment.

2.7. Summary of Measures

Continuous data (mean and standard deviation) were extracted from studies reporting the bone thickness measured by an imaging technique and by the gold standard. The difference in means was used for statistical analysis. In cases in which the study described the accuracy of different imaging devices, these were described separately.

2.8. Synthesis of Results

Meta-analysis was performed with studies comparing CBCT with the physical measurements using the same software reported above (RevMan 5.3). A random-effect model was assumed. Averaging was weighted by inverse variance and standardized mean difference was defined as effect size. The overall effect size was determined by means of the Z-test, and Q test was used to evaluate the homogeneity of effect sizes among studies. Heterogeneity within studies was evaluated by using inconsistency indexes (I^2). I^2 greater than 50% was considered an indicator of substantial heterogeneity between studies ($p \leq 0.05$) [25].

2.9. Risk of Bias Across Studies

The small number of included studies did not support any further assessment of bias across studies.

3. RESULTS

3.1. Study Selection

A flow chart describing the selection process is shown in Fig. (1). The initial search resulted in 1106 studies. Subsequently, 357 duplicated articles were removed and 740 studies remained. After reading titles and abstracts, 70 articles were selected for a complete reading. Furthermore, nine out of 524 articles extracted from grey literature, in addition to four papers selected from manual search, were chosen for a more detailed evaluation. Thus, out of the total of 83 studies selected for full-reading analysis, 70 were excluded and 13 studies were considered eligible for this review. The list of excluded articles and their respective reasons for exclusion are listed in Appendix 1.

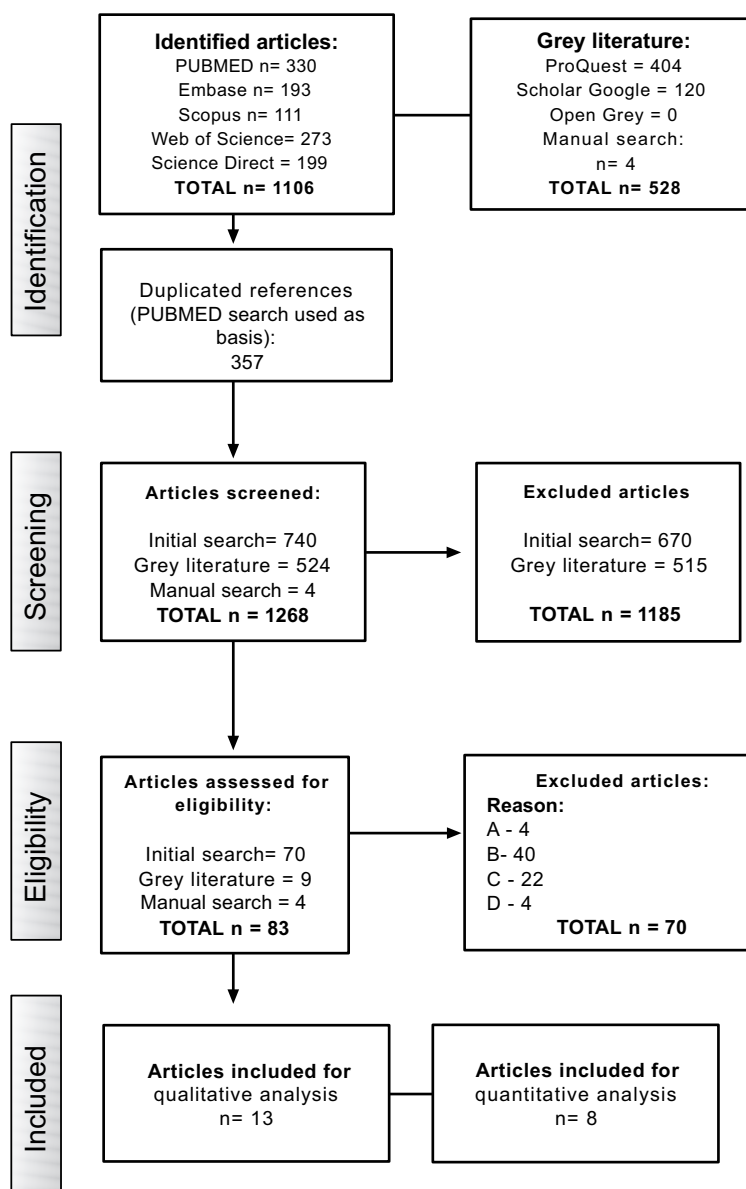


Fig. (1). Flowchart of search strategy.

3.2. Study Characteristics

A summary of study characteristics is described in Tables 1 and 2. Accuracy of CBCT was assessed by all studies. Additionally, one study evaluated computed tomography (CT) [26] and 4 studies evaluated the use of ultrasound-based techniques (US) [27 - 30].

All included studies selected in this review were laboratory studies, in which a total of 219 implants were placed in cadaver jaws [28 - 31] dry skulls [29, 32, 33], porcine or bovine bone [27, 26, 30, 34 - 36] or dogs [12].

As a reference standard, one study used histological samples, [12] five studies used light microscopy [27, 29, 32 -

34] and 2 studies performed physical measurements using a caliper [26, 28]. Digital images, used as a pre-operative scan without implants [31, 35, 37], optical scanner [30] or digital photograph [36] were also used as a reference.

3.3. Risk of Bias within Studies

Fig. (2) shows the QUADAS-2 assessment. In general, all studies presented a low risk of bias and few concerns about applicability. The patient selection domain was considered poor, since these were laboratory studies and a randomization process was not possible. For the same reason, the QUADAS-2 question "was a case-control avoided?" was considered not applicable to these studies.

Table 1. Summary of descriptive characteristics of included articles. CBCT= cone beam computed tomography; CT= computed tomography; US= ultrasound.

Study		Sample		-	-	Bone Assessment		
Author Year	Country	Bone Sample (n)	Type	Implants (n)	Implant Dimension (diameter x height)	Imaging Technique	Exposure Parameters	Gold Standard
Bohner <i>et al.</i> , 2017	Brazil	6	Dry skulls	18	3.75x9mm	CBCT (1:Carestream 9300; 2: R100 Veraview)	1: 70kV, 6.3mA, 8.03s, 0.18mm voxel size; 2: 75kV, 5mA, 9.40s, 125µm voxel size	Direct measurements (microscope)
Bohner <i>et al.</i> , 2019	Brazil	3	Dry skulls	10	3.75x9mm	CBCT (1:Carestream 9300), US	CBCT: 70kV, 6.3mA, 8.03s, 180µm voxel size; US: 28MHz, bandwidth 84%	Direct measurements (microscope)
Chan <i>et al.</i> , 2018	China	7	Cadavers	17	3.7x13mm	CBCT (3D Accuitomo 170), US	CBCT: 120kV, 18.66mA, 20s, 80 µm; US: 25MHz	Direct measurements (caliper)
Degen <i>et al.</i> , 2016	Germany	10	Bovine ribs	10	3.8x11mm	CBCT (Galileos, Sirona), US	85kV, 10mA, 30s; US: 42MHz, bandwidth 95%	Direct measurements (microscope)
González-Martín <i>et al.</i> , 2015	USA	10	Bovine ribs	20	-	CT (Brightspeed); CBCT (iCAT, NewTom)	CT: 120kV, 60mA, 4s 625µm; iCAT: 110kV, 4.8s, 2-3.2mA, 300µm; NewTom: 110kV, 4mA, 5.4s, 200µm	Direct measurements (caliper)
Liedke <i>et al.</i> , 2018	Brazil	40	Dry porcine mandible	3	4x9mm	CBCT (Scanora)	1) 90 kVp, 6.3mA, 13s, 200µm; 2) 90 kVp, 6.3mA, 20s, 130µm;	Digital photograph
Marotti <i>et al.</i> , 2019	Germany	8	Porcine ribs	8	3.8x11mm	CBCT (Galileos, Sirona); US	CBCT: 85kV, 10 ma, 30S, 300µm; US: 75MHz, aperture 6.35mm, focus 2	Optical scanner
Rásko <i>et al.</i> , 2016	Hungary	1	Porcine mandible	3	4.3x11mm; 3.8x11mm; 3.8x13mm	CBCT (iCAT)	120kV, 18mA, 8,9s, 200µm,	CBCT without implants
Razavi <i>et al.</i> , 2010	United Kingdom	10	Bovine ribs	10	4x11mm	CBCT (i-CAT NG and Accuitomo 3D, Morita)	i-CAT: 120kV, 18.54mA, 0.3mm voxel size; Accuitomo: 80kV, 4mA, 125µm voxel size	Direct measurements (microscope)
Ritter <i>et al.</i> , 2014	Germany	12	Dogs	26	-	CBCT (Galileos, Sirona)	CBCT: 85kV, 28mA, 300µm voxel size	Direct measurements (Histology)
Sheridan <i>et al.</i> , 2018	USA	9	Cadavers	19	4x10mm 4x12mm	CBCT (3D Accuitomo 170)	120kV, 18.66mA, 20s, 400 µm;	CBCT without implants

Study		Sample		-	-	Bone Assessment		
Author Year	Country	Bone Sample (n)	Type	Implants (n)	Implant Dimension (diameter x height)	Imaging Technique	Exposure Parameters	Gold Standard
Shiratori <i>et al.</i> , 2012	Brazil	8	Skulls	31	3.75x13mm	CBCT (i-CAT)	120kV, 46.72mA, 40s, 250µm voxel size	Direct measurements (microscope)
Vanderstuyft <i>et al.</i> , 2019	Belgium	5	Cadavers	44	3.6x13mm	CBCT (1: NewTom, Verona; 2: Accuitomo 170, Morita)	NewTom: 110kVp, 5.2mA, 150µm; Accuitomo: 90kVp, 5mA, 160µm	CBCT without implants

Table 2. Summary of outcomes of included articles. CBCT= cone beam computed tomography; CT= computed tomography; US= ultrasound.

Author, year	Measurements			Findings	Conclusion
	Points	Examiner	Repeatability		
Bohner <i>et al.</i> , 2017	Dental implant to bone surface at apical and 5mm above	1	3	No difference between CBCT and physical measurements	CBCT is accurate
Bohner <i>et al.</i> , 2019	Dental implant to bone surface at apical and 5mm above	1	3	No difference between CBCT and US to the control group	Trueness of US was similar to the one of CBCT
Chan <i>et al.</i> , 2018	Outsurface of bone crest and implant surface 1mm from the bone crest	1	1	The mean absolute difference among groups ranged from 0.033 to 0.24 mm.	Ultrasound can accurately measure bone dimensions
Degen <i>et al.</i> , 2016	Distance between dental implant and bone surface	1	1	Median deviation was higher for ultrasound (US) (0.23mm) compared to CBCT measurements (0.19mm)	US showed a high potential for bone evaluation
González-Martín <i>et al.</i> , 2015	1mm apical to the bone crest	2	1	CBCT underestimated buccal bone	Devices presented low accuracy to measure bone
Liedke <i>et al.</i> , 2018	Distance between bone and implant surface from occlusal view	3	1	Low resolution jeopardize bone detection	CBCT overestimated bone thickness
Marotti <i>et al.</i> , 2019	Distance between implant and bone surface along the long axis of the implant	2	1	US and CBCT showed similar measurement values to optical scanner	US presented a higher accuracy in comparison to CBCT
Rásko <i>et al.</i> , 2016	Measurements were made at each thickness level	1	1	Deviation increased with a reduced bone thickness	CBCT was not accurate, especially for thin bone
Razavi <i>et al.</i> , 2010	Distance between dental implant and bone surface at implant threads 3, 6 and 9mm from the top of the implant	10	2	Bone thickness calculation showed a mean deviation of 0.14±0.15mm for Accuitomo and 0.46±0.24mm for I-CAT. For bone level, the mean deviation was 0.76±0.57mm to Accuitomo and 2.10±1.58mm to I-CAT	i-CAT did not produce sufficient resolution for the thin bone
Ritter <i>et al.</i> , 2014	From dental implant middle to bone surface, 4mm above apical of implant.	2	2	Mean deviation ranged from 0.06 to 2.61mm to CBCT and 0.12 to 0.43 to IR	CBCT provided usable information about bone dimension
Sheridan <i>et al.</i> , 2018	At the implant platform and apex	-	1	No statistical difference was found in images with and without implants	Dental implants to not hamper the measurements of bone thickness by CBCT
Shiratori <i>et al.</i> , 2012	Dental implant to bone surface at apical and 5mm above	1	3	Mean difference for CBCT was 0.04±0.01mm for bone thickness and 0.13±0.86mm for bone level	CBCT is accurate
Vanderstuyft <i>et al.</i> , 2019	2,4, and 6mm to the implant shoulder	1	1	Bone thickness was underestimated by 0.3mm	CBCT underestimated bone thickness

	<u>Risk of Bias</u>				<u>Applicability Concerns</u>		
	Patient Selection	Index Test	Reference Standard	Flow and Timing	Patient Selection	Index Test	Reference Standard
Bohner 2017	-	+	-	+	+	+	+
Bohner 2019	-	+	-	+	+	+	+
Chan 2018	-	+	+	+	+	+	+
Degen 2016	-	+	+	+	+	+	+
Gonzales-Martin 2015	-	+	+	+	○	○	○
Liedke 2018	-	+	+	+	+	+	-
Marotti 2019	-	+	+	+	+	+	-
Raskó 2016	-	+	-	+	+	+	-
Razavi 2010	-	+	+	+	+	+	+
Ritter 2014	-	+	+	+	+	+	+
Sheridan 2018	-	+	-	+	+	+	-
Shiratori 2012	-	+	-	+	+	+	+
Vanderstuyft 2019	-	+	-	+	+	+	-



 High	 Unclear	 Low
--	---	--

Fig. (2). Risk of bias within studies with QUADAS-2.

With regard to the test group, all studies presented a low risk of bias. It was unclear whether the reference standard was interpreted without knowledge of the index result. However, this was not considered a risk due to the limitations of the in-vitro study design.

Measurements of bone thickness, which were not performed on the physical bone samples, but cast models instead, were considered high risk. Furthermore, the studies that used digital images as gold standards were considered doubtful for answering the focused question of this review.

3.4. Results of Individual Studies

All studies evaluated the accuracy of CBCT with reference to standard values. In comparison with histological samples, Ritter *et al.* (2014) [12] showed a measurement error of 0.42mm for buccal bone thickness measured by CBCT. According to Degen *et al.* (2016) [27], CBCT showed a deviation of 18% when measurements were performed in the middle or center of the implant. Nonetheless, Razavi *et al.* (2010) [34] showed that measurement error ranged from 23% to 86% with different CBCT devices.

Shiratori *et al.* (2012) [32] showed an underestimation of up to 0.07mm, whereas Gonzales-Martín *et al.* (2015) [26] found that the measurement was underestimated in a range from 0.3mm to 0.5mm. No significant difference was found when comparing conventional with cone-beam computed tomography. The highest values were found by Bohner *et al.* (2017;2019) [29, 33], who showed a deviation of 0.78mm for measurements at the apex and 0.40mm for measurements 5mm above the apex.

When considering preoperative CBCT images, Raskó *et al.* (2016) [35] showed that bone thickness measurements ranged from 0.26mm to 1.65mm when CBCT images were taken without implants, and from 0mm to 1.46mm in CBCT images taken after implantation. Sheridan *et al.* (2018) [31] showed an underestimation of 0.04mm when measurements were taken at the implant platform and of 0.02mm when these were taken at the implant apex after placement of implants. Likewise, Vanderstuyft *et al.* (2019) [37] found a mean bone thickness deviation of up to 0.27mm when compared with CBCT images without implants. In comparison with optical imaging, Marotti

et al. (2019) [30] showed a mean measurement error of 0.2mm for CBCT. This mean was in agreement with the study of Liedke *et al.* (2019) [36], who showed that most measurement errors were under 0.5mm in comparison with measurements taken in digital photographs.

Ultrasound-based techniques were evaluated in four studies. Degen *et al.* (2016) [27] showed a mean error of 12.1% in comparison with the gold standard. In comparison with optical images, the measurement error was 0.28mm. [30] Chan *et al.* (2018) [28] showed a mean difference of 0.3mm in comparison with direct measurements. Likewise, Bohner *et al.* (2019) [29] described a mean difference of 0.38mm when scanning with high-resolution ultrasound.

3.5. Synthesis of Results

I^2 among studies was 11% ($p=0.34$). There was no statistically significant difference between the CBCT and the gold standard ($p=0.81$). Fig. (3) shows the mean values and standard deviation of the peri-implant buccal bone thickness measured by CBCT and by the Gold Standard. The mean difference between measurements of bone thickness between them was -0.03mm [95%CI -0.29;0.253mm].

3.6. Risk of Bias Across Studies

The diversified methodology was considered a bias across studies.

4. DISCUSSION

The estimation of buccal bone thickness is an important parameter to predict the outcome of dental implant treatment. To date, the most reliable alternative to provide a non-invasive assessment of the buccal bone of the jawbone is CBCT. Nonetheless, novel imaging techniques have been investigated to overcome the limitations of a tomographic technique, such as ionizing radiation and artifacts. This research aimed to search the literature relative to the question about whether currently available techniques can provide accurate measurements of buccal bone during implant assessment.

According to the included studies, CBCT deviates from real measurements by less than 1mm, which is considered

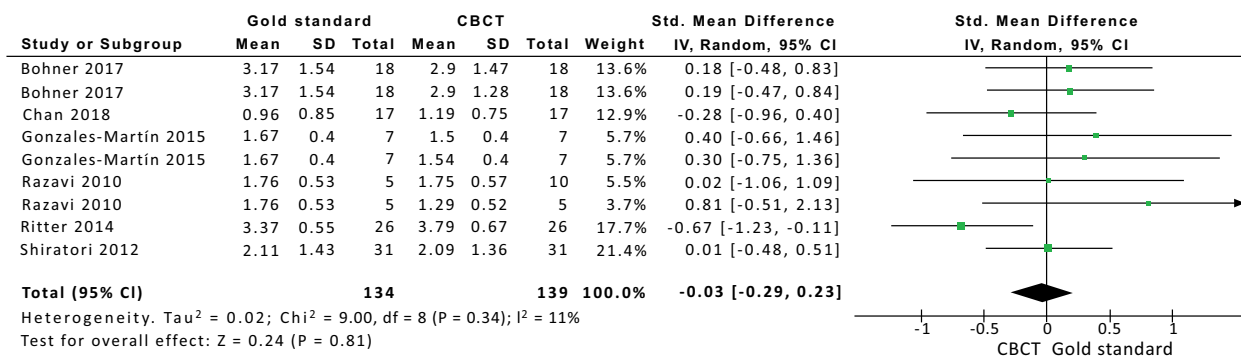


Fig. (3). Forest plot evaluating bone thickness determined by CBCT.

acceptable from a clinical point of view. Nonetheless, this accuracy seems to decrease as the bone becomes thinner. In this sense, Gonzales-Martín *et al.* (2015) [26] showed that in up to 63% of the cases, the buccal bone was not visible in CBCT images when the thickness was lower than 1mm. This statement is in agreement with the findings of Shiratori *et al.* (2012) [32], who attributed the mean deviation range of -0.02mm to 0.07mm to the bone volume variation. Accordingly, Razavi *et al.* (2010) [34] claimed that an underestimation of bone thickness occurred when this was thinner than 0.8mm.

The inaccuracy of CBCT assessment is related to the appearance of metal artifacts, which may hamper the visualization of bone-implant contact [38]. Furthermore, exposure parameters and partial effect may affect the image accuracy [14]. In this sense, better accuracy is provided when the image resolution is increased by using a lower voxel size [28, 31].

With regard to ultrasound-based techniques, these provide real-time images without involving radiation, which may be considered an advantage of the technique for periodical assessment of peri-implant bone. Out of the included studies, 4 of them used a high-frequency US-transducer to scan hard tissue. Although studies reported that US can measure bone dimensions with an accuracy similar to CBCT, this is a sensitive technique, which can lead to distortions of the final image [18, 30, 39]. Thus, further studies are required to improve its use during clinical practice.

The included studies assessed only dental implants fully covered by bone. An important limitation of this study was that it did not take into consideration the presence of dehiscence or fenestrations, which could affect the results. Furthermore, the results described in this review are limited to in-vitro studies. The lack of clinical studies relative to this issue is possibly related to the need for a high number of cases to provide statistically significant results. Thus, there is a limitation to conducting this type of study design in agreement with the ALARA principle [16]. However, in a clinical situation, factors

related to patient movements could also affect image resolution.

This review aimed to help clinicians to understand the advantages and limitations of the imaging methods currently available for the assessment of peri-implant bone. However, it must be emphasized that the choice of imaging technique depends on the patient's need, professional preference and the additional benefits provided by the examination. Factors such as radiation dose, costs and individual needs must be taken into consideration in future researches [40].

CONCLUSION

- CBCT showed an acceptable accuracy for assessing peri-implant buccal bone thickness.
- US showed an accuracy similar to that of CBCT in all evaluated studies.
- Due to the lack of studies in the literature, no conclusion could be drawn with respect to other techniques.

CONSENT FOR PUBLICATION

Not applicable.

STANDARD FOR REPORTING

PRISMA guidelines and methodology were followed.

FUNDING

None.

CONFLICT OF INTEREST

The authors declare no conflict of interest, financial or otherwise.

ACKNOWLEDGEMENTS

Declared none.

Appendix 1. Excluded articles and reason.

Author, Year	Exclusion criteria
Azevedo-Vaz <i>et al</i> 2013	3
Azevedo-Vaz <i>et al</i> 2013b	3
Azevedo-Vaz <i>et al</i> 2013c	3
Azevedo-Vaz <i>et al</i> 2016	3
Becker <i>et al</i> 2015	2
Benic <i>et al</i> 2012	4
Borg <i>et al</i> 2000	3
Bousquet <i>et al</i> 2007	2
Bousquet <i>et al</i> 2008	2
Bridcut <i>et al</i> 2001	2
Choi <i>et al</i> 2012	3
Dave <i>et al</i> 2012	3
Draenert <i>et al</i> 2007	2
Duttenhoefer <i>et al</i> 2015	2
Fienitz <i>et al</i> 2011	3

Author, Year	Exclusion criteria
Fourmoussis <i>et al</i> 1994	2
Gher <i>et al</i> 1995	3
Garcia-Garcia <i>et al</i> 2016	3
Golubovic <i>et al</i> 2012	3
Gonzales-Garcia <i>et al</i> 2013	2
González-Martin <i>et al</i> 2016	3
Grondhal <i>et al</i> 1997	2
Kamburoglu <i>et al</i> 2014	3
Kavadella <i>et al</i> 2006	3
Kuhl <i>et al</i> 2015	3
King <i>et al</i> 2002	2
Linrachtamorn <i>et al</i> 2000	1
Ludlow <i>et al</i> 1995	2
Mangione <i>et al</i> 2013	2
Matsuda <i>et al</i> 2001	2
Meijer <i>et al</i> 1993	2
Meijer <i>et al</i> 1995	2
Mengel <i>et al</i> 2006	3
Merheb <i>et al</i> 2015	2
Miyamoto <i>et al</i> 2011	2
Ogusanglu <i>et al</i> 2012	2
Pasquet <i>et al</i> 2009	1
Pauwels <i>et al</i> 2014	2
Pinheiro <i>et al</i> 2015	3
Pinheiro 2015b	3
Raes <i>et al</i> 2013	2
Rashedi <i>et al</i> 2003	2
Reddy <i>et al</i> 1994	2
Sanchez <i>et al</i> 2004	2
Schliephake <i>et al</i> 2013	3
Sennerby <i>et al</i> 2001	4
Sewerin <i>et al</i> 1997	3
Shokri <i>et al</i> 2015	2
Sirin <i>et al</i> 2012	3
Slak <i>et al</i> 2014	1
Sundén <i>et al</i> 1995	2
Svenson <i>et al</i> 1996	3
Van Oossterwyck, <i>et al</i> 2000	4
Vandeweghe <i>et al</i> 2013	4
Wang <i>et al</i> 2013	3
Wang <i>et al</i> 2013b	1
Webber <i>et al</i> 1996	2
Zechner <i>et al</i> 2003	2
Dagassan-Berndt <i>et al</i>	3
Tang <i>et al</i>	3
Vidor <i>et al</i>	3
Vidor <i>et al</i>	3
Peterson <i>et al</i>	3
Mercado <i>et al</i>	3
Flügge <i>et al</i>	3
Sheikhi <i>et al</i>	3
Yen <i>et al</i>	3
Chan <i>et al</i>	3
Chan <i>et al</i>	3

Author, Year	Exclusion criteria
Salmon <i>et al</i>	3

1. Case reports, reviews, letters, abstracts; 2. Studies that did not compare the accuracy of imaging techniques with the gold-standard (histology or direct measurements); 3. Studies that did not evaluate the bone dimension or did not present data enough to calculate them; 4. Studies that evaluated methods not reliable for clinical use.

REFERENCES

- [1] Jung RE, Zembic A, Pjetursson BE, Zwahlen M, Thoma DS. Systematic review of the survival rate and the incidence of biological, technical, and aesthetic complications of single crowns on implants reported in longitudinal studies with a mean follow-up of 5 years. *Clin Oral Implants Res* 2012; 23(Suppl. 6): 2-21. [http://dx.doi.org/10.1111/j.1600-0501.2012.02547.x] [PMID: 23062124]
- [2] Slatger KW, Meijer HJ, Bakker NA, Vissink A, Raghoobar GM. Immediate single-tooth implant placement in bony defects in the esthetic zone: A 1-year randomized controlled trial. *J Periodontol* 2016; 87(6): 619-29. [http://dx.doi.org/10.1902/jop.2016.150417] [PMID: 26876349]
- [3] Buser D, Bornstein MM, Weber HP, Grütter L, Schmid B, Belser UC. Early implant placement with simultaneous guided bone regeneration following single-tooth extraction in the esthetic zone: a cross-sectional, retrospective study in 45 subjects with a 2- to 4-year follow-up. *J Periodontol* 2008; 79(9): 1773-81. [http://dx.doi.org/10.1902/jop.2008.080071] [PMID: 18771381]
- [4] Buser D, Halbritter S, Hart C, *et al*. Early implant placement with simultaneous guided bone regeneration following single-tooth extraction in the esthetic zone: 12-month results of a prospective study with 20 consecutive patients. *J Periodontol* 2009; 80(1): 152-62. [http://dx.doi.org/10.1902/jop.2009.080360] [PMID: 19228101]
- [5] Merheb J, Van Assche N, Coucke W, Jacobs R, Naert I, Quirynen M. Relationship between cortical bone thickness or computerized tomography-derived bone density values and implant stability. *Clin Oral Implants Res* 2010; 21(6): 612-7. [http://dx.doi.org/10.1111/j.1600-0501.2009.01880.x] [PMID: 20666788]
- [6] Buser D, Chappuis V, Bornstein MM, Wittneben JG, Frei M, Belser UC. Long-term stability of contour augmentation with early implant placement following single tooth extraction in the esthetic zone: a prospective, cross-sectional study in 41 patients with a 5- to 9-year follow-up. *J Periodontol* 2013; 84(11): 1517-27. [http://dx.doi.org/10.1902/jop.2013.120635] [PMID: 23347346]
- [7] Hsu JT, Fuh LJ, Tu MG, Li YF, Chen KT, Huang HL. The effects of cortical bone thickness and trabecular bone strength on noninvasive measures of the implant primary stability using synthetic bone models. *Clin Implant Dent Relat Res* 2013; 15(2): 251-61. [http://dx.doi.org/10.1111/j.1708-8208.2011.00349.x] [PMID: 21599830]
- [8] Demircan S, Demircan E. Dental Cone Beam Computed Tomography Analyses of the Anterior Maxillary Bone Thickness for Immediate Implant Placement. *Implant Dent* 2015; 24(6): 664-8. [http://dx.doi.org/10.1097/ID.0000000000000340] [PMID: 26460741]
- [9] Benic GI, Mokti M, Chen CJ, Weber HP, Hämmerle CH, Gallucci GO. Dimensions of buccal bone and mucosa at immediately placed implants after 7 years: a clinical and cone beam computed tomography study. *Clin Oral Implants Res* 2012; 23(5): 560-6. [http://dx.doi.org/10.1111/j.1600-0501.2011.02253.x] [PMID: 22093013]
- [10] Tey VH, Phillips R, Tan K. Five-year retrospective study on success, survival and incidence of complications of single crowns supported by dental implants. *Clin Oral Implants Res* 2016. [PMID: 27334865]
- [11] Chappuis V, Araújo MG, Buser D. Clinical relevance of dimensional bone and soft tissue alterations post-extraction in esthetic sites. *Periodontol* 2000 2017; 73(1): 73-83. [http://dx.doi.org/10.1111/prd.12167] [PMID: 28000281]
- [12] Ritter L, Elger MC, Rothamel D, *et al*. Accuracy of peri-implant bone evaluation using cone beam CT, digital intra-oral radiographs and histology. *Dentomaxillofac Radiol* 2014; 43(6):20130088 [http://dx.doi.org/10.1259/dmfr.20130088] [PMID: 24786136]
- [13] Chappuis V, Bornstein MM, Buser D, Belser U. Influence of implant neck design on facial bone crest dimensions in the esthetic zone analyzed by cone beam CT: a comparative study with a 5-to-9-year follow-up. *Clin Oral Implants Res* 2015. [PMID: 26370904]
- [14] Scarfe WC, Farman AG. What is cone-beam CT and how does it work? *Dent Clin North Am* 2008; 52(4): 707-730, v. [http://dx.doi.org/10.1016/j.cden.2008.05.005] [PMID: 18805225]
- [15] Behnia H, Motamedian SR, Kiani MT, Morad G, Khojasteh A. Accuracy and reliability of cone beam computed tomographic measurements of the bone labial and palatal to the maxillary anterior teeth. *Int J Oral Maxillofac Implants* 2015; 30(6): 1249-55. [http://dx.doi.org/10.11607/jomi.3856] [PMID: 26478968]
- [16] Hendee WR, Edwards FM. ALARA and an integrated approach to radiation protection. *Semin Nucl Med* 1986; 16(2): 142-50. [http://dx.doi.org/10.1016/S0001-2998(86)80027-7] [PMID: 3961515]
- [17] Bornstein MM, Scarfe WC, Vaughn VM, Jacobs R. Cone beam computed tomography in implant dentistry: a systematic review focusing on guidelines, indications, and radiation dose risks. *Int J Oral Maxillofac Implants* 2014; 29(Suppl.): 55-77. [http://dx.doi.org/10.11607/jomi.2014suppl.g1.4] [PMID: 24660190]
- [18] Salmon B, Le Denmat D. Intraoral ultrasonography: development of a specific high-frequency probe and clinical pilot study. *Clin Oral Investig* 2012; 16(2): 643-9. [http://dx.doi.org/10.1007/s00784-011-0533-z] [PMID: 21380502]
- [19] Dutenhoefer F, Mertens ME, Vizkelety J, Gremse F, Stadelmann VA, Sauerbier S. Magnetic resonance imaging in zirconia-based dental implantology. *Clin Oral Implants Res* 2015; 26(10): 1195-202. [http://dx.doi.org/10.1111/clr.12430] [PMID: 24893967]
- [20] Wanner L, Ludwig U, Hövener JB, Nelson K, Flügge T. Magnetic resonance imaging-a diagnostic tool for postoperative evaluation of dental implants: a case report. *Oral Surg Oral Med Oral Pathol Oral Radiol* 2018; 125(4): e103-7. [http://dx.doi.org/10.1016/j.oooo.2018.01.005] [PMID: 29501353]
- [21] Benic GI, Elmasy M, Hämmerle CH. Novel digital imaging techniques to assess the outcome in oral rehabilitation with dental implants: a narrative review. *Clin Oral Implants Res* 2015; 26(Suppl. 11): 86-96. [http://dx.doi.org/10.1111/clr.12616] [PMID: 26010421]
- [22] Tahmaseb A, Wismeijer D, Coucke W, Derksen W. Computer technology applications in surgical implant dentistry: a systematic review. *Int J Oral Maxillofac Implants* 2014; 29(Suppl.): 25-42. [http://dx.doi.org/10.11607/jomi.2014suppl.g1.2] [PMID: 24660188]
- [23] Liberati A, Altman DG, Tetzlaff J, *et al*. The PRISMA statement for reporting systematic reviews and meta-analyses of studies that evaluate health care interventions: explanation and elaboration. *J Clin Epidemiol* 2009; 62(10): e1-e34. [http://dx.doi.org/10.1016/j.jclinepi.2009.06.006] [PMID: 19631507]
- [24] Whiting PF, Rutjes AW, Westwood ME, *et al*. QUADAS-2 Group. QUADAS-2: a revised tool for the quality assessment of diagnostic accuracy studies. *Ann Intern Med* 2011; 155(8): 529-36. [http://dx.doi.org/10.7326/0003-4819-155-8-201110180-00009] [PMID: 22007046]
- [25] Deeks JBBPGC. *Cochrane Handbook for Systematic Reviews of Diagnostic Test Accuracy* Version 09. The Cochrane Collaboration 2013.
- [26] González-Martín O, Oteo C, Ortega R, Alandez J, Sanz M, Veltri M. Evaluation of peri-implant buccal bone by computed tomography: an experimental study. *Clin Oral Implants Res* 2016; 27(8): 950-5. [http://dx.doi.org/10.1111/clr.12663] [PMID: 26178780]
- [27] Degen K, Habor D, Radermacher K, *et al*. Assessment of cortical bone thickness using ultrasound. *Clin Oral Implants Res* 2017; 28(5): 520-8. [http://dx.doi.org/10.1111/clr.12829] [PMID: 27018152]
- [28] Chan HL, Sinjab K, Li J, Chen Z, Wang HL, Kripfgans OD. Ultrasonography for noninvasive and real-time evaluation of peri-implant tissue dimensions. *J Clin Periodontol* 2018; 45(8): 986-95. [http://dx.doi.org/10.1111/jcpe.12918] [PMID: 29757464]
- [29] Bohner L, Habor D, Tortamano P, Radermacher K, Wolfart S, Marotti J. Assessment of Buccal Bone Surrounding Dental Implants Using a High-Frequency Ultrasound Scanner. *Ultrasound Med Biol* 2019; 45(6): 1427-34. [http://dx.doi.org/10.1016/j.ultrasmedbio.2019.02.002] [PMID: 30940417]
- [30] Marotti J, Neuhaus S, Habor D, *et al*. High-frequency ultrasound for assessment of peri-implant bone thickness. *J Clin Med* 2019; 8(10): 8. [http://dx.doi.org/10.3390/jcm8101539] [PMID: 31557872]
- [31] Sheridan RA, Chiang YC, Decker AM, Suthiboonyanan P, Chan HL,

- Wang HL. The effect of implant-induced artifacts on interpreting adjacent bone structures on cone-beam computed tomography scans. *Implant Dent* 2018; 27(1): 10-4. [http://dx.doi.org/10.1097/ID.0000000000000684] [PMID: 29095787]
- [32] Shiratori LN, Marotti J, Yamanouchi J, Chilvarquer I, Contin I, Tortamano-Neto P. Measurement of buccal bone volume of dental implants by means of cone-beam computed tomography. *Clin Oral Implants Res* 2012; 23(7): 797-804. [http://dx.doi.org/10.1111/j.1600-0501.2011.02207.x] [PMID: 21631591]
- [33] Bohner LOL, Tortamano P, Marotti J. Accuracy of linear measurements around dental implants by means of cone beam computed tomography with different exposure parameters. *Dentomaxillofac Radiol* 2017; 46(5):20160377 [http://dx.doi.org/10.1259/dmfr.20160377] [PMID: 28267928]
- [34] Razavi T, Palmer RM, Davies J, Wilson R, Palmer PJ. Accuracy of measuring the cortical bone thickness adjacent to dental implants using cone beam computed tomography. *Clin Oral Implants Res* 2010; 21(7): 718-25. [http://dx.doi.org/10.1111/j.1600-0501.2009.01905.x] [PMID: 20636726]
- [35] Raskó Z, Nagy L, Radnai M, Piffkó J, Baráth Z. Assessing the accuracy of cone-beam computerized tomography in measuring thinning oral and buccal bone. *J Oral Implantol* 2016; 42(3): 311-4. [http://dx.doi.org/10.1563/aid-joi-D-15-00188] [PMID: 26645480]
- [36] Liedke GS, Spin-Neto R, da Silveira HED, Schropp L, Stavropoulos A, Wenzel A. Accuracy of detecting and measuring buccal bone thickness adjacent to titanium dental implants-a cone beam computed tomography *in vitro* study. *Oral Surg Oral Med Oral Pathol Oral Radiol* 2018; 126(5): 432-8. [http://dx.doi.org/10.1016/j.oooo.2018.06.004] [PMID: 30126809]
- [37] Vanderstuyft T, Tarce M, Sanaan B, Jacobs R, de Faria Vasconcelos K, Quiryren M. Inaccuracy of buccal bone thickness estimation on cone-beam CT due to implant blooming: An *ex-vivo* study. *J Clin Periodontol* 2019; 46(11): 1134-43. [http://dx.doi.org/10.1111/jcpe.13183] [PMID: 31446644]
- [38] Degen K, Habor D, Radermacher K, Heger S, Kern JS, Wolfart S, *et al.* Assessment of cortical bone thickness using ultrasound. *Clin Oral Implants Res* 2016. [PMID: 27018152]
- [39] Choi M, Culjat MO, Singh RS, White SN. Ultrasound imagery for dental implant diagnosis and treatment planning in a porcine model. *J Prosthet Dent* 2012; 108(6): 344-53. [http://dx.doi.org/10.1016/S0022-3913(12)60190-5] [PMID: 23217466]
- [40] Bornstein MM, Al Nawas B, Kuchler U, Tahmaseb A. Consensus statements and recommended clinical procedures regarding contemporary surgical and radiographic techniques in implant dentistry. *Int J Oral Maxillofac Implants* 2013. [PMID: 23951565]

© 2020 Bohner *et al.*

This is an open access article distributed under the terms of the Creative Commons Attribution 4.0 International Public License (CC-BY 4.0), a copy of which is available at: (<https://creativecommons.org/licenses/by/4.0/legalcode>). This license permits unrestricted use, distribution, and reproduction in any medium, provided the original author and source are credited.