

BOLD Myocardial Imaging: Advances for Clinical and Physiological Applications

Sanjit Peter and Garth M. Beache*

Department of Radiology, University of Louisville School of Medicine, Louisville, Kentucky, USA

Abstract: Blood oxygenation level-dependent (BOLD) imaging is firmly established as a powerful tool for clinical and research studies in the brain. Though, borrowing from the brain methodology, the technique was early adapted for the heart, due to artifacts unique to myocardial imaging; cardiac and respiratory motion, flow and blood pool effects, and magnetic susceptibility effects arising from the adjacent lungs and bowel, and from the veins at the surface of the heart, cardiac application has largely been limited to research groups. In this paper we aim to focus on these factors affecting ease and reliability of BOLD myocardial imaging, and highlight advances which have the potential to make this methodology more widely accessible to clinical- and physiology- based practitioners who may have an interest in exploring this area in collaboration with technical magnetic resonance imaging colleagues

Keywords: BOLD, myocardium, coronary artery disease, metabolic syndrome, endothelium, magnetic resonance imaging.

BOLD MECHANISM

Myocardial blood oxygenation level- dependent (BOLD) imaging was early investigated by several groups [1-3]. The BOLD mechanism exploits the property that deoxyhemoglobin is paramagnetic while oxyhemoglobin is not [4]. At the microvasculature level, deoxyhemoglobin is compartmentalized within the erythrocytes, and also with respect to the intravascular *vs.* the extravascular space. This compartmentalization effectively results in heterogeneity of the local magnetic field environment, and which in turn leads to dephasing of spins of the imaged volume element, and an observed signal loss, using pulse sequences sensitized to field inhomogeneities [5].

An initial motivation for exploration of myocardial BOLD imaging in humans was to develop a methodology to index the delivery of blood (and oxygen) to the tissue microvasculature bed, without the costs, or the risks of gadolinium (Gd)-based contrast agent [3, 6]. In addition, unlike the first-pass delivery of extracellular contrast agent, which is a transient effect [7], BOLD imaging permits temporal averaging of the oxygenation status of the myocardium. In that regard the BOLD method has the potential to be more reliable than first-pass transit techniques.

EARLY TECHNIQUE: T2* IMAGING

An early approach to achieve BOLD sensitivity used T2*, multi-echo, segmented k-space imaging [8], however this approach suffered from regional variability of the BOLD effect in normal myocardium, owing largely to flow artifact arising from the ventricular cavities, the veins at the epicardial surface, particularly the posterior vein of the left

ventricle, and susceptibility effects occurring at the lung-heart interface and from air within adjacent bowel [9]. These techniques, however, proved useful in practice when combined with specialized saturation pulses to null ventricular blood, and inversion pulses to further minimize flow artifact.

PHYSIOLOGICAL IMAGING WITH BOLD

An important conceptual advance was the recognition of the ability to characterize myocardial physiology by combining the BOLD effect with manipulation of the microvasculature oxygenation environment, using drugs that modulate hemodynamics.

Zhang *et al.* conducted a BOLD study at 1.5 Tesla (T), using a dog model of coronary stenosis, with microsphere documentation of flow [10]. They investigated a BOLD index related to oxygen extraction fraction (OEF), and BOLD signal change in response to dipyridamole-induced maximal hyperemia. They documented that regional OEF was increased (0.43 +/- 0.12 *vs.* 0.21 +/- 0.11, normal), and BOLD signal change was decreased (3.06 +/- 2.74 % *vs.* 10.19 +/- 4.12 %, normal) in segments corresponding to a stenosed vessel.

Beache *et al.* investigated BOLD physiological imaging in a model of global myocardial disease, using a segmented gradient echo sequence, with multiple echo times, at 1.5T [11]. Special preparation pulses were applied to minimize blood pool, and flow artifacts, and thus improve the reliability of quantitative estimates. Their physiological protocol consisted of multiple T2*-acquisitions in the baseline state, and multiple acquisitions at maximal hyperemia, following a standard clinical dose of dipyridamole (Fig. 1). The choice of a global disease model avoided problems with regional variability related to technical limitations. In particular T2* corresponding to the 3 major vascular territories, in large mid-wall regions-of-interest (ROI's), was tracked temporally during the physiological protocol (Fig. 2). Spatial

*Address correspondence to this author at the Department of Radiology, University of Louisville School of Medicine, 530 South Jackson Street, Louisville, KY 40202, Kentucky, USA; Tel: (502) 852-2113; Fax: (502) 852-1754; E-mail: gbeache1@aol.com

averaging across ROI's, and temporal averaging in a given oxygenation state (rest vs. maximal hyperemia) were subsequently performed. In a study of 9 healthy controls and

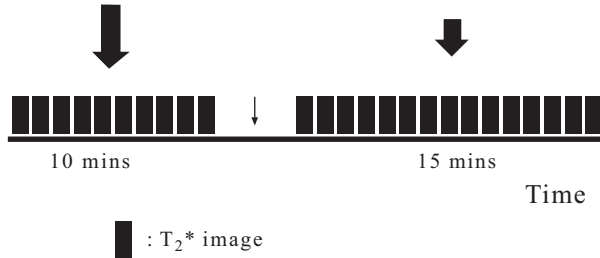


Fig. (1). Schematic of the physiological imaging protocol. Repeated BOLD T₂^{*}, breath-held acquisition was performed of a single image-section in each of the baseline (longer thick arrow), and maximal vasodilation (shorter thick arrow), oxygenation states. An image was acquired approximately at 1 minute intervals, to not tire the patient. Timing of dipyrindamole administration is indicated by the thin arrow. Maximal vasodilation was achieved using a typical clinical dipyrindamole dose; 0.56 mg/kg (total), infused over 4 minutes. This protocol permits temporal averaging of BOLD signal intensities corresponding to each of the 2 oxygenation states, to provide a robust measure characterizing each state. We used as our physiological index, signal change in response to maximal vasodilator-induced hyperemia (vasodilator responsiveness).

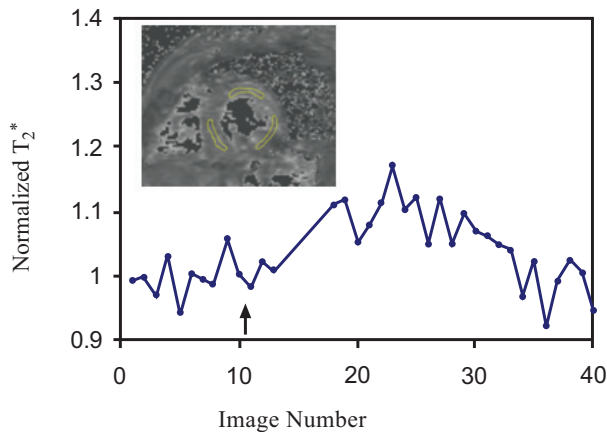


Fig. (2). BOLD signal intensity-time series curve. A short axis image section of the heart within the thoracic cavity, acquired during end-expiratory breath holding, is shown, inset. Three intramyocardial regions-of-interest (ROI's), approximating the 3 major vascular territories are outlined. Signal corresponding to each of the ROI's was tracked temporally, over the course of the physiological protocol. Because of in-plane rigid body motion from image frame to image frame, due to cardiac motion, and end-respiration irreproducibility, a registration technique was employed. Nonetheless there remained variability of the BOLD signal corresponding to each of the oxygenation states, including in the pre-drug administration, baseline state. This is the motivation for utilization of temporal averaging, for a given physiological state, when estimating the signal change. In this global disease model, we confirmed no statistical difference of the observed vasodilator responsiveness among regions, which permitted us to average the 3 ROI signal intensities for each time frame, and thus generate a single time series curve. Corresponding to the dipyrindamole effect, one can observe the declining effect of the drug over a period of about ½ hour.

10 patients with hypertension and myocardial hypertrophy, they documented a 3-fold decrease of the BOLD vasodilator response to dipyrindamole-induced maximal hyperemia, in the patient group. Representative signal-intensity (SI) time series curves are shown in Fig. (3). These results are of broader relevance since a major pathomechanism underlying this disease is believed to be related to an abnormality of microvasculature vasoregulatory function [12]. Hypertension is thought to be among a class of conditions comprising the insulin metabolism syndrome, which also includes a wide spectrum of conditions, including central obesity, dyslipidemia, type 2 diabetes, atherosclerosis, and heart failure, and thus the method may hold promise to explore this wider group of conditions [13].

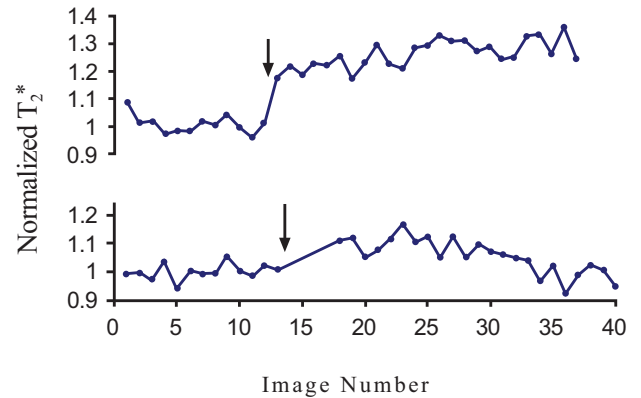


Fig. (3). Time series curves comparing a representative healthy control (at top), to a representative patient (at bottom). The arrow indicates the period of dipyrindamole infusion. Typical vasodilator responsiveness was about 18 % in the healthy controls. Typical standard deviation of the signal intensity of the baseline images, in normals, was ~5%. Thus for the healthy controls, vasodilator responsiveness was sufficiently large, (overcoming the baseline variability by a factor of 3), to provide reliable estimates of signal change. Compared to healthy controls, vasodilator responsiveness was significantly reduced in patients.

IMAGING SEGMENTAL CAD

Although the potential to image the global, functional microvasculature abnormality in the insulin metabolism syndrome is quite intriguing, the primary object of adult cardiac imaging remains coronary artery disease (CAD), which affects the myocardium in a segmental fashion. Freidrich *et al.*, investigated the utility of a T₂^{*} echo planar imaging technique at 1.5T. In a study of 25 CAD patients, with quantitative angiography and thallium SPECT validation, they documented the ability to detect a relative reduced response to adenosine induced maximal hyperemia, in segments with significant (> 75%) stenoses [14]. Image artifacts likely affected the ability to reliably characterize less severe disease in this study.

Egred and colleagues have recently investigated the utility of BOLD imaging in coronary artery disease, in patients. They studied 12 patients with myocardial ischemia documented by SPECT nuclear imaging [15]. BOLD imaging was done at rest, and during dipyrindamole induced maximal hyperemia, using T₂^{*}-weighted sequences on a 0.95 T system. In addition, they acquired wall thickening

data using magnetic resonance imaging (MRI), a sensitive indicator of ischemia. They found the BOLD signal change in response to hyperemia was -10.3 (± 14.7) %, for the non ischemic segments, and -13.8 (± 16.3) %, for ischemic segments. Corresponding wall thickening was 8.7 (± 3.8) mm, for non ischemic segments, and 6.4 (± 3.4), for diseased. Though an important clinical step, the fact that the standard deviation is bigger than the mean for the BOLD data suggests that the BOLD quantitative estimates may have been affected by lack of specialized techniques to suppress artifact from blood flow effects, and artifact arising from the ventricular cavity. This might explain, at least in part, why segments showing adequate wall thickening changes, manifested a smaller vasodilator BOLD response than segments with reduced wall thickening changes (and thus presumed ischemic).

TECHNICAL ADVANCES TO MINIMIZE ARTIFACT

Limitations associated with T2* techniques (including low signal-to-noise ratios; magnetic field inhomogeneities due to the epicardial cardiac veins, and also at the heart-lung interface and arising from adjacent bowel; blood flow; cardiac and respiratory motion) are now well recognized [9,16], and several groups have implemented research programs to overcome these difficulties.

The laboratory of Li *et al.*, has done extensive work exploring techniques that combine T2 preparation pulses, that avoid artifacts associated with use of a long repetition time (TR) parameter to achieve BOLD sensitivity, along with steady state free precession (SSFP) readouts to improve image quality. In an early study, at 1.5T, they investigated 13 canines, with a surgical preparation that included a variable occluder placed in the circumflex coronary [17]. Validation of flow status of the myocardium was via microspheres. BOLD signal change and flow change, in response to maximal vasodilatation induced by adenosine, were indexed. Signal change differences were clearly visually depicted between the circumflex myocardial territory, and the left anterior descending used as a control. In addition, there was good agreement by linear regression analysis between the BOLD signal change and flow change ($R=0.80$, $P<0.01$).

Huang and colleagues have now also investigated a fast, motion insensitive T2 magnetization method, with SSFP readout before achieving the steady state. In this fashion they created absolute T2 relaxation maps of the myocardium [18]. Respiratory navigation was also employed to afford averaging of repeated measurements for a given oxygenation state. In a study of 12 healthy participants, at 1.5T, estimated T2 relaxation of myocardium was 54 ± 5.7 ms. Regional variation, among vascular territories, was 7%. Temporal variability (in a 0.5 cc transmural volume), in the resting state, was 3.6 %, leading to the ability to reliably detect a minimum T2 change corresponding to a 2-fold flow response. These improvements over alternative T2* methods (with which one could reliably detect a minimum 3-fold response), suggest that T2-preparation SSFP techniques have the regional homogeneity, and the temporal reproducibility to afford robust human imaging, in segmental diseases, such as coronary artery disease, as well as global conditions such as the insulin metabolism syndrome.

Arumana, Li, and, Dharmakumar have recently explored a SSFP method, without T2 preparation, that consists of a steady state acquisition, and a phase-cycled RF pulse (which has BOLD sensitivity). The technique termed phase-cycled SSFP is designed to further improve reliability, by reducing acquisition times and improving SNR. An initial study was done at both 1.5T and 3T in a model of ischemia in leg muscle, and also compared with theoretical simulations [19]. The data documented greater response to maximal hyperemia, and also less temporal variability in a given oxygenation state, of the phase-cycle method than both the T2-preparation method, and the T2* weighted method, at both 1.5T and 3T, with optimized imaging parameters. This would suggest greater reliability in estimating pharmacologically induced BOLD signal changes. In another study in 8 dogs, using their well validated model of coronary stenosis and myocardial ischemia, the investigators explored phase-cycled SSFP at 1.5T [20]. Myocardial oxygenation changes induced by adenosine, with varying degrees of stenosis, were documented to correlate with flow changes indexed using microspheres ($r=0.80$, $P<0.01$). Work on this method, while of great promise, awaits more widespread evaluation.

3T IMAGING

Although both the BOLD vasodilator responsiveness and physiological noise effects would be expected to scale with some power of the field strength thus making the exact dependence of the desired clinical effect on field strength non-linear [21], it would be anticipated that given the typical low signal to noise ratio of BOLD images, the BOLD methodology would over-all benefit from going to higher field strengths.

Dharmakumar *et al.*, have investigated phase-cycled SSFP BOLD acquisitions (without T2 preparation) at 1.5T vs. 3T, using theoretical simulations, and experimental preparations (namely, their dog model of stenosis), correlated with microsphere indexed flow [22]. These data revealed that the flow response to maximal hyperemia was increased by a factor of 2.5, comparing 3T vs. 1.5T. In addition, the minimum relative flow deficit detectable (in stenosed compared to healthy regions), was 1.6 at 3T vs. 2.9 at 1.5T, or approaching the clinically relevant reduction of a factor of 2 (i.e. a 50% reduction), for distinguishing significantly stenosed territories, compared to normal segments [23].

Overall, BOLD MRI continues to undergo investigations to improve the reliability of the imaging technique and to aid in the understanding of the underlying physiological mechanisms [24-26].

SUMMARY

Early myocardial BOLD imaging studies, primarily using T2* imaging, were plagued by low SNR, and blood pool and flow artifact. Recent technical developments, originating with T2-preparation with SSFP readout, have sufficiently improved reliability to make clinical imaging in both

segmental diseases, such as coronary artery disease, and global conditions, such as comprise the insulin metabolism syndrome, accessible beyond research labs. Much exciting

clinical studies, and translational research remain to be done using this physiologically-based, non-invasive myocardial technique.

CONFLICT OF INTEREST

None declared.

ACKNOWLEDGEMENT

Dr. Beache's research was supported, in part, by The University of Louisville Clinical and Translational Science Pilot Grant Program.

REFERENCES

- [1] Atalay MK, Forder JR, Chacko VP, Kawamoto S, Zerhouni EA. Oxygenation in the rabbit myocardium: assessment with susceptibility-dependent MR imaging. *Radiology* 1993; 189: 759-64.
- [2] Wacker CM, Hartlep AW, Pflieger S, Schad LR, Ertl G, Bauer WR. Susceptibility-sensitive magnetic resonance imaging detects human myocardium supplied by a stenotic coronary artery without a contrast agent. *J Am Coll Cardiol* 2003; 41: 834-40.
- [3] Niemi P, Poncelet BP, Kwong KK, *et al.* Myocardial intensity changes associated with flow stimulation in blood oxygenation sensitive magnetic resonance imaging. *Magn Reson Med* 1996; 36: 78-82.
- [4] Thulborn KR, Waterton JC, Mathews PM, Radda GK. Oxygenation dependence of the transverse relaxation time of water protons in whole blood at high field. *Biochim Biophys Acta* 1982; 714: 265-70.
- [5] Weisskoff RM, Zuo CS, Boxerman JL, Rosen BR. Microscopic susceptibility variation and transverse relaxation: theory and experiment. *Magn Reson Med* 1994; 31: 601-10.
- [6] Marckmann P, Skov L, Rossen K, *et al.* Nephrogenic systemic fibrosis: suspected causative role of gadodiamide used for contrast-enhanced magnetic resonance imaging. *J Am Soc Nephrol* 2006; 17: 2359-62.
- [7] Arai AE. Magnetic resonance first-pass myocardial perfusion imaging. *Top Magn Reson Imaging* 2000; 11: 383-98.
- [8] Reeder SB, Atalar E, Faranesh AZ, McVeigh ER. Multi-echo segmented k-space imaging: an optimized hybrid sequence for ultrafast cardiac imaging. *Magn Reson Med* 1999; 41: 375-85.
- [9] Reeder SB, Faranesh AZ, Boxerman JL, McVeigh ER. *In vivo* measurement of T2* and field inhomogeneity maps in the human heart at 1.5 T. *Magn Reson Med* 1998; 39: 988-98.
- [10] Zhang H, Gropler RJ, Li D, Zheng J. Assessment of myocardial oxygen extraction fraction and perfusion reserve with BOLD imaging in a canine model with coronary artery stenosis. *J Magn Reson Imaging* 2007; 26: 72-9.
- [11] Beache GM, Herzka DA, Boxerman JL, *et al.* Attenuated myocardial vasodilator response in patients with hypertensive hypertrophy revealed by oxygenation-dependent magnetic resonance imaging. *Circulation* 2001; 104: 1214-7.
- [12] Treasure CB, Klein JL, Vita JA, *et al.* Hypertension and left ventricular hypertrophy are associated with impaired endothelium-mediated relaxation in human coronary resistance vessels. *Circulation* 1993; 87: 86-93.
- [13] Haffner SM, Mietinen H. Insulin resistance implications for type II diabetes mellitus and coronary heart disease. *Am J Med* 1997; 103: 152-62.
- [14] Friedrich MG, Niendorf T, Schulz-Menger J, Gross CM, Dietz R. Blood oxygen level-dependent magnetic resonance imaging in patients with stress-induced angina. *Circulation* 2003; 108: 2219-23.
- [15] Egred M, Waiter GD, Redpath TW, Semple SK, Al-Mohammad A, Walton S. Blood oxygen level-dependent (BOLD) MRI: A novel technique for the assessment of myocardial ischemia as identified by nuclear imaging SPECT. *Eur J Intern Med* 2007; 18: 581-6.
- [16] Atalay MK, Poncelet BP, Kantor HL, Brady TJ, Weisskoff RM. Cardiac susceptibility artifacts arising from the heart-lung interface. *Magn Reson Med* 2001; 45: 341-5.
- [17] Fieno DS, Shea SM, Li Y, Harris KR, Finn JP, Li D. Myocardial perfusion imaging based on the blood oxygen level-dependent effect using T2-prepared steady-state free-precession magnetic resonance imaging. *Circulation* 2004; 110: 1284-90.
- [18] Huang TY, Liu YJ, Stemmer A, Poncelet BP. T2 measurement of the human myocardium using a T2-prepared transient-state TrueFISP sequence. *Magn Reson Med* 2007; 57: 960-6.
- [19] Arumana JM, Li D, Dharmakumar R. Deriving blood-oxygen-level-dependent contrast in MRI with T2*-weighted, T2-prepared and phase-cycled SSFP methods: theory and experiment. *Magn Reson Med* 2008; 59: 561-70.
- [20] Dharmakumar R, Arumana JM, Larson AC, Chung Y, Wright GA, Li D. Cardiac phase-resolved blood oxygen-sensitive steady-state free precession MRI for evaluating the functional significance of coronary artery stenosis. *Invest Radiol* 2007; 42: 180-8.
- [21] Duong TQ, Yacoub E, Adriany G, Hu X, Ugurbil K, Kim SG. Microvascular BOLD contribution at 4 and 7 T in the human brain: gradient-echo and spin-echo fMRI with suppression of blood effects. *Magn Reson Med* 2003; 49: 1019-27.
- [22] Dharmakumar R, Arumana JM, Tang R, Harris K, Zhang Z, Li D. Assessment of regional myocardial oxygenation changes in the presence of coronary artery stenosis with balanced SSFP imaging at 3.0 T: theory and experimental evaluation in canines. *J Magn Reson Imaging* 2008; 27: 1037-45.
- [23] Klocke FJ, Simonetti OP, Judd RM, *et al.* Limits of detection of regional differences in vasodilated flow in viable myocardium by first-pass magnetic resonance perfusion imaging. *Circulation* 2001; 104: 2412-6.
- [24] Zhou X, Tsiftaris SA, Liu Y, *et al.* Artifact-reduced two-dimensional cine steady state free precession for myocardial blood-oxygen-level-dependent imaging. *J Magn Reson Imaging* 2010; 31: 863-71.
- [25] Vöhringer M, Flewitt JA, Green JD, *et al.* Oxygenation-sensitive CMR for assessing vasodilator-induced changes of myocardial oxygenation. *J Cardiovasc Magn Reson* 2010; 12: 20.
- [26] McCommis KS, Koktzoglou I, Zhang H, *et al.* Improvement of hyperemic myocardial oxygen extraction fraction estimation by a diffusion-prepared sequence. *Magn Reson Med* 2010; 63: 1675-82.

Received: December 29, 2010

Revised: January 18, 2012

Accepted: January 20, 2012

© Peter and Beache; Licensee *Bentham Open*.

This is an open access article licensed under the terms of the Creative Commons Attribution Non-Commercial License (<http://creativecommons.org/licenses/by-nc/3.0/>), which permits unrestricted, non-commercial use, distribution and reproduction in any medium, provided the work is properly cited.