

**Disclaimer:** This article has been published immediately upon acceptance (by the Editors of the journal) as a provisional PDF from the revised version submitted by the authors(s). The final PDF version of this article will be available from the journal URL shortly after approval of the proofs by authors(s) and publisher.

## A Case of Encephalopathy in an Immunocompetent Adult with Persistent Parvovirus B19 Viremia

Ariel Antezana\*, Ilya Kister and Joseph Herbert

*The Open Neurology Journal, Volume 9, 2015*

**ISSN:** 1874-205X/15

**DOI:** 10.2174/1874205X20150520E001

**Article Type:** Review Article

**Received:** January 22, 2015

**Revised:** March 25, 2015

**Accepted:** April 02, 2015

**Provisional PDF Publication Date:** May 20, 2015

© Antezana *et al.*; Licensee Bentham Open.

This is an open access article licensed under the terms of the Creative Commons Attribution Non-Commercial License (<http://creativecommons.org/licenses/by-nc/3.0/>) which permits unrestricted, non-commercial use, distribution and reproduction in any medium, provided the work is properly cited.

## **A Case of Encephalopathy in an Immunocompetent Adult with Persistent Parvovirus B19 Viremia**

**Short Title:** Encephalopathy after parvovirus B19 exposure.

Name:

Ariel Antezana

Email:

antezana.neuromed@gmail.com

Affiliation:

Neuromedical Clinic of Central Louisiana

Name:

Ilya Kister

Email:

ilya.kister@nyumc.org

Affiliation:

NYU Multiple Sclerosis Center

Name:

Joseph Herbert

Email:

joseph.herbert@nyumc.org

Affiliation:

NYU Multiple Sclerosis Center

### **Abstract**

Parvovirus B19 (PVB19) is a ubiquitous airborne virus; it is well known to cause erythema infectiosum (fifth disease) in children. Neurologic complications after PVB19 exposure are thought to be transitory and infrequent in the adult population. Herein, we report an interesting case of a young woman who developed cognitive deficits, white matter changes and persisting viremia for over a year after exposure to PVB19.

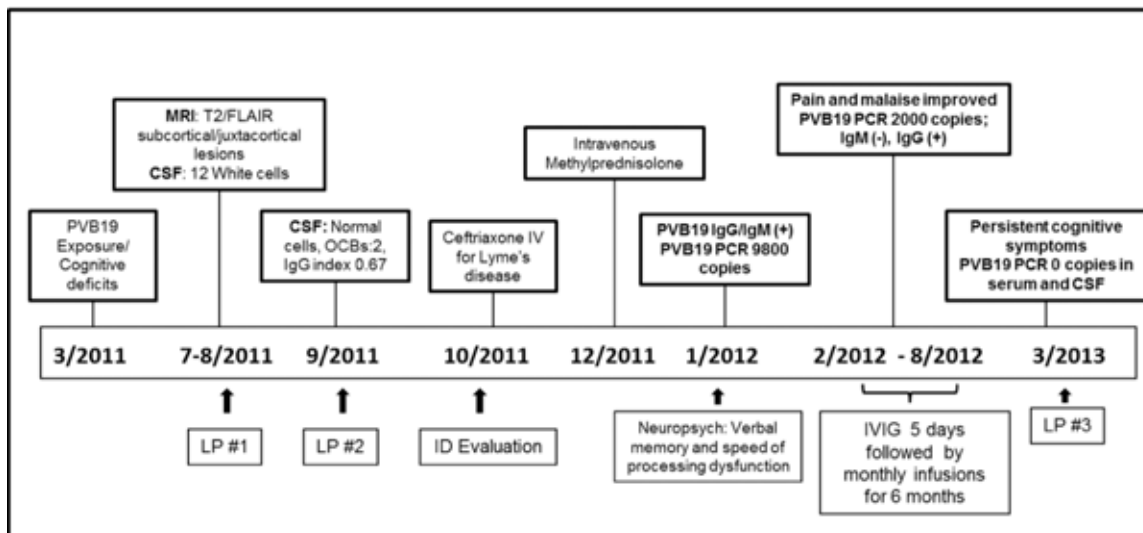
### **Key Words:**

Parvovirus B19, encephalopathy, white matter changes, cognitive deficits.

## Clinical Presentation

A previously healthy 33 year-old woman developed cognitive deficits, dizziness, arthralgias and myalgias a few days after her daughter was diagnosed with Fifth disease (parvovirus B19, PVB19). She had no fever, headache and meningismus. The patient was referred for neurologic consultation after her cognitive symptoms persisted and she was fired from office job. Neurologic exam was unremarkable, but neuropsychological testing confirmed a variety of cognitive deficits, predominantly in areas of speed of processing, attention, working and verbal memory. Timeline of disease course, treatments, testing is shown in Figure 1.

**Figure 1. Timeline of disease course and treatments.**

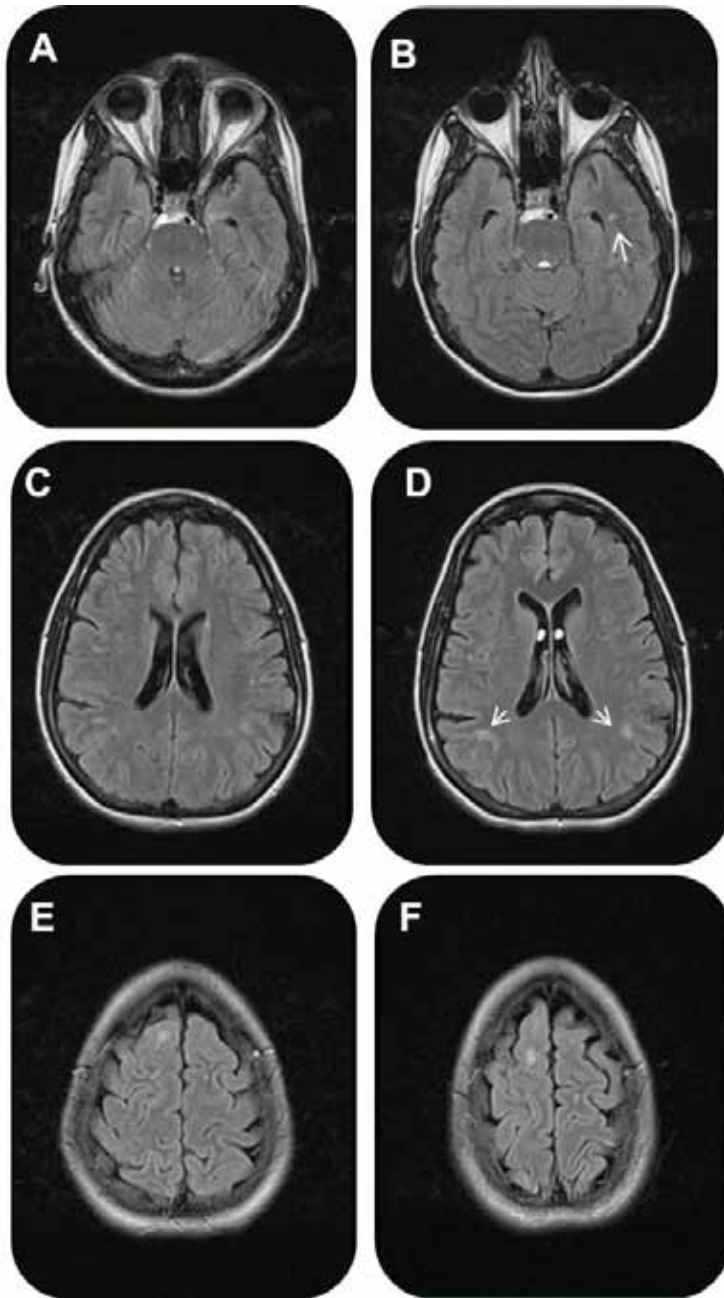


**PVB19:** Parvovirus B19; **MRI:** Magnetic Resonance Imaging; **FLAIR:** Fluid Attenuated Inversion Recovered; **LP:** Lumbar Puncture, **CSF:** Cerebro-spinal fluid, **OCB:** Oligoclonal Bands, **ID:** Infectious disease; **PCR:** Polymerase Chain Reaction; **IVIg:** Intravenous Immunoglobulin.

MRI of the brain demonstrated small juxtacortical, subcortical and pontine non-enhancing hyperintensities on T2/FLAIR, which increased in number of a follow up

study (Figure 2). Initial cerebrospinal fluid (CSF) studies were remarkable for elevated leukocyte count of 12 cell/ml<sup>3</sup>, with lymphocyte predominance, but no oligoclonal bands (OCBs). Repeat CSF studies showed normalization of cell count, 2 OCBs and borderline IgG index of 0.67 (normal 0.66). A six-week course of Ceftriaxone was given by infectious disease specialist for suspected Lyme's disease, followed by a course of intravenous Methylprednisolone for presumptive neuro-inflammatory process. Neither intervention yielded an observable benefit.

**Figure 2 Brain MRI**



Magnetic Resonance Images: A,C and E initial MRI which showed Subcortical and juxtacortical white matter lesions on FLAIR images. B,D and F two months follow up MRI showing few more white matter lesions (arrows)

In view of parvovirus exposure, serum antibodies against PVB19 were tested and found to be elevated: IgG of 4.6 (normal 0-0.8) and IgM of 1.0 (normal 0-0.8). PVB19 Polymerase Chain Reaction (PCR) in serum demonstrated 9800 copies/ml nine months after onset, which decreased to 2000 copies/ml at one-year follow up. Diagnosis of parvovirus-induced encephalopathy [2] was suggested and a course of Intravenous Immunoglobulin (IVIG) 0.4 g/Kg for 5 days was administered and monthly thereafter for 6 months. The treatment resulted in subjective improvement in malaise and arthralgias, but not cognition. PVB19 viremia resolved at 2-year follow-up, but she continued to report cognitive, vestibular and sensory symptoms.

## **DISCUSSION**

PVB19 is a ubiquitous airborne virus that can infect people of all ages, but mostly children. PVB19 infection is typically asymptomatic, but can cause erythema infectiosum ('slapped cheek disease'), arthropathy, and, much less commonly, transient aplastic crisis, persistent anemia and hydrops fetalis. Severity of the disease depends, in part, on the immunologic status of the host with grave cases of aplastic crisis, pure red cell anemia and death in immunodeficient patients lacking neutralizing antibodies [1]. Neurological complications after PVB19 infection have been described; a recent systematic review of neurological manifestations of PVB19 reports encephalitis, encephalopathy and meningoencephalitis represent 63.3% of all PVB19 CNS related cases; several of them 68% were in immunocompetent patients. [2,3]. Permanent neurologic damage with cognitive deficits is also described and presumed to be immune-mediated [4]. We present a case of a young immunocompetent adult with encephalopathy and persistent PVB19 viremia for at least 12 months following parvoviral infection.

Differential diagnosis of encephalopathy and white matter lesions on MRI includes mainly infectious causes such as Lyme's disease, viral (Cytomegalovirus, Varicella, Herpes, West Nile virus) [5], immune-mediated diseases (multiple sclerosis, sarcoidosis, vasculitis), toxic-metabolic (CO exposure, B12 deficiency), vascular etiologies. Our patient underwent extensive work up to rule out these etiologies. Neurodegenerative disorders were considered unlikely given acute onset of symptoms, patient's age and lack of progression. The diagnosis of PVB19-associated encephalopathy is supported by clinical history, elevation of IgM, IgG antibodies [3] in the acute phase and remarkable persistence of PVB19 in serum for a year after exposure.

Systemic parvoviral infection can last from 3-198 days [1,3] with mean duration of 55 days. There is no specific treatment for PVB19 and the majority of cases resolve spontaneously; severe cases of aplastic crisis or pure red cell anemia can respond to IVIG [1,2,4]. However, as our case demonstrates cognitive deficits, which may be related to increasing burden of subcortical hyperintensities on brain MRI, can persistent for years after exposure despite treatment with IVIG. We recommend that patients with neurologic symptoms following PVB19 infection should have serologic and spinal fluid examinations for PVB19 IgG, IgM and PCR as well as MRI of the brain. IVIG could be considered for neurologically-impaired patients with persistent PVB19 viremia. A systematic study of neurologic sequella of PV19 infection and their treatment is warranted.

### **Acknowledgment**

No funding was received for the publication of this work.



## Conflicts of Interest

The authors report no conflicts of interest related to this work.

## REFERENCES

1. Neal S. Young, M.D., and Kevin E. Brown, M.D. Mechanism of Disease Parvovirus B19. *N Engl J Med* 2004; 350:586-597.
2. Bara F, Whiteside S, Batista S, Morris J. Neurological Aspects of Human Parvovirus B19 Infection: a Systemic Review. *Rev. Med. Virol.* Jan 2014.
3. Miltiadis Douvoyiannis, Nathan Litman and David L. Goldman. Neurologic Manifestations Associated with Parvovirus B19 Infection. *Clinical Infectious Diseases* 2009; 48:1713-1723.
4. J R Kerr, F Barah, M L Chiswick et al. Evidence for the role of demyelination, HLA-DR alleles, and cytokines in the pathogenesis of parvovirus B19 meningoencephalitis and its sequelae. *J Neurol Neurosurg Psychiatry* 2002;73:739-746.
5. Arciniegas D, Anderson A, Viral Encephalitis: Neuropsychiatric and Neurobehavioral Aspects. *Current Psychiatric reports.* Vol. 6, Issue 5, 2004.
6. Heegaard ED, Brown KE. Human Parvovirus B19. *Clinical Microbiology Reviews*, July 2002, p. 485-505.
7. Hiroshi Fujimoto, Kyoko Asaoka, Toshihiro Imaizumi, Mitsuyoshi Ayabe, Hiroshi Shoji and Masahide Kaji. Epstein-Barr Virus Infections of the Central Nervous System. *Internal Medicine* 42: 33-40, 2003.