



The Open Orthopaedics Journal

Content list available at: www.benthamopen.com/TOORTHJ/

DOI: 10.2174/1874325001610010001



The Size of the Radial Tuberosity is Not Related to the Occurrence of Distal Biceps Tendon Ruptures: A Case-Control Study

Izaäk F. Kodde^{*,1,2}, Michel P.J. van den Bekerom³, Paul G.H. Mulder⁴ and Denise Eygendaal¹¹ Department of Orthopedics, Upper Limb Unit, Amphia Hospital, Breda, The Netherlands² Department of Orthopedics, Academic Medical Center, Amsterdam, The Netherlands³ Department of Orthopedics, O.L.V.G. Hospital, Amsterdam, The Netherlands⁴ Consulting Biostatistician, Amphia Academy, Amphia Hospital, Breda, The Netherlands

Abstract:

Introduction:

Hypertrophic changes at the radial tuberosity have traditionally been related to distal biceps tendon degeneration and rupture. From supination to pronation of the forearm, the space available for the distal biceps tendon between the lateral ulna and radial bicipital tuberosity (RBT) decreases by almost 50%. A hypertrophic change at the radial tuberosity further reduces this space with impingement of the distal biceps tendon as a result. The purpose of this study was to evaluate whether the size of the RBT plays a role in the pathophysiology of distal biceps tendon ruptures.

Materials and Methods:

Twenty-two consecutive patients with a surgically proven distal biceps tendon rupture were matched to controls, in a 1:1 ratio. The size of the RBT was expressed as a ratio of the maximum diameter of the radius at the RBT to the diameter of the diaphysis just distal to the RBT (RD ratio), measured on standard radiographs of the elbow. The RD ratio of patients and matched controls were compared.

Results:

The mean RD ratio in control group was 1.25 and not significantly different from the mean 1.30 in the group of patients with a distal biceps tendon rupture. Each 0.1 point increase in RD ratio results in an estimated 60% increase of the rupture odds, which was not significant either.

Conclusion:

Based on the RD ratio on conventional radiographs of the elbow, there was no significant difference in RBT size between patients with a distal biceps tendon rupture and matched controls without biceps tendon pathology.

Keywords: Anatomy, distal biceps tendon, elbow, pathophysiology, radial bicipital tuberosity, rupture.

INTRODUCTION

Distal biceps tendon ruptures are most commonly seen in the dominant elbow of men who are in the fourth decade of life [1]. Abuse of tobacco and steroids and the use of statins are associated with an increased risk on rupturing the biceps tendon [2, 3]. Ruptures of the distal biceps tendon have also been described in athletes [4, 5].

In 1956, Davis and Yassine proposed that hypertrophic changes of the radial tuberosity decreased the available

* Address correspondence to this author at the Academic Medical Center, Department of Orthopedics, Post-Box 22660, 1100 DD Amsterdam, The Netherlands; Tel: 0031614198331; Fax: 0031205669117; E-mail: if.kodde@hotmail.com

space between the lateral ulna and Radial Bicipital Tuberosity (RBT), causing irritation of the tendon, predisposing it to degenerative changes and finally rupture [6]. In 1995, Seiler and co-workers did some basic anatomical studies to evaluate potential mechanisms involved in the rupturing process. They found a hypovascular zone in the distal biceps tendon near its insertion at the RBT. Furthermore, they recognized that the space available for the distal biceps tendon between the lateral ulna and RBT decreased by almost 50% from supination to pronation of the forearm [7].

However, this assumption was not supported with clinical data. With recent developments in distal biceps tendon reconstructions, there is also an increasing interest in surgical anatomy of the distal biceps tendon. In 2007 Mazzocca and colleagues identified different tuberosity ridge types (single, smooth or bifid) [8]. The distal biceps tendon is recently described as two distinct tendons with their own functional roles. Moreover, anatomical studies have revealed the insertional footprint anatomy on the RBT, the orientation of the distal biceps tendons to their insertion site and the anatomy of the lacertus fibrosis [9 - 14]. Although these studies provide potential causative factors that might contribute in the rupturing process, most of these recent studies were primarily performed to facilitate a more anatomical reconstruction during reinsertion procedures.

Despite these recent anatomic and biomechanical studies, the definitive cause of tears has yet to be delineated; and Seilers' theory continue to be cited most frequently in the literature as the cause of rupture. However, no clinical data have ever supported the role of a hypertrophic radial tuberosity in the pathophysiology of distal biceps tendon ruptures.

The purpose of this matched control study was to evaluate whether the size of the RBT, measured on standard radiographs of the elbow, plays a role in the pathophysiology of distal biceps tendon ruptures. Our hypothesis was that patients with a larger RBT endure more impingement of the distal biceps tendon between ulna and RBT during pronation and are therefore more at risk for rupturing the distal biceps tendon.

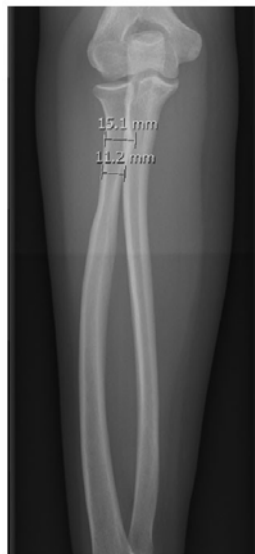

Fig. (1). Example of calculation of RBT-Diaphysis ratio.

MATERIALS AND METHODS

Between November 2007 and November 2010, 22 consecutive patients with 24 distal biceps tendon ruptures underwent surgical repair. Two patients had bilateral ruptures, of which only the first occurring rupture was used. All patients had a surgical refixation using a single incision technique with cortical button fixation. All operations were performed by or under supervision of the senior author. The medical records were reviewed to identify baseline characteristics and known predictors for a distal biceps tendon rupture (age, gender, nicotine abuse). This study was reviewed and approved by the institutional review board.

Standard radiographs were made just after trauma according to local protocol. The patient was seated close to the radiographic table with the entire arm in the same horizontal plane. The arm was fully supinated and the elbow extended for the anteriorposterior (AP) view. If necessary, the patient was asked to lean laterally in order to enable the elbow to be in a true AP position. The long axis of the forearm was aligned to the long axis of the image receptor, and the central ray was directed to the middle of the elbow. The RBT was independently determined at standardized AP

view by two of the authors. The size of the RBT was expressed as a ratio of the maximum diameter of the radius at the RBT to the diameter of the diaphysis just distal to the RBT (RD ratio). A mean RD ratio was calculated from the measurements of the two researchers. See Fig. (1).

Each patient with a distal biceps tendon rupture was matched to a control patient, with a radial head fracture, without distal biceps tendon pathology, in a 1:1 ratio. Radiographs of the control patients were made according to the same local protocols. Subjects were matched by age, gender and nicotine abuse. The control group was retrieved from a database with 450 patients that sustained a radial head fracture for which they received treatment in the same hospital. The final case-control sample consisted of 22 matched pairs.

STATISTICAL ANALYSIS

Differences between cases and controls were analyzed using the paired t-test for continuous variables and McNemar's test for dichotomous variables. A dose-effect relationship between the RD ratio and distal biceps tendon rupture (yes/no) while taking account of the 1:1 matching was analyzed using a conditional logistic regression model stratified by case-control pair.

Statistical analyses were performed using SPSS (version 16.0). A p-value smaller than 0.05 was considered significant.

RESULTS

Baseline characteristics of patients with a distal biceps tendon rupture and controls are summarized in Table 1.

Table 1. Baseline characteristics of patients with a distal biceps tendon rupture and controls.

	Distal Biceps Tendon Rupture (N=22)	Controls (N=22)	Significance (p-Value)
Age (years) [sd]	45.7 [9.38]	45.1 [8.26]	0.23
Gender (% male)	95	95	1.00
Nicotine (% users)	18*	41*	0.34
RDR [sd]	1.30 [0.10]	1.25 [0.07]	0.15

RDR = radial bicipital tuberosity to diaphysis ratio; * N=17.

Distal Biceps Tendon Rupture Group

The mean age at time of rupturing the biceps tendon was 46 years old (range 18-59); distribution is shown in Fig. (2). Of the 22 patients, 5 patients (23%) were smokers. The dominant arm was involved in 56.5% of the cases. The mean RD ratio in this group was 1.30 (range 1.15-1.57).

Control (Radial Head Fracture) Group

The 22 controls had a mean age of 45 years old (range 24-60). Seven patients (32%) were smokers.

The mean RD ratio in control group was 1.25 (range 1.09-1.35) and not significantly different from the mean 1.30 in the group of patients with a distal biceps tendon rupture ($p = 0.15$). The dose-effect relationship as estimated using conditional logistic regression analysis is expressed by means of an odds ratio per 0.1 point increase in RD ratio. The rupture odds is defined as the ratio of the probability of rupture to the probability of no-rupture. Each 0.1 point increase in RD ratio results in an estimated 60% increase of the rupture odds, which is not significant (95% CI: from a 16% decrease to a 204% increase; $p = 0.15$).

DISCUSSION

The pathophysiology of distal biceps tendon ruptures is subject of an ongoing debate for the last decades. Epidemiological studies identified some potential chemical risk factors for distal biceps tendon ruptures, including abuse of nicotine, steroids and statins [1, 3]. Hypertrophic changes at the radial tuberosity have been traditionally been related to distal biceps tendon degeneration and rupture [6]. No clinical or radiographic data have ever supported this theory. Davis and Yassine described enlarged and irregular margins of the radials tuberosity on conventional radiographs of their patients. However, to our knowledge, no standard methods to measure the RBT on radiographs had been described.

To determine the RBT we have introduced the RD ratio. The RD ratio is easily calculated from standard elbow radiographs in a standardized way, the outcome is unrelated to magnification; so calibrated radiographs are not necessary. Previous research on the RBT was from cadavers or CT- scans of the elbow. The RD ratio is a parameter that may be useful in daily clinical practice. It may be included in a risk calculation for distal biceps tendon rupture in for instance body-builders together with other known risk factors (male, smoking, steroids, *etc.*). The radial tuberosity may also be reduced during distal biceps tendon surgery in order to minimize the risk on a re-rupture. Although radiographs provide some information on the size of the RBT, it does not give fully accurate three-dimensional and volume data of the tuberosity. However, the traditional idea that enlarged margins of the RBT caused impingement of the distal biceps tendon was based on a paper from 1956, with no CT-scans available.

Seiler and colleagues reported in 1995 on two possible mechanisms involved in the rupturing process of the distal biceps tendon; a hypovascular zone and impingement of the tendon [7]. Since their original report, numerous other studies has been performed that provided more insight in the anatomy of the distal biceps tendon and it's insertion on the RBT. Eames and colleagues presented a clear anatomical study on the lacertus fibrosis [13]. They showed that the lacertus fibrosis is a fixed-length structure, which comprises the forearm flexor muscles. As these muscles contract, the cross-sectional area increases and it tenses the aponeurosis, thereby pulling the distal biceps tendon medially. This force on the distal biceps tendon might play a role in the rupturing process. Additionally, it could also increase the potential impingement of the tendon between the RBT and the ulna. Although these studies provide important knowledge and theories on the distal biceps tendon anatomy and pathophysiology, no comparison of the patient related anatomy was performed. Recently, Krueger *et al.* evaluated the amount of radioulnar space available for the distal biceps tendon following four different fixation techniques for distal biceps tendon repair on fresh-frozen cadavers [15]. They hypothesized that differences in space could increase the risk of impingement after repair. Next to the rotation of the forearm (pronation-supination), the amount of space available was dependent on the type of reconstruction. Although the authors suggested that reduced radioulnar space or impingement might be a reason for failure of biceps tendon repair, there is no clinical evidence that supports this theory.

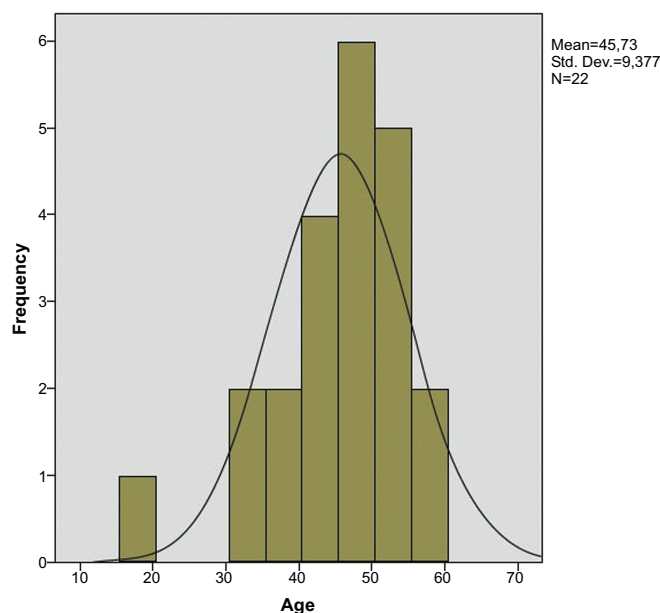


Fig. (2). Age distribution of patients with a distal biceps tendon rupture.

The assumed role of hypertrophic changes at the radial tuberosity causing distal biceps tendon pathology in the past could not be verified in this study. Although it is hypothesized that the size of the RBT affects the distal biceps tendon, it is also possible that the form of the RBT is influenced by the function of the biceps tendon. Previously in 1892, Julius Wolff introduced 'the law of bone transformation', in which he stated that the every change in the function of a bone is followed by changes in architecture of the bone according to mathematical laws [16]. In other words, compression and tension forces produced by the distal biceps might influence the surface of the RBT. Overload of the biceps could lead to microtraumata in the tendon itself, but also lead to the proposed enlargement of the RBT, resulting in impingement of the tendon and even more microtraumata.

The current study was limited by the fact that the groups of cases and controls might have been too small. Using the standard error based on 22 case-control pairs of the estimated log odds ratio from this study it can be calculated that the number of case-control pairs needed to detect a rupture odds ratio of 1.6 per 0.1 unit increase in RD ratio with 80% power would equal 87, given a two-sided test size of 0.05. With 115 case-control pairs a 90% power would be reached. Secondly, conventional radiographs do not provide adequate information to calculate volumes. Also, this is a retrospective study that does not take into account all possible confounders. Ideally, it would be a prospective study in which patients with a distal biceps tendon rupture have a MRI or CT-scan with three-dimensional reconstructions to evaluate the space between RBT and ulna in a pronated position of the forearm.

In conclusion, there was no significant difference in RBT size between patients with a distal biceps tendon rupture and matched controls without a rupture, based on conventional radiographs of the elbow. Although there have been a lot of studies on distal biceps tendon anatomy last decades, the pathophysiology of the rupturing process remains unclear.

CONFLICT OF INTEREST

The authors confirm that this article content has no conflict of interest.

ACKNOWLEDGEMENTS

Declared none.

REFERENCES

- [1] Safran MR, Graham SM. Distal biceps tendon ruptures: incidence, demographics, and the effect of smoking. *Clin Orthop Relat Res* 2002; (404): 275-83. [http://dx.doi.org/10.1097/00003086-200211000-00042] [PMID: 12439270]
- [2] Schneider A, Bennett JM, O'Connor DP, Mehlhoff T, Bennett JB. Bilateral ruptures of the distal biceps brachii tendon. *J Shoulder Elbow Surg* 2009; 18(5): 804-7. [http://dx.doi.org/10.1016/j.jse.2009.01.029] [PMID: 19362860]
- [3] Savvidou C, Moreno R. Spontaneous distal biceps tendon ruptures: are they related to statin administration? *Hand Surg* 2012; 17(2): 167-71. [http://dx.doi.org/10.1142/S0218810412500153] [PMID: 22745079]
- [4] D'Alessandro DF, Shields CL Jr, Tibone JE, Chandler RW. Repair of distal biceps tendon ruptures in athletes. *Am J Sports Med* 1993; 21(1): 114-9. [http://dx.doi.org/10.1177/036354659302100119] [PMID: 8427351]
- [5] Stucken C, Ciccotti MG. Distal biceps and triceps injuries in athletes. *Sports Med Arthrosc Rev* 2014; 22(3): 153-63. [http://dx.doi.org/10.1097/JSA.000000000000030] [PMID: 25077745]
- [6] Davis WM, Yassine Z. An etiological factor in tear of the distal tendon of the biceps brachii; report of two cases. *J Bone Joint Surg Am* 1956; 38-A(6): 1365-8. [PMID: 13376661]
- [7] Seiler JG III, Parker LM, Chamberland PD, Sherbourne GM, Carpenter WA. The distal biceps tendon. Two potential mechanisms involved in its rupture: arterial supply and mechanical impingement. *J Shoulder Elbow Surg* 1995; 4(3): 149-56. [http://dx.doi.org/10.1016/S1058-2746(05)80044-8] [PMID: 7552670]
- [8] Mazzocca AD, Cohen M, Berkson E, *et al.* The anatomy of the bicipital tuberosity and distal biceps tendon. *J Shoulder Elbow Surg* 2007; 16(1): 122-7. [http://dx.doi.org/10.1016/j.jse.2006.04.012] [PMID: 17055747]
- [9] Athwal GS, Steinmann SP, Rispoli DM. The distal biceps tendon: footprint and relevant clinical anatomy. *J Hand Surg Am* 2007; 32(8): 1225-9. [http://dx.doi.org/10.1016/j.jhsa.2007.05.027] [PMID: 17923307]
- [10] Forthman CL, Zimmerman RM, Sullivan MJ, Gabel GT. Cross-sectional anatomy of the bicipital tuberosity and biceps brachii tendon insertion: relevance to anatomic tendon repair. *J Shoulder Elbow Surg* 2008; 17(3): 522-6. [http://dx.doi.org/10.1016/j.jse.2007.11.002] [PMID: 18325797]
- [11] Hutchinson HL, Gloystein D, Gillespie M. Distal biceps tendon insertion: an anatomic study. *J Shoulder Elbow Surg* 2008; 17(2): 342-6. [http://dx.doi.org/10.1016/j.jse.2007.05.005] [PMID: 17931901]
- [12] Jarrett CD, Weir DM, Stuffmann ES, Jain S, Miller MC, Schmidt CC. Anatomic and biomechanical analysis of the short and long head components of the distal biceps tendon. *J Shoulder Elbow Surg* 2012; 21(7): 942-8. [http://dx.doi.org/10.1016/j.jse.2011.04.030] [PMID: 21813298]
- [13] Eames MH, Bain GI, Fogg QA, van Riet RP. Distal biceps tendon anatomy: a cadaveric study. *J Bone Joint Surg Am* 2007; 89(5): 1044-9. [http://dx.doi.org/10.2106/JBJS.D.02992] [PMID: 17473142]

- [14] Kulshreshtha R, Singh R, Sinha J, Hall S. Anatomy of the distal biceps brachii tendon and its clinical relevance. *Clin Orthop Relat Res* 2007; 456(456): 117-20. [http://dx.doi.org/10.1097/BLO.0b013e31802f78aa] [PMID: 17179788]
- [15] Krueger CA, Aden JK, Broughton K, Rispoli DM. Radioulnar space available at the level of the biceps tuberosity for repaired biceps tendon: a comparison of 4 techniques. *J Shoulder Elbow Surg* 2014; 23(11): 1717-23. [http://dx.doi.org/10.1016/j.jse.2014.02.023] [PMID: 24862250]
- [16] Wolff J. Concerning the interrelationship between form and function of the individual parts of the organism. By Julius Wolff, 1900. *Clin Orthop Relat Res* 1988; (228): 2-11. [PMID: 3277757]

Received: July 25, 2015

Revised: September 4, 2015

Accepted: November 19, 2015

© Kodde *et al.*; Licensee *Bentham Open*.

This is an open access article licensed under the terms of the Creative Commons Attribution-Non-Commercial 4.0 International Public License (CC BY-NC 4.0) (<https://creativecommons.org/licenses/by-nc/4.0/legalcode>), which permits unrestricted, non-commercial use, distribution and reproduction in any medium, provided the work is properly cited.