




The Open Urology & Nephrology Journal

Content list available at: <https://openurologyandnephrologyjournal.com>



CASE REPORT

A Case of Multiple Wasp Stings Causing Multi-organ Dysfunction Syndrome

Nabin Basnet^{1,*}, Binod Pantha², Sanjeev Acharya¹, Barsha Shrestha³ and Rishi Kafle³

¹Department of Nephrology, Sumeru Kidney Hospital, Sumeru, Nepal

²Department of Internal Medicine, National Academy of Medical Sciences, Bir Hospital, Nepal

³Department of Nephrology, National Kidney Centre, Kathmandu, Nepal

Abstract: Wasp stings occur commonly and uncomplicated cases are generally managed at local health centers. Complicated cases are referred to tertiary hospitals for multi-specialty care. We report a case of a 30-year old gentleman from a remote center in Nepal who had multiple wasp stings and developed oligo-anuric acute kidney injury, liver failure, and rhabdomyolysis. He was promptly referred to our hospital after initial resuscitation. At our hospital, he was treated with intensive conventional supportive care and specific organ-supportive care including N-Acetylcysteine infusion and hemodialysis. With the treatment given, the general condition of the patient as well as liver function improved within the first week. However, the recovery of kidney function and urine output lagged behind. The patient showed signs of improvement in kidney function at the end of the third week and completely recovered by the 40th day of treatment.

Keywords: Wasps, Bites and stings, Acute kidney injury, Multiple organ failure, Renal dialysis.

Article History

Received: February 11, 2019

Revised: May 24, 2019

Accepted: May 30, 2019

1. INTRODUCTION

Cases of wasp stings are commonly encountered in Nepal [1 - 4]. Uncomplicated cases are managed successfully in primary care centers and those with systemic complications are referred to tertiary care hospitals [1 - 4]. The outcome is variable depending upon factors including the severity of complications, the involvement of different organs, and timely and effective management [1, 3, 5]. Wasp sting causing multi-organ dysfunction is uncommon and carries worse prognosis [5 - 7]. Mortality among patients who have Acute Kidney Injury (AKI) after wasp sting is said to be as high as 25% [5]. This case report describes a young male patient who presented with multi-organ involvement and made a complete recovery.

2. CASE REPORT

A 30-year old previously healthy gentleman from Khotang was stung by a swarm of wasps (species not identified) one day prior to the presentation. He had severe pain due to the stings. Later that day, he developed jaundice and was noted to have reduced and dark-colored urine. He was initially managed in the local health centre and then referred to our hospital after stabilization. At the time of arrival, the patient was ill-looking and icteric with a puffy face. His blood pressure was 150/90 mmHg with normal heart rate and rhythm. The laboratory

investigations showed leukocytosis (Total count: 23000 cells/ml), deranged renal (Serum Creatinine: 4 mg/dl) and liver function tests (Total Bilirubin: 22.9 mg/dl, Serum glutamic pyruvic transaminase 7200 U/L, serum glutamic-oxaloacetic transaminase 2700 U/L), Creatine Phosphokinase (15000 IU/L), and albuminuria without hematuria or casts. Echocardiogram and electrocardiogram were normal. Ultrasonography of kidneys showed diffusely increased cortical echotexture of the kidneys.

The patient was managed further in the Intensive Care Unit (ICU) with parenteral broad-spectrum antibiotics and fluids. Urine output remained low despite fluid resuscitation and diuretics. The patient remained icteric in the first week of the treatment. He received nutritional support tailored to meet his requirement for recovery and other general supportive care. He received N-Acetylcysteine (NAC) infusion for 72 hours from the second day to intensify recovery of liver function. Hemodialysis was started *via* a femoral hemodialysis catheter also from the second day of admission as the patient remained anuric and uremic. The hematological parameters, liver function, and general condition of the patient improved in the first week of the treatment (Fig. 1). He was shifted to the renal ward on the sixth day. In the ward, the patient developed a few episodes of fever and remained oligo-anuric till the end of the third week (Fig. 2). Hemodialysis was continued (Fig. 1) along with antibiotics. Hemodialysis catheter was inserted in the right internal jugular on the eighth day. Gastrointestinal symptoms resolved on Day 12 of admission. The urine output and renal

* Address correspondence to this author at the Nephrology, Sumeru Kidney Hospital, Sumeru, Nepal; Tel: 977-9851037521; E-mail: dr.nabinbasnet@gmail.com

function started to stabilize only in the third week (Fig. 2). Albuminuria resolved on Day 36 of admission. During this period, the patient had received fourteen sessions of hemodialysis (Fig. 1). The patient received inpatient treatment

for 40 days out of which he was in ICU for the first 6 days.

At two weeks and two months after discharge on follow-up, the patient was doing well with normal kidney and liver functions.

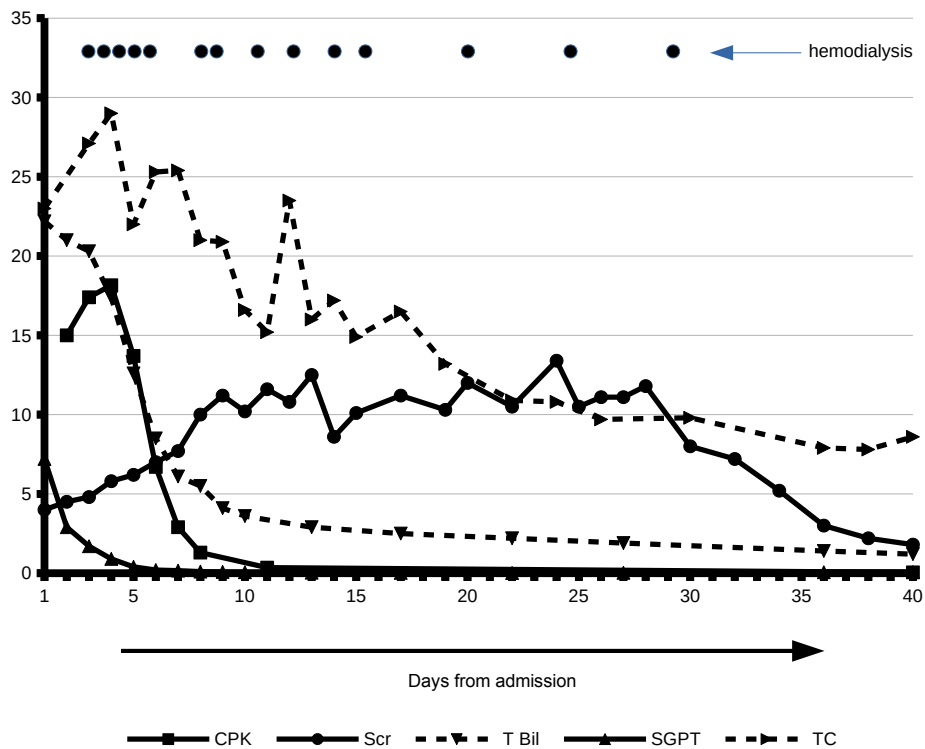


Fig. (1). Levels of blood Creatine Phosphokinase (CPK, mg/L), Serum Creatinine (Scr, mg/dl), total bilirubin (T Bil, mg/dl), Serum glutamic pyruvic transaminase (SGPT, units/ml), and total blood count (TC, cells/nL) shows improvement over time. The dots indicate the day hemodialysis was done. Fourteen sessions of hemodialysis was done during the period of treatment.

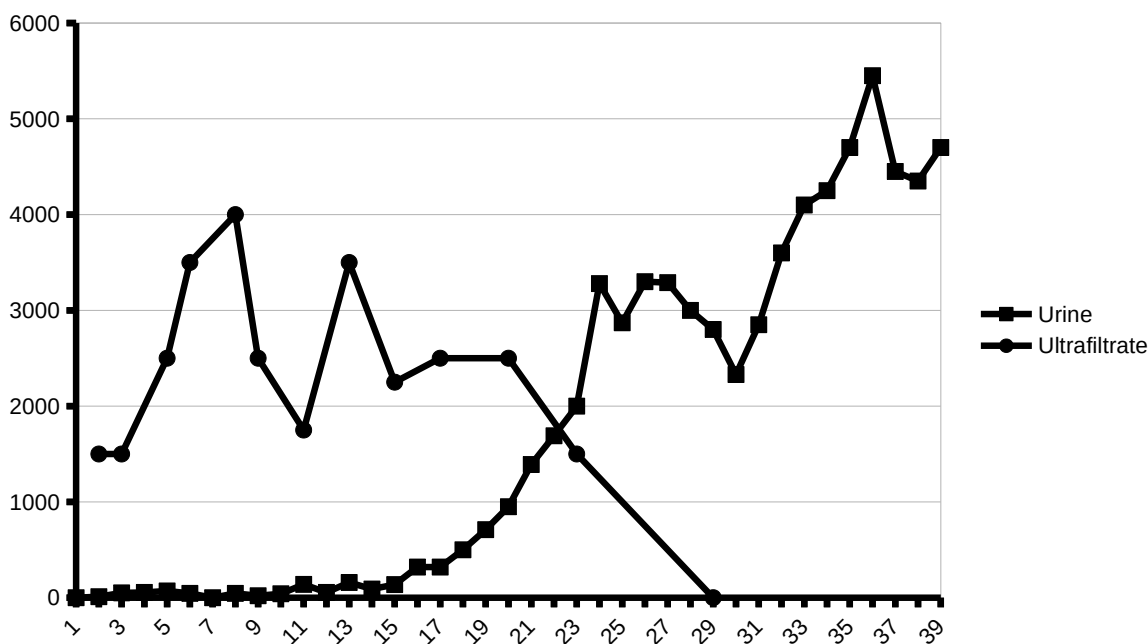


Fig. (2). The patient remained oligo-anuric for three weeks after which the urine output improved gradually. During the period, fluid balance was maintained with ultrafiltration during hemodialysis.

3. DISCUSSION

Wasp stings cause local and systemic effects primarily due to the wasp venom which contains various active substances including dopamine, adrenaline, hyaluronidase, histamine, serotonin, and phospholipase A. Though a single sting of wasp can cause fatal anaphylaxis, severe complications are usually related to massive envenomation [1, 5] which cause toxin-mediated damages including rhabdomyolysis [4, 5, 8 - 10], hematological complications [5, 9], liver failure [5, 6], acute kidney injury [1, 2, 4 - 8, 11 - 14], myocarditis [5, 13], acute pancreatitis [5, 8], and stroke [5, 16]. The clinical features seen in our patient and the consequences are consistent with multi-organ dysfunction due to wasp sting [5].

AKI due to wasp sting is seen in more than half of the patients who experience multiple wasp stings [5]. AKI is due to direct toxic effect of the venom, ischemic acute tubular injury, and nephropathy due to hemoglobinuria and rhabdomyolysis. Renal biopsy reveals acute tubular necrosis and occasionally acute interstitial nephritis and pigment tubulopathy [6, 11, 12]. Liver injury is rare [5] and the pathogenesis has not been well understood. It could be implicated to direct toxic effect and ischemic injury to the liver.

Treatment of wasp sting is supportive. Adequate fluid resuscitation, maintenance of hemodynamic stability, and proper nutritional support enhance recovery.

As most of the cases with severe complications have acute kidney injury, dialysis (intermittent hemodialysis or peritoneal dialysis) is frequently needed for indications such as electrolyte imbalance, uremia, and fluid overload [5]. Plasma exchange with continuous veno-venous hemofiltration has been suggested for the treatment of multiple organ failure after wasp stings [6, 7, 14]. The reported patient received multiple sessions of intermittent hemodialysis which helped in the recovery of the patient.

Intravenous infusion of NAC was given for 72 hours to the patient. NAC infusion is an established treatment for acetaminophen-induced acute liver failure [15, 16], and its use along with conventional treatment has been shown to be beneficial in non-acetaminophen-induced acute liver failure. Our patient received NAC infusion during the initial days of treatment which could have improved the outcome of acute liver failure that the patient had presented with.

The role of steroids in the management of wasp stings other than for initial acute inflammatory reaction is debatable. Our patient did not have features of an acute allergic event but rhabdomyolysis was pronounced. Use of steroid was avoided and did not seem to affect the outcome of the management.

Early referral and management of wasp sting with multi-organ dysfunction improve the outcome.

CONCLUSION

Conventional supportive care along with the intravenous infusion of NAC and intensive hemodialysis support contributed to the successful recovery. The management of such cases with multi-organ involvement should be carried out by a multi-speciality team where dialysis support can be provided till the patient recovers.

ETHICS APPROVAL AND CONSENT TO PARTICIPATE

Not applicable.

HUMAN AND ANIMAL RIGHTS

Not applicable.

CONSENT FOR PUBLICATION

Informed consent was obtained from the patient.

STANDARD FOR REPORTING

CARE guidelines and methodology were followed.

CONFLICT OF INTEREST

The authors declare no conflict of interest, financial or otherwise.

ACKNOWLEDGEMENTS

Declared none.

REFERENCES

- [1] Paudel B, Paudel K. A study of wasp bites in a tertiary hospital of western Nepal. *Nepal Med Coll J* 2009; 11(1): 52-6. [PMID: 19769240]
- [2] Sigdel MR, Raut KB. Wasp bite in a referral hospital in Nepal. *J Nepal Health Res Counc* 2013; 11(25): 244-50. [PMID: 24908524]
- [3] Lama T, Karmacharya B, Chandler C, Patterson V. Telephone management of severe wasp stings in rural Nepal: A case report. *J Telemed Telecare* 2011; 17(2): 105-8. [http://dx.doi.org/10.1258/jtt.2010.100606] [PMID: 21139015]
- [4] Dhakal AK, Basnet NB, Shrestha D. Acute kidney injury due to multiple wasp stings in an eighty-year-old child. *J Kathmandu Med College* 2014; 2(3): 145-7. [http://dx.doi.org/10.3126/jkmc.v2i3.9965]
- [5] Xie C, Xu S, Ding F, *et al.* Clinical features of severe wasp sting patients with dominantly toxic reaction: analysis of 1091 cases. *PLoS One* 2013; 8(12): e83164 [http://dx.doi.org/10.1371/journal.pone.0083164] [PMID: 24391743]
- [6] Liu Z, Li X-D, Guo B-H, *et al.* Acute interstitial nephritis, toxic hepatitis and toxic myocarditis following multiple Asian giant hornet stings in Shaanxi Province, China. *Environ Health Prev Med* 2016; 21(4): 231-6. [http://dx.doi.org/10.1007/s12199-016-0516-4] [PMID: 26910407]
- [7] Han-Min W, Feng L, Mei-Lan Z, Rong L, Hong-Bao L, Chen H, *et al.* Successful treatment of multiple organ failure after wasp stings in an elderly patient. *Int J Gerontol* 2012; 6(1): 52-3. [http://dx.doi.org/10.1016/j.ijge.2012.01.002]
- [8] Yang SH, Song YH, Kim TH, *et al.* Acute pancreatitis and rhabdomyolysis with acute kidney injury following multiple wasp stings. *Case Rep Nephrol* 2017; 20178596981 [Internet]. [http://dx.doi.org/10.1155/2017/8596981] [PMID: 28706746]
- [9] Chao SC, Lee YY. Acute rhabdomyolysis and intravascular hemolysis following extensive wasp stings. *Int J Dermatol* 1999; 38(2): 135-7. [http://dx.doi.org/10.1046/j.1365-4362.1999.00640.x] [PMID: 10192165]
- [10] Ito K, Imafuku S, Nakayama J. Rhabdomyolysis due to Multiple Wasp Stings. *Case Rep Dermatol Med* 2012; 2012486724 [Internet]. [http://dx.doi.org/10.1155/2012/486724] [PMID: 23259084]
- [11] Chao Y-W, Yang A-H, Ng Y-Y, Yang W-C. Acute interstitial nephritis and pigmented tubulopathy in a patient after wasp stings. *Am J Kidney Dis* 2004; 43(2): e15-9. [http://dx.doi.org/10.1053/j.ajkd.2003.10.025] [PMID: 14750120]
- [12] Ezhilnilavan S, Priyamvada PS, Srinivas BH, Satish H, Parameswaran S. Acute tubulointerstitial nephritis following hymenopteran stings. *Postgrad Med J* 2018; 94(1113): 418-20. [http://dx.doi.org/10.1136/postgradmedj-2018-135608] [PMID: 29626057]

- [13] Jairam A, Kumar RSV, Ghosh AK, *et al.* Delayed Kounis syndrome and acute renal failure after wasp sting. *Int J Cardiol* 2010; 138(1): e12-4.
[<http://dx.doi.org/10.1016/j.ijcard.2008.06.004>] [PMID: 18706710]
- [14] Zhang L, Yang Y, Tang Y, *et al.* Recovery from AKI following multiple wasp stings: A case series. *Clin J Am Soc Nephrol* 2013; 8(11): 1850-6.
[<http://dx.doi.org/10.2215/CJN.12081112>] [PMID: 24009218]
- [15] Wani M, Saleem S, Verma S, *et al.* Multiple cerebral infarctions with severe multi-organ dysfunction following multiple wasp stings. *Ann Indian Acad Neurol* 2014; 17(1): 125-7.
[<http://dx.doi.org/10.4103/0972-2327.128581>] [PMID: 24753680]
- [16] Nabi T, Nabi S, Rafiq N, Shah A. Role of N-acetylcysteine treatment in non-acetaminophen-induced acute liver failure: A prospective study. *Saudi J Gastroenterol* 2017; 23(3): 169-75.
[PMID: 28611340]

© 2019 Basnet *et al.*

This is an open access article distributed under the terms of the Creative Commons Attribution 4.0 International Public License (CC-BY 4.0), a copy of which is available at: <https://creativecommons.org/licenses/by/4.0/legalcode>. This license permits unrestricted use, distribution, and reproduction in any medium, provided the original author and source are credited.